

DATE

6/29/2023

PATIENT

Cam Giansante

SPECIES

Canine

BREED

Labrador

SEX

Neutered Male

AGE

4/13/2011

WEIGHT

86.5 lbs

INTERPRETED BY

Beth Johnson, DVM
DACVIM

HOSPITAL NAME

Warm & Fuzzy

REFERRING VET

Dr. Urie

INVOICE

10296

PRESENTING CLINICAL SIGNS

History of hypertension and proteinuria. Irregular spleen on radiographs and loss of abdominal muscle tone. Hypothyroidism- new.

Current Medications: 60mg Benazapril SID.
Lab Results: ALP 388, Total T4 0.7. Urine protein 2+, specific gravity 1.011, BP 170.
Date of Previous IntraPet Ultrasound: No previous.
Sedation: Gabapentin PO.
Stat Report: Not requested.
Imaging Performed By: Stephanie Warga RDCS, RVT.

ULTRASONOGRAPHIC EXAMINATION OF THE ABDOMEN

Urinary System

The urinary bladder is only mildly distended with primarily anechoic contents and occasional echogenic non-shadowing debris. Apical urinary bladder wall is diffusely thick. Mucosa is hyperechoic and irregular. No masses or cystoliths are observed. The trigone and visible pelvic urethra are normal thickness with a smooth mucosal surface. The urinary bladder wall measures 0.74 cm thick. Given the lack of full distention, this finding should be interpreted cautiously.

The right kidney is normal in size (7.37 cm), shape, and echogenicity. It has smooth peripheral margination. There is a normal 1:3 cortex-to-medulla ratio with appropriate corticomedullary distinction. There is no evidence of pyelectasia, mineral, or infarcts observed.

The left kidney is normal in size (7.98 cm), shape, and echogenicity. It has smooth peripheral margination. There is a normal 1:3 cortex-to-medulla ratio with appropriate corticomedullary distinction. A small cortical cyst in the caudal pole was noted. There is no evidence of pyelectasia, mineral, or infarcts observed.

Adrenal Glands

Adrenal glands are plump/swollen in size. Normal shape and contour are maintained without evidence of capsular invasion. Corticomedullary structure is unremarkable. Visible surrounding vasculature appears normal. A hyperechoic nodule is noted in the cranial poles of both adrenal glands. Nodule does not disrupt normal shape and/or architecture. The right adrenal measures 1.61 cm cranial, and 1.04 cm caudal. The left adrenal gland measures 1.41 cm cranial, and 1.04 caudal.

Spleen

Spleen is subjectively normal in size with a normal smooth capsular contour. Parenchyma is appropriately finely textured and homogenous with normal echogenicity relative to surrounding tissue (hyperechoic to liver). Multifocal discrete hyperechoic homogenous nodules are noted. Near the head of the spleen, there is a 1.5 cm x 1.6 cm mildly heterogenous hypo to anechoic/cystic non-capsule disrupting nodule. Splenic vasculature appears normal.

Liver

The liver is subjectively normal in size with normal smooth curvilinear peripheral contour. Parenchyma is appropriately hypoechoic to the spleen in echogenicity and appropriately mildly coarse and homogenous in echotexture. In the mid to left caudal liver there is a 3 cm x 6.7 cm rounded homogenous isoechoic liver lobe/emerging mass-like lesion noted. Visible vasculature and biliary tree appear normal without distension or congestion.

Gallbladder is mildly overdistended with a moderate amount of non-dependent, mildly aggregated/inspissated sludge. Hypo to anechoic cystic areas is noted between the gallbladder sludge and luminal wall. The wall is otherwise smooth without visible thickening. There is no evidence of cystic or CBD dilation. There is no evidence of effusion.

Gastrointestinal

The visible stomach wall is normal in thickness and layering. The lumen of the stomach is mildly distended with very echogenic reverberation artifact from intraluminal gas. There is no evidence of obstruction, foreign material, or infiltrative disease; however, complete visualization of far wall is partially inhibited by gas. Pyloric outflow tract appears patent.

The visible small intestines are normal in wall thickness and layering (canine duodenum < 0.5 cm and feline duodenum < 0.4 cm; other < 0.3 cm). Small intestinal motility appears adequate (1-3 contractions per min). The lumen of the small intestine is empty with no evidence of obstruction or foreign material.

The visible colon is normal in wall thickness (< 0.2 cm) and layering. Contents are consistent with normal formed feces and gas.

Pancreas

The pancreatic parenchyma is appropriately isoechoic to surrounding tissue. Visible capsule is smooth and normal in contour. There is no visible pancreatic duct dilation. There is no evidence of active peripancreatic inflammation.

Free Abdomen

There is no evidence of free peritoneal effusion noted in these images.

There is no apparent lymphadenopathy noted in these images.

There is no evidence of heart base or pericardial pathology noted in these images at this time. If cardiac function evaluation is desired a full echocardiogram is recommended.

ULTRASONOGRAPHIC FINDINGS

- **Bilateral adrenomegaly with bilateral cranial pole hyperechoic adrenal nodule** – Differentials include primary adrenal cortical adenoma or adenocarcinoma, pheochromocytoma, myelolipoma, adrenal hyperplasia secondary to pituitary disease or metastatic disease. Ultrasound alone cannot differentiate between functional and non-functional nodules and/or between benign and malignant disease. Small nodules without other evidence of abdominal disease (to suggest metastatic disease) and/or clinical signs (to suggest adrenal disease) are most often incidental and should be monitored.
- **Emerging mucocele** – Cholecystic debris is of unknown clinical significance. It can be seen with biliary stasis from fasting or illness. Cholecystic debris is not necessarily related to hepatobiliary disease. The non-dependent nature of this sludge combined with the cystic areas are suggestive, however, of possible emerging cystic mucosal hyperplasia or early gallbladder mucocele.
- The liver nodule/mass described above trends in appearance towards benign as is seen with marked nodular hyperplasia versus an adenoma, hepatoma, etc. However, infiltrative neoplasia is possible and cannot be ruled out without tissue sampling.

- **Hyperechoic splenic nodules** – most consistent with benign myelolipomas. Other differentials such as fibrosis or calcification caused by old hematomas or infarcts, chronic inflammation, granulomatous disease, or metastatic disease cannot be ruled out, but are considered less likely. **Hypo to anechoic splenic nodule** – likely represents a benign lesion such as a cyst, hematoma, nodular hyperplasia, extramedullary hematopoiesis, etc., however while considered less likely, infiltrative neoplasia can mimic benign lesions, and cannot be ruled out.
- **Possible Chronic Cystitis** - Urinary bladder wall changes are most consistent with chronic cystitis. Infiltrative neoplasia cannot be ruled out but is considered less likely give the location and diffuse nature of the changes.

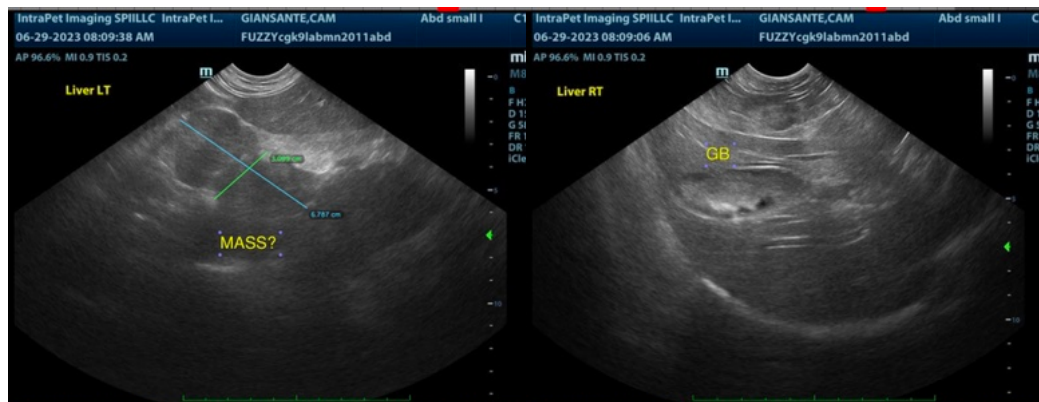
SECONDARY FINDINGS

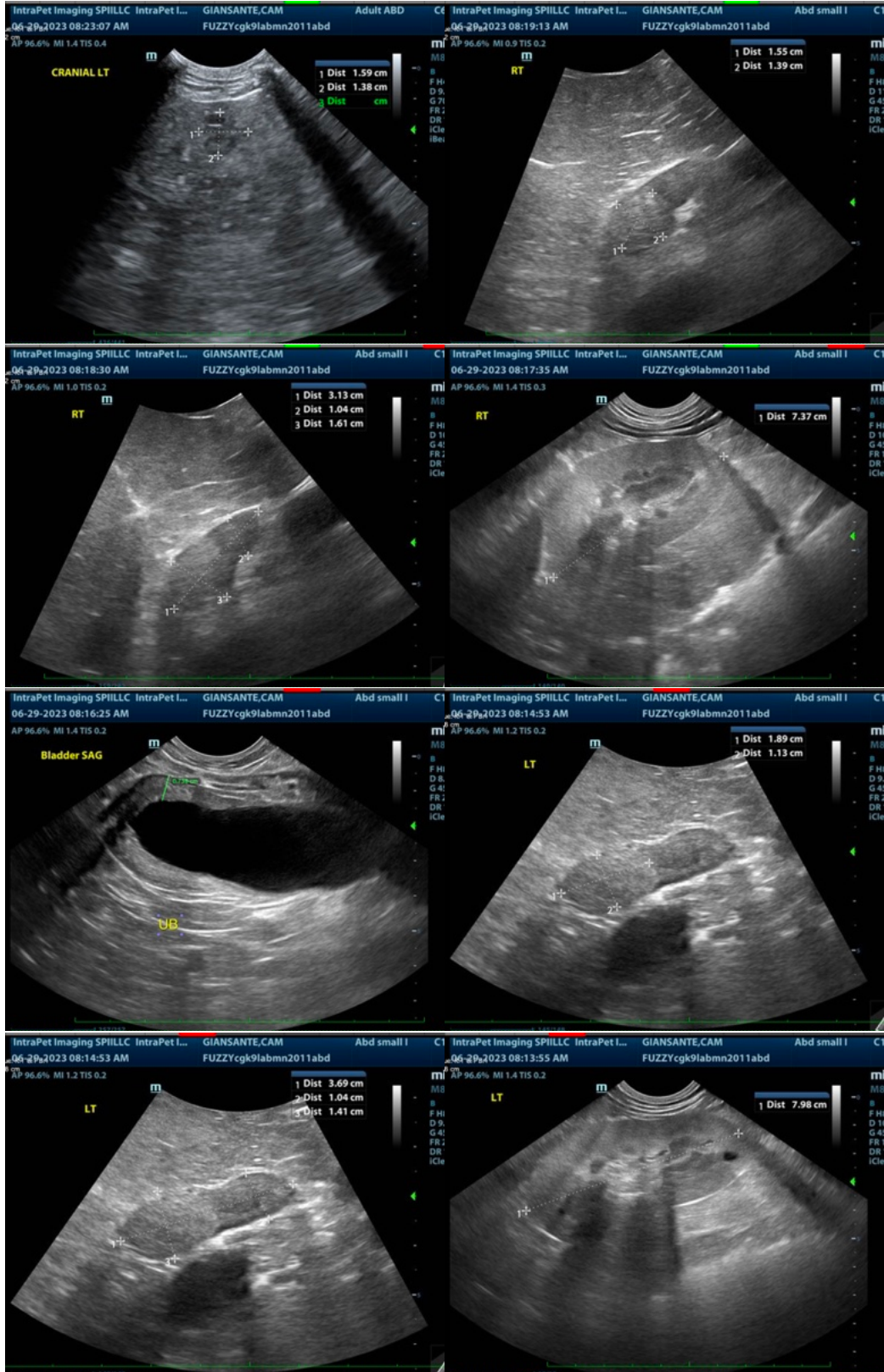
- A small cortical cyst in the caudal pole of the left kidney.

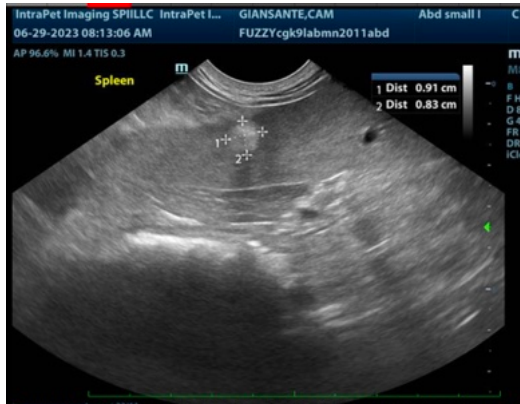INTERPRETATION OF THE FINDINGS & FURTHER RECOMMENDATIONS

Three view thoracic radiographs are recommended for further assessment of cardio-pulmonary status as well as to further evaluate for any evidence of metastatic disease, if not recently evaluated. A fine needle aspirate of mid to left caudal liver is recommended if patient coagulation status is appropriate.

Beyond that, given the pathology described above the adrenal glands, the gallbladder, the liver, etc. could all be related to underlying hyperadrenocorticism which could also possibly be contributing to hypertension and proteinuria. If clinical signs of hyperadrenocorticism are present further testing is warranted in the form of a low-dose Dexamethasone suppression test. However, without supporting clinical signs further evaluation is not necessarily indicated but treatment of hypertension and proteinuria should be pursued/continued.







The information and recommendations provided are based on the images presented by the referring veterinarian/sonographer. No evaluation can be communicated regarding pathology that was not visible in the image/video clips provided.

Thank you for this referral. If the clinical or image interpretation does not parallel your findings or if I can be of any further assistance, please contact me.

Beth Johnson, DVM, DACVIM
info@sonopath.com