

**DATE**

6/28/22

PRESENTING CLINICAL SIGNS

Known IBD/PLE, sees Dr. Petrus. Maintained on Fish, sweet potato OTC. Acutely vomiting last night, weak, cannot hold down water, no known ingestion - but does run on farm. Has not had labwork in a while.
Current Medications: Buprenorphine, Metronidazole.

PATIENT

Lab Results: See attached.

Radiographs: gas dilation, one bowel loop - very mottled/distended, cannot tell if it is colon or SI.

Date of Previous IntraPet Ultrasound: No previous.

Sedation: Not required to complete full diagnostic ultrasound.

Stat Report: Not requested.

Imaging Performed By: Rachel Brillhart, RDMS.

Graham Manzanares

SPECIES

Canine

BREED

Jack Russell

SEX

Neutered male

AGE

6/28/11

WEIGHT

11.2 lbs

ULTRASONOGRAPHIC EXAMINATION OF THE ABDOMEN**Urinary System**

Urinary bladder is adequately distended with anechoic contents. No masses, inflammatory changes, echogenic sediment or cystoliths are observed. The urinary bladder, trigone and visible pelvic urethra are normal in thickness with a smooth mucosal surface.

The prostate is normal for a neutered dog.

Left kidney is normal in size (4.46 cm), shape and echogenicity. It has smooth peripheral margination. There is a normal 1:3 cortex to medulla ratio with appropriate corticomedullary distinction. There is no evidence of pyelectasia, mineral or infarcts observed.

Right kidney is normal in size (4.24 cm), shape and echogenicity. It has smooth peripheral margination. There is a normal 1:3 cortex to medulla ratio with appropriate corticomedullary distinction. There is no evidence of pyelectasia, mineral or infarcts observed.

INTERPRETED BY

Beth Johnson, DVM
DACVIM

Adrenal Glands

Left adrenal gland is normal in size (1.94 cm long, 0.69 cm at cranial pole and 0.63 cm at caudal pole), shape and overall architecture, echogenicity and echotexture. Visible surrounding vasculature appears normal.

Right adrenal gland is normal in size (1.89 cm long, 0.76 cm at cranial pole and 0.78 cm at caudal pole), shape and overall architecture, echogenicity and echotexture. Visible surrounding vasculature appears normal.

HOSPITAL NAME

Animal Emergency
Hospital

Spleen

Spleen is subjectively normal in size with a normal smooth capsular contour. Parenchyma is appropriately finely textured and homogenous with normal echogenicity relative to surrounding tissue (hyperechoic to liver). No focal nodules or masses are observed. Splenic vasculature appears normal.

REFERRING VET

Dr. King

INVOICE

31306

Liver

Liver is subjectively normal in size with normal smooth curvilinear peripheral contour. Parenchyma is appropriately hypoechoic to the spleen in echogenicity and appropriately mildly coarse and homogenous in echotexture. No focal lesions are observed. Visible vasculature and biliary tree appear normal without distension or congestion.

Gallbladder is non-distended in size. The wall is smooth without visible thickening. Luminal contents are primarily anechoic. There is no evidence of cystic or common bile duct dilation.

Gastrointestinal

The visible stomach wall is normal in thickness and layering. The lumen of the stomach is empty with no evidence of obstruction, foreign material or infiltrative disease. Pyloric outflow tract appears patent.

The visible small intestines are normal in wall thickness and layering. Small intestinal motility appears adequate (1-3 contractions per min). The lumen of the small intestine is empty with no evidence of obstruction, foreign material or infiltrative disease.

The large bowel is markedly over distended and contains primarily fluid as well as echogenic sand, debris and larger pieces of possibly bone, mineral or rocks that are causing strong hyperechoic, curvilinear interfaces in the colon with strong acoustic shadowing.

Pancreas

The observed pancreas appears appropriately isoechoic to surrounding omental fat. Visible capsule is smooth and normal in contour. Visible pancreatic parenchyma is homogenous and unremarkable. There is no visible pancreatic duct dilation. There is no evidence of active peripancreatic inflammation.

Free Abdomen

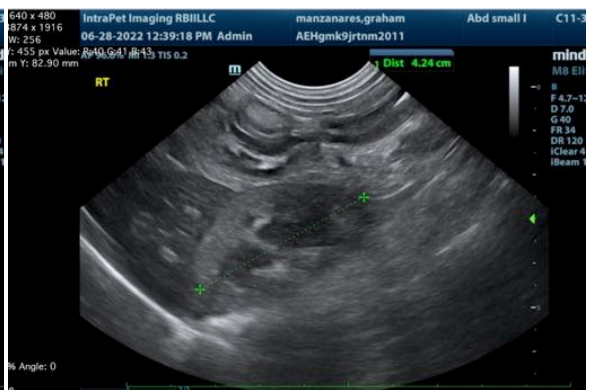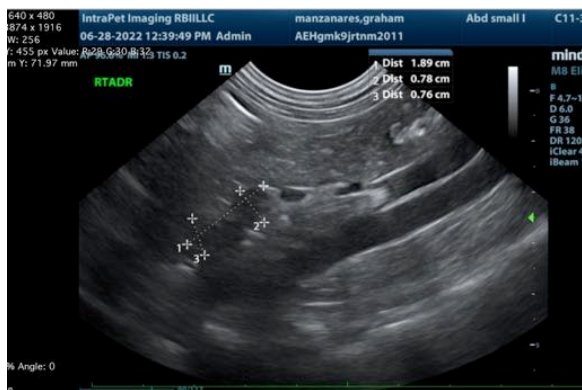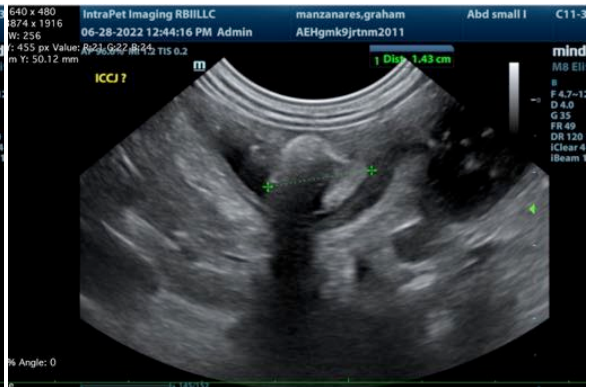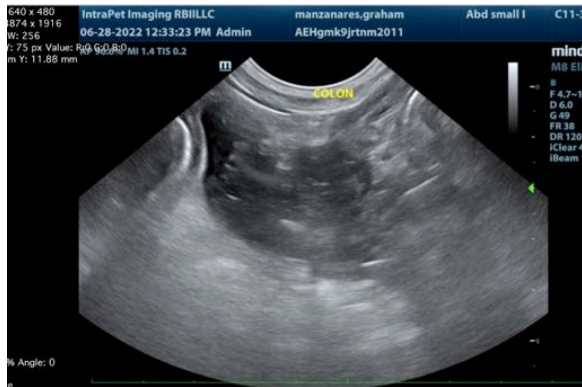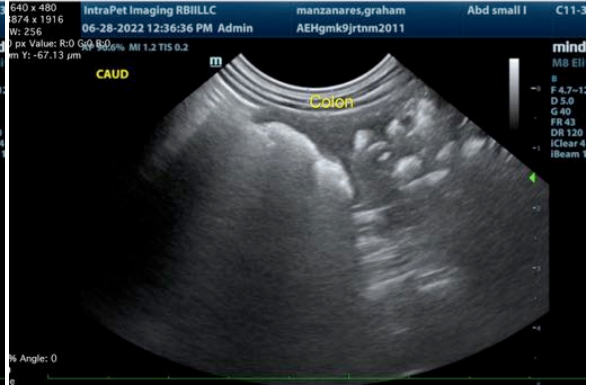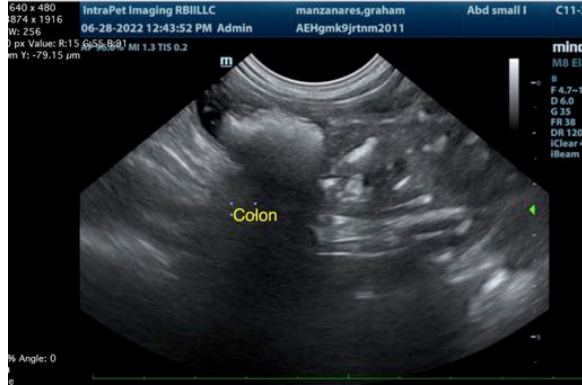There is a scant amount of anechoic free fluid. No appreciable lymphadenopathy is noted in these images.

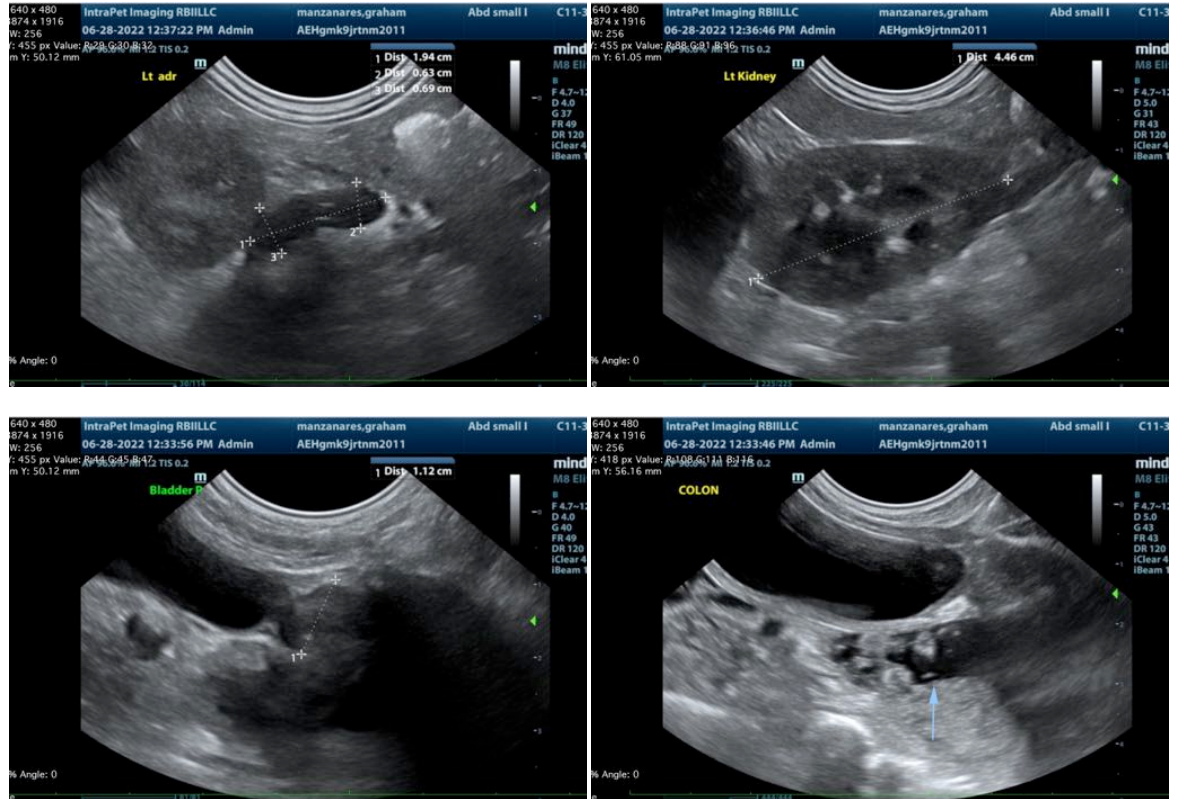
ULTRASONOGRAPHIC FINDINGS

- Markedly over distended colon filled with debris, consistent with sand, rocks or may be bone fragments and fluid stool. This is consistent with diarrhea. Some involvement of the small bowel cannot be definitively ruled out, but is considered much less likely with no over distension of stomach or small bowel to suggest obstruction and/or mechanical reason for the vomiting.
- Scant amount of anechoic free fluid likely secondary to this patient's reportedly low albumin.

INTERPRETATION OF THE FINDINGS & FURTHER RECOMMENDATIONS

Differentials for this patient's acute gastrointestinal signs is potentially an acute flare up of the reported historical IBD/PLE, possibly brought on by dietary indiscretion resulting from something outside. Recommendations include supportive medical management of acute gastroenteritis/colitis with fluid support as needed, anti-emetics, gastroprotectants, appetite stimulants if necessary, probiotic +/- Metronidazole or Tylosin and/or fiber as needed to control clinical signs. Monitoring this patient's defecation/bowel movements, etc. for any signs of straining is recommended. If vomiting and upper gastrointestinal signs persist beyond medical management recheck imaging to definitively rule out small bowel involvement is recommended. Additionally a gastrointestinal malabsorption panel (including cobalamin, folate, TLI and PLI) to Texas A&M GI Laboratory is recommended for further evaluation of GI and pancreatic function.





The information and recommendations provided are based on the images presented by the referring veterinarian. No evaluation can be communicated regarding pathology that was not visible in the image/video clips provided.

Thank you for this referral. If the clinical or image interpretation does not parallel your findings or if I can be of any further assistance please contact me.

Beth Johnson, DVM DACVIM

Beth.Johnson@SonoPath.com