

**DATE PRESENTING CLINICAL SIGNS**

6/28/22 P has hx of chronic intermittent V+/D+. Currently on RC Gastrointestinal. Symptoms resolve when on abx but return soon after meds are finished. P also has hx of elevated liver values

PATIENT

Frankie Giancola Current Medications: Cerenia 60 mg SID, Metronidazole 500mg BID
Lab Results: Last BW 6/20/2022 Alk Phos 715; ALT 157. Baseline Cortisol 2.3 (normal).

Date of Previous IntraPet Ultrasound: No previous.

Sedation: Patient sedated with Torbugesic.

Stat Report: Not requested.

SPECIES

Canine

ULTRASONOGRAPHIC EXAMINATION OF THE ABDOMEN**BREED**

Pit Bull

Urinary System

Urinary bladder is mildly to moderately distended with anechoic contents. Apical urinary bladder wall is diffusely thick (0.54 cm thick). Mucosa is hyperechoic and irregular. No masses or cystoliths are observed. The trigone and visible pelvic urethra are normal thickness with a smooth mucosal surface.

SEX

Neutered Male

Prostate (neutered) is normal in size, echotexture and echogenicity for a neutered male.

AGE

12/10/11

The right kidney is normal in size (6.97 cm), shape and echogenicity. It has smooth peripheral margination. There is a normal 1:3 cortex to medulla ratio with appropriate corticomedullary distinction. There is no evidence of pyelectasia, mineral or infarcts observed.

WEIGHT

68 Pounds

The left kidney is normal in size (6.58 cm), shape and echogenicity. It has smooth peripheral margination. There is a normal 1:3 cortex to medulla ratio with appropriate corticomedullary distinction. There is no evidence of pyelectasia, mineral or infarcts observed.

INTERPRETED BY

Beth Johnson, DVM
DACVIM

Adrenal Glands

The right adrenal gland is normal in size (2.74 cm long x 0.78 cm at the cranial pole and 0.59 cm at the caudal pole), shape and contour. Corticomedullary structure is unremarkable. Visible surrounding vasculature appears normal.

IMAGING PERFORMED BY

Andi Parkinson RDMS

The left adrenal gland is normal in size (3.2 cm long x 1.0 cm at the cranial pole and 1.1 cm at the caudal pole), shape and contour. Corticomedullary structure is unremarkable. Visible surrounding vasculature appears normal.

HOSPITAL NAME

Banfield Timonium

Spleen

The spleen is subjectively normal in size with a normal smooth capsular contour. Parenchyma is appropriately finely textured and homogenous with normal echogenicity relative to surrounding tissue (hyperechoic to liver). No focal nodules or masses are observed. Splenic vasculature appears normal.

REFERRING VET

Dr. Adu

Liver

The liver is subjectively enlarged with irregular margins. Parenchyma is heterogenous characterized by multiple poorly defined hypoechoic nodules within otherwise hyperechoic liver parenchyma. Visible vasculature and biliary tree appear normal without distension or congestion.

INVOICE

39080

The gallbladder is moderately distended with anechoic bile as well as suspended and gravity dependent echogenic debris. The wall is smooth without visible thickening. There is no evidence of cystic or CBD dilation. There is no evidence of effusion or inflammation.

Gastrointestinal

The stomach wall is normal in thickness (canine < 0.5 cm and feline < 0.4 cm) and layering. The lumen of the stomach is empty with no evidence of obstruction, foreign material or infiltrative disease. Pyloric outflow tract appears patent.

The visible small intestine demonstrates areas of thick muscularis layer relative to mucosa (disruption of the normal 1:3 muscularis:mucosa ratio). Small intestinal submucosa is slightly irregular, thick and hyperechoic, without evident loss of layering appreciated. The lumen is empty with no evidence of obstruction or foreign material. Hyperechoic enhanced fat is noted around the area of the jejunum with the thick muscularis.

The visible colon is normal in wall thickness (< 0.2 cm) and layering. Contents are consistent with normal formed feces and gas.

Pancreas

The pancreatic parenchyma is appropriately isoechoic to surrounding tissue. Visible capsule is smooth and normal in contour. There is no visible pancreatic duct dilation. There is no evidence of active peripancreatic inflammation.

Free Abdomen

There is no evidence of peritoneal effusion. There is no apparent lymphadenopathy.

PRIMARY FINDINGS

- Inflammatory bowel disease (IBD) pattern - This finding has been reported with infiltrative bowel disease including both benign inflammatory disease as well as infiltrative neoplasia such as lymphoma. No concurrent lymphadenopathy, loss of layering, etc. is noted to make lymphoma more probable, but lymphoma cannot be definitively ruled out without tissue sampling. Enhanced hyperechoic fat surrounding the inflamed bowel indicates active inflammatory process/focal peritonitis.

SECONDARY FINDINGS

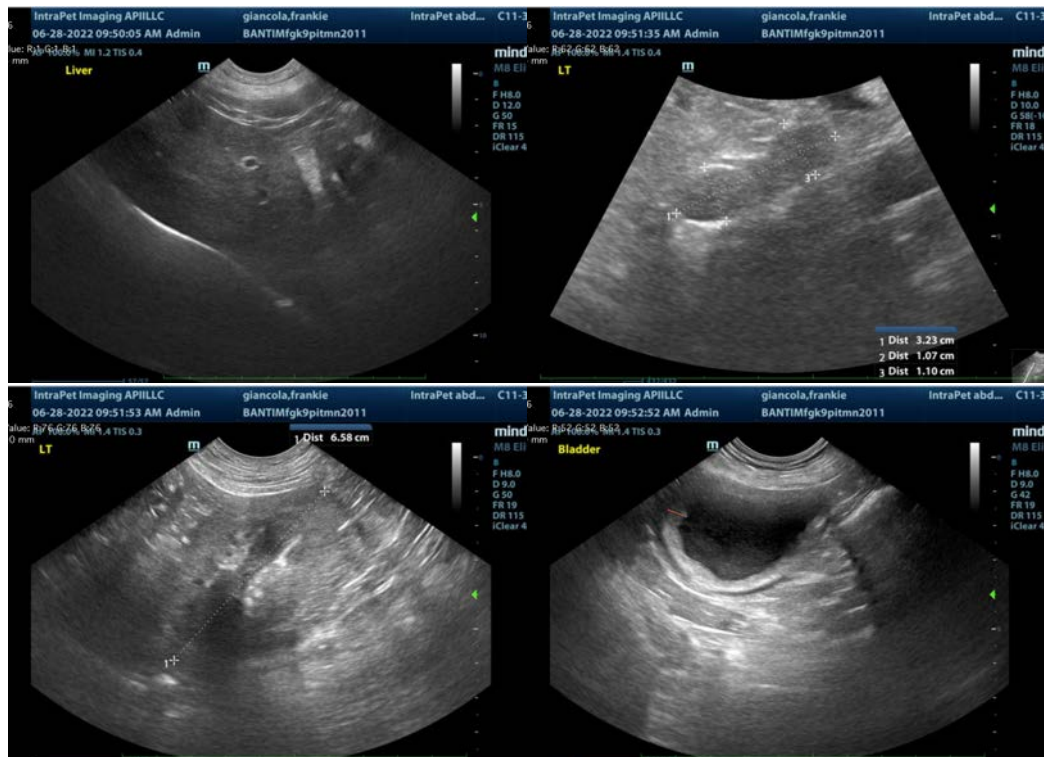
- Chronic Cystitis – Urinary bladder wall changes are most consistent with chronic cystitis. Infiltrative neoplasia cannot be ruled out but is considered less likely give the location and diffuse nature of the changes.
- Liver Nodular Hyperplasia – These changes are most consistent with benign processes such as nodular hyperplasia, steroid (vacuolar) hepatopathy, extramedullary hematopoiesis or possibly chronic inflammatory disease and less commonly infiltrative round cell or metastatic neoplasia.
- Gallbladder debris - Cholecystic debris is of unknown clinical significance. It can be seen with biliary stasis from fasting or illness. Cholecystic debris is not necessarily related to hepatobiliary disease. Echogenic bile is most commonly an incidental finding in dogs and should be interpreted in combination with clinical signs such as nausea, inappetence, cranial abdominal discomfort and/or laboratory changes such as increased ALP and/or increased Tbili.

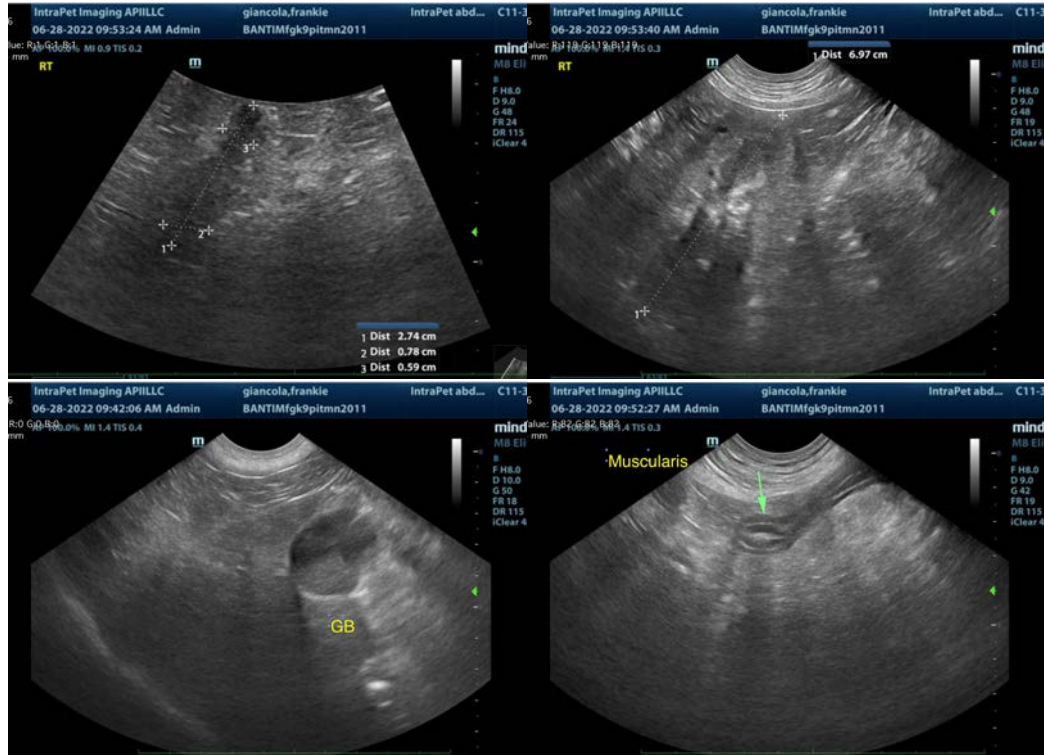
INTERPRETATION OF THE FINDINGS & FURTHER RECOMMENDATIONS

- Given this patient's history of gastrointestinal signs, response to antibiotics, and ultrasound findings, an infiltrative inflammatory process, potentially infectious in nature, is suspected. Recommendations include a gastrointestinal malabsorption panel (including cobalamin, folate, TLI and PLI) to Texas A&M GI Laboratory for further evaluation of GI and pancreatic function, as well as

A fecal enteropathogen PCR panel to Texas A&M GI Laboratory could be considered for further evaluation of possible infectious disease.

- Pending results, ultimately ideally biopsies of the GI tract are recommended to definitively diagnose and therefore manage the infiltrative bowel disease, if a diagnosis is not obtained via the enteropathogen PCR panel. In the meantime, transition from Metronidazole to Tylosin could be considered with plans to treat long-term, potentially antibiotic responsive diarrhea, as Tylosin is a safer long-term options. Other empirical therapeutic considerations could include a fecal transplant.
- Urinalysis and, if indicated based on urinalysis results, urine culture are recommended. If protein is present in an otherwise quiet sediment, protein quantification with a urine protein to creatinine ration is recommended.
- Given the combination of ultrasound changes, a differential for the increased ALP includes hyperadrenocorticism. However, testing in the form of a low-dose Dexamethasone suppression test is not recommended until further evaluation/resolution of the gastrointestinal signs is accomplished.





The information and recommendations provided are based on the images presented by the referring veterinarian/sonographer. No evaluation can be communicated regarding pathology that was not visible in the image/video clips provided.

Thank you for this referral. If the clinical or image interpretation does not parallel your findings or if I can be of any further assistance please contact me.

Beth Johnson, DVM, DACVIM
Beth.Johnson@sonopath.com