

**DATE PRESENTING CLINICAL SIGNS**

6/28/22 PU/PD, panting, weight loss.

PATIENT

Beckham Jacobs

Current Medications: Vetprofen 100mg ½ up to BID, Fluoxetine 40mg SID, Apoquel 16mg ½ SID- not constantly on, Gabapentin 100mg 2 BID- just added.

Lab Results: See attached.

Radiographs: Liver- enlarged/rounded.

Date of Previous IntraPet Ultrasound: No previous.

SPECIES

Canine

Sedation: Telazol, Torbugesic and Dexdomitor.

Stat Report: Not requested.

BREED

Border Collie X

ULTRASONOGRAPHIC EXAMINATION OF THE ABDOMEN**Urinary System**

The urinary bladder is moderately distended with anechoic contents. No masses, inflammatory changes, echogenic sediment or cystoliths are observed. The urinary bladder, trigone and visible pelvic urethra are normal in thickness with a smooth mucosal surface.

SEX

Neutered Male

Prostate (neutered) is normal in size, echotexture and echogenicity for a neutered male.

AGE

8/6/07

The right kidney is normal in size (6.52 cm), shape and echogenicity. It has smooth peripheral margination. There is a normal 1:3 cortex to medulla ratio with appropriate corticomedullary distinction. There is no evidence of pyelectasia, mineral or infarcts observed.

WEIGHT

54.8 Pounds

The left kidney is normal in size (6.45 cm), shape and echogenicity. It has smooth peripheral margination. There is a normal 1:3 cortex to medulla ratio with appropriate corticomedullary distinction. There is no evidence of pyelectasia, mineral or infarcts observed.

INTERPRETED BYBeth Johnson, DVM
DACVIM**Adrenal Glands**

The adrenal glands are bilaterally plump/swollen, but largely normal in shape and contour. The left adrenal gland measures 2.31 cm long x 0.56 cm at the cranial pole and 1.1 cm at the caudal pole. The right adrenal gland measures 2.5 cm long x 1.1 cm at the cranial pole and 0.70 cm at the caudal pole. Some parenchymal heterogeneity is present without concerning capsular distortion. These changes are likely normal for this age but should be monitored if there is any suspicion of adrenal disease.

IMAGING PERFORMED BYStephanie Pearce
RDMS, RVT**Spleen**

The spleen is subjectively large in size with a normal smooth capsular contour. Parenchyma is appropriately finely textured and homogenous with normal echogenicity relative to surrounding tissue (hyperechoic to liver). Multifocal well demarcated hyperechoic homogeneous nodules are noted. Splenic vasculature appears normal. The spleen is folded upon itself, which is a positional non-pathologic variant.

HOSPITAL NAMEHoneygo Animal
Hospital**Liver**

The liver is subjectively enlarged with irregular margins. Parenchyma is heterogenous characterized by multiple poorly defined hypoechoic nodules within otherwise hyperechoic liver parenchyma. A more discrete focal, more heterogeneous, slightly hypoechoic area is noted in the mid cranial liver, measuring 2.5 cm x 4.5 cm in diameter with an emerging mass-like appearance. In the right liver, a 1.2 cm x 2.0 cm cystic lesion is also presented. Visible vasculature and biliary tree appear normal without distension or congestion.

REFERRING VET

Dr. Mullenex

INVOICE

39078

The gallbladder is non-distended in size. The wall is smooth without visible thickening. Luminal contents are primarily anechoic. There is no evidence of cystic or common bile duct dilation.

Gastrointestinal

The stomach wall is normal in thickness (canine < 0.5 cm and feline < 0.4 cm) and layering. The lumen of the stomach is empty with no evidence of obstruction, foreign material or infiltrative disease. Pyloric outflow tract appears patent.

The visible small intestines are normal in wall thickness and layering (canine duodenum < 0.5 cm and feline duodenum < 0.4 cm; other < 0.3 cm). Small intestinal motility appears adequate (1-3 contractions per min). The lumen of the small intestine is empty with no evidence of obstruction, foreign material or infiltrative disease.

The visible colon is normal in wall thickness (< 0.2 cm) and layering. Contents are consistent with normal formed feces and gas.

Pancreas

The pancreatic parenchyma is appropriately isoechoic to surrounding tissue. Visible capsule is smooth and normal in contour. There is no visible pancreatic duct dilation. There is no evidence of active peripancreatic inflammation.

Free Abdomen

There is no evidence of peritoneal effusion. There is no apparent lymphadenopathy.

No pericardial effusion noted in these images.

PRIMARY FINDINGS

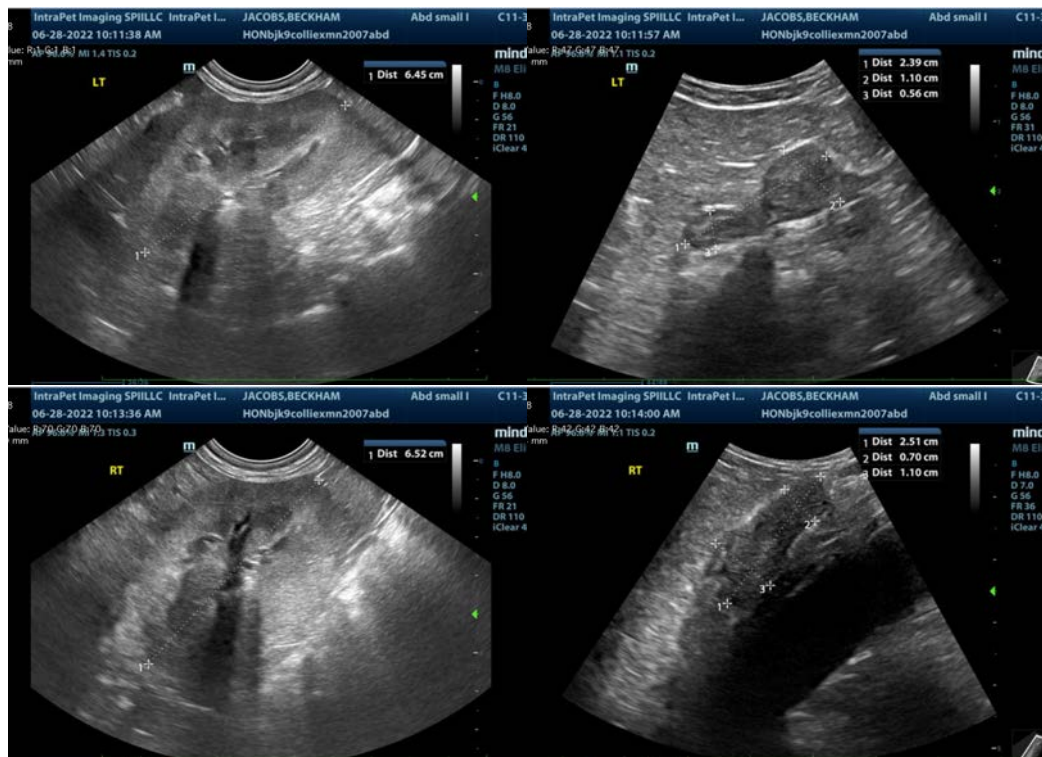
- Bilateral adrenomegaly – consistent with adrenal hyperplasia secondary to pituitary depending hyperadrenocorticism vs normal variant. Diffuse heterogeneity noted, consistent with normal age related remodeling. However, more severe infiltrative disease cannot be ruled out, and the adrenal glands should be monitored.
- Liver Nodular Hyperplasia – These changes are most consistent with benign processes such as nodular hyperplasia, steroid (vacuolar) hepatopathy, extramedullary hematopoiesis or possibly chronic inflammatory disease and less commonly infiltrative round cell or metastatic neoplasia.
- More discrete emerging mass mid liver – differentials include a benign mass such as a hepatoma as well as infiltrative well differentiated primary hepatocellular carcinoma.
- Liver cyst

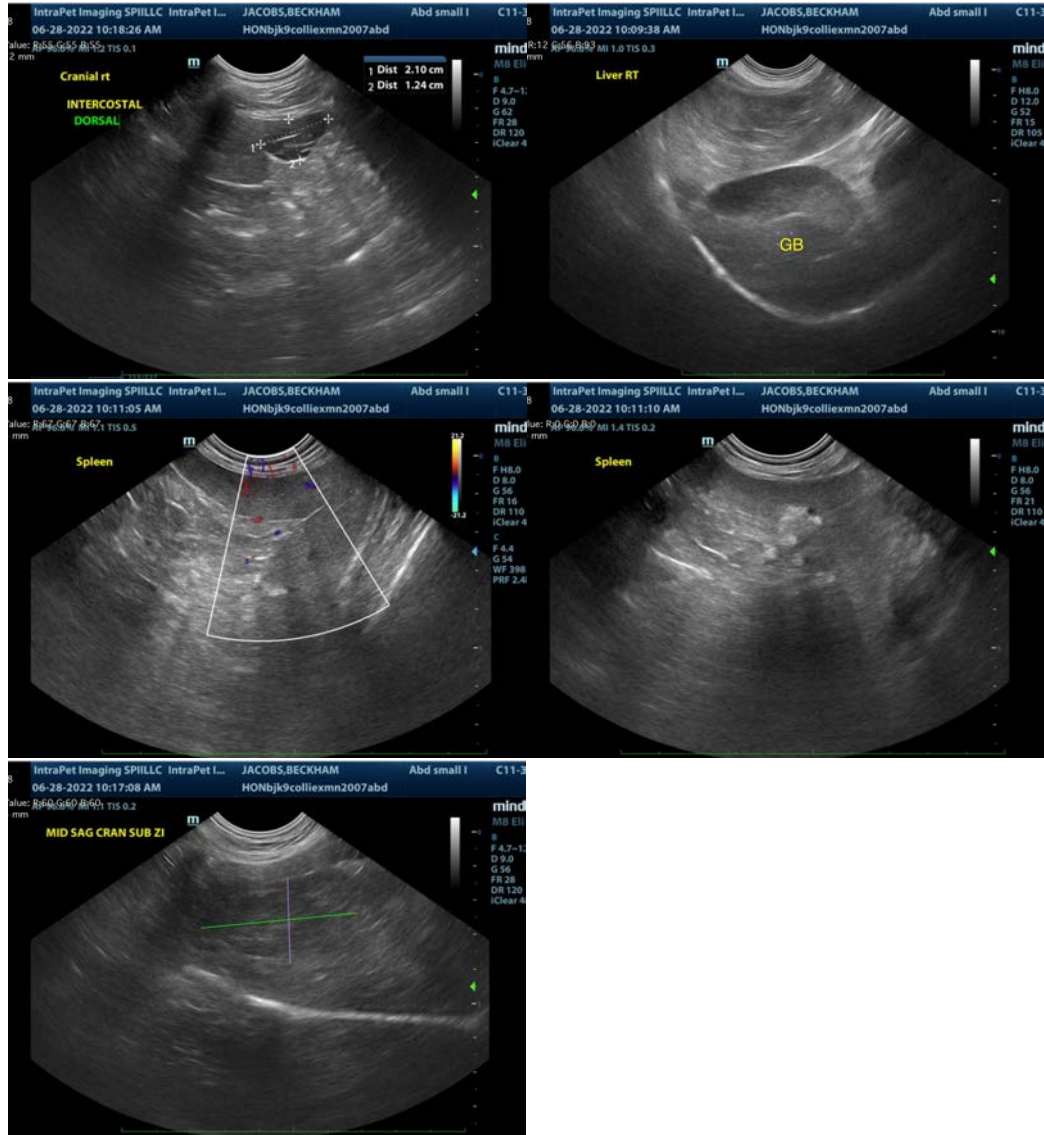
SECONDARY FINDINGS

- Gallbladder debris - Cholecystic debris is of unknown clinical significance. It can be seen with biliary stasis from fasting or illness. Cholecystic debris is not necessarily related to hepatobiliary disease. Echogenic bile is most commonly an incidental finding in dogs and should be interpreted in combination with clinical signs such as nausea, inappetence, cranial abdominal discomfort and/or laboratory changes such as increased ALP and/or increased Tbili.
- Hyperechoic splenic nodules – most consistent with benign myelolipomas. Other differentials such as fibrosis or calcification caused by old hematomas or infarcts, chronic inflammation, granulomatous disease or metastatic disease cannot be ruled out, but are less likely.

INTERPRETATION OF THE FINDINGS & FURTHER RECOMMENDATIONS

- The described adrenal gland, liver and gallbladder changes are all suggestive of hyperadrenocorticism. If clinical signs of hyperadrenocorticism, such as polyuria, polydipsia, polyphagia, panting, hair loss, hypertension, etc. are present, testing for hyperadrenocorticism with a LDDS test is warranted. If clinical signs are not present, monitoring is recommended with testing pursued when/if clinical signs develop.
- If not recently evaluated, blood pressure is recommended.
- If not recently evaluated, a urinalysis and, if indicated based on urinalysis results, urine culture are also recommended. If protein is present in an otherwise quiet sediment, protein quantification with a urine protein to creatinine ratio is recommended.
- While hyperadrenocorticism is suspected based on reported clinical signs, ultrasound findings, etc., hyperadrenocorticism does not typically result in a decreased appetite or weight loss, and does not typically cause an ALT relatively higher than the ALP. Therefore, other recommendations prior to pursuing hyperadrenocorticism include fine needle aspirate of the emerging mid liver mass, Leptospirosis testing, and potentially a course of broad-spectrum antibiotics and hepatic nutraceuticals with monitoring of liver enzymes for improvement.
- Three view thoracic radiographs are recommended for further assessment of cardio-pulmonary status as well as to further evaluate for any evidence of metastatic disease, if not recently evaluated.





The information and recommendations provided are based on the images presented by the referring veterinarian/sonographer. No evaluation can be communicated regarding pathology that was not visible in the image/video clips provided.

Thank you for this referral. If the clinical or image interpretation does not parallel your findings or if I can be of any further assistance please contact me.

Beth Johnson, DVM, DACVIM
Beth.Johnson@sonopath.com