

**DATE PRESENTING CLINICAL SIGNS**

6/27/23

Patient presents for evaluation of routine PE and labwork- some mildly increased kidney values noted on labwork.

**PATIENT**

Maya Szklany

Current Medications: Proin ER 38mg SID long term.

Lab Results: See attached.

Date of Previous IntraPet Ultrasound: No previous.

Sedation: Not required to complete full diagnostic ultrasound.

Stat Report: Not requested.

Imaging Performed By: Stephanie Warga RDCS, RVT.

**SPECIES**

Canine

**BREED**

Hound X

**SEX**

Spayed Female

**AGE**

12/18/19

**WEIGHT**

32 Pounds

**INTERPRETED BY**

Beth Johnson, DVM  
DACVIM

**HOSPITAL NAME**

Perry Hall AH

**REFERRING VET**

Dr. Miller

**INVOICE**

43481

**ULTRASONOGRAPHIC EXAMINATION OF THE ABDOMEN****Urinary System**

The urinary bladder is moderately distended with anechoic contents. No masses, inflammatory changes, echogenic sediment or cystoliths are observed. The urinary bladder, trigone and visible pelvic urethra are normal in thickness with a smooth mucosal surface.

The right kidney is normal in size (4.71 cm long) and shape with smooth peripheral margination. A normal 1:3 cortex to medulla ratio is maintained. The medulla and cortices are uniform in texture with some mild increased cortical echogenicity and mild loss of corticomedullary distinction. There is no evidence of pyelectasia, mineral or infarcts observed.

The left kidney is small (2.83 cm), irregular and diffusely echogenic with decreased corticomedullary distinction and very little to no normal architecture. No overt neoplasia or mineral is observed.

**Adrenal Glands**

The right adrenal gland is normal in size (0.42 cm at the cranial pole and 0.56 cm at the caudal pole), shape and contour. Corticomedullary structure is unremarkable. Visible surrounding vasculature appears normal.

The left adrenal gland is normal in size (0.47 cm at the cranial pole and 0.53 cm at the caudal pole), shape and contour. Corticomedullary structure is unremarkable. Visible surrounding vasculature appears normal.

**Spleen**

The spleen is subjectively normal in size with a normal smooth capsular contour. Parenchyma is appropriately finely textured and homogenous with normal echogenicity relative to surrounding tissue (hyperechoic to liver). No focal nodules or masses are observed. Splenic vasculature appears normal.

**Liver**

The liver is subjectively normal in size with normal smooth curvilinear peripheral contour. Parenchyma is appropriately hypoechoic to the spleen in echogenicity and appropriately mildly coarse and homogenous in echotexture. No focal lesions are observed. Visible vasculature and biliary tree appear normal without distension or congestion.

Gallbladder is moderately distended with anechoic bile as well as suspended and gravity dependent echogenic debris. The wall is smooth without visible thickening. There is no evidence of cystic or CBD dilation. There is no evidence of effusion or inflammation.

### ***Gastrointestinal***

The stomach wall is normal in thickness (canine < 0.5 cm and feline < 0.4 cm) and layering. The lumen of the stomach is empty with no evidence of obstruction, foreign material or infiltrative disease. Pyloric outflow tract appears patent.

The visible small intestines are normal in wall thickness and layering (canine duodenum < 0.5 cm and feline duodenum < 0.4 cm; other < 0.3 cm). Small intestinal motility appears adequate (1-3 contractions per min). The lumen of the small intestine is empty with no evidence of obstruction, foreign material or infiltrative disease.

The visible colon is normal in wall thickness (< 0.2 cm) and layering. Contents are consistent with normal formed feces and gas.

### ***Pancreas***

The pancreatic parenchyma is appropriately isoechoic to surrounding tissue. Visible capsule is smooth and normal in contour. There is no visible pancreatic duct dilation. There is no evidence of active peripancreatic inflammation.

### ***Free Abdomen***

There is no evidence of free peritoneal effusion noted in these images.

There is no apparent lymphadenopathy noted in these images.

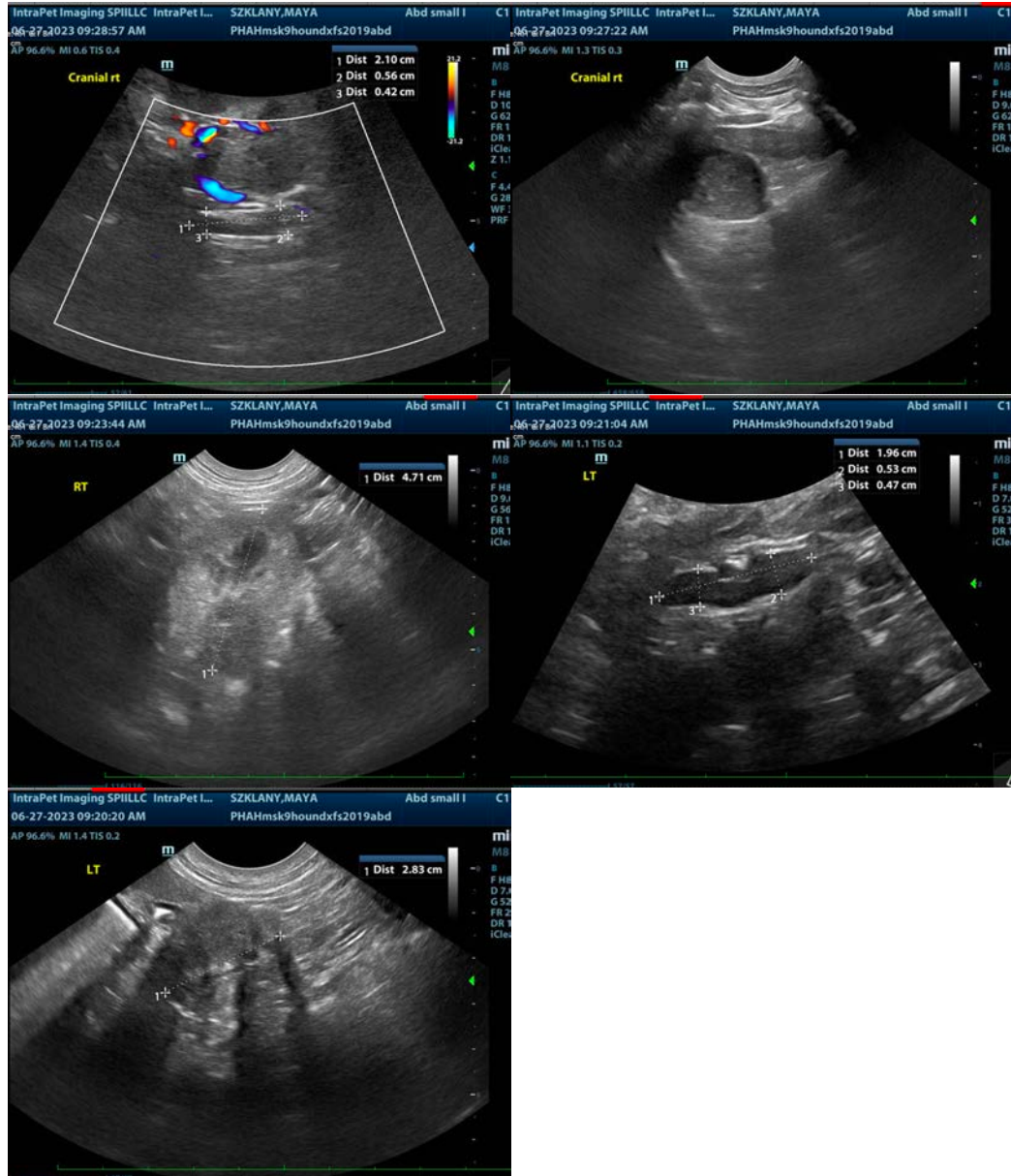
## **ULTRASONOGRAPHIC FINDINGS**

- **Left kidney renal dysplasia with some mild loss of corticomedullary distinction, evidence of possible kidney disease in the right kidney but to a much milder degree** – The appearance of this left kidney in a young dog is most concerning for congenital renal dysplasia or juvenile nephropathy. Other differentials include glomerular or interstitial nephritis, leptospirosis, chronic pyelonephritis, ethylene glycol toxicosis, etc.
- **Mild gallbladder debris** - Cholecystic debris is of unknown clinical significance. It can be seen with biliary stasis from fasting or illness. Cholecystic debris is not necessarily related to hepatobiliary disease. Echogenic bile is most commonly an incidental finding in dogs and should be interpreted in combination with clinical signs such as nausea, inappetence, cranial abdominal discomfort and/or laboratory changes such as increased ALP and/or increased Tbili.

## **INTERPRETATION OF THE FINDINGS & FURTHER RECOMMENDATIONS**

The appearance of this patient's left kidney is concerning for a congenital renal dysplasia. Having said, further evaluation of concurrent contributing renal insults such as urinary tract infection, Leptospirosis, etc. should be investigated/ruled out. Additionally, if not recently evaluated, a blood pressure is recommended.

In the meantime, beginning management of chronic kidney disease, starting with a kidney friendly diet if well tolerated, is recommended, as well as medical management of any concurrent hypertension, proteinuria, etc.



The information and recommendations provided are based on the images presented by the referring veterinarian/sonographer. No evaluation can be communicated regarding pathology that was not visible in the image/video clips provided.

Thank you for this referral. If the clinical or image interpretation does not parallel your findings or if I can be of any further assistance please contact me.

**Beth Johnson, DVM, DACVIM**  
 info@sonopath.com