

**DATE PRESENTING CLINICAL SIGNS**

6/27/23 Ongoing intermittent vomiting and weight loss past 8 months, 10lbs weight loss with no diet changes since 8/22. PE: unremarkable, BCS 4/9.

PATIENT

Bo Fitzpatrick
 Current Medications: None listed.
 Lab Results: 6/9/23 CBC WNL. Chem 17- ALT (H) 300, lepto negative.
 Date of Previous IntraPet Ultrasound: No previous.
 Sedation: Not required to complete full diagnostic ultrasound.
 Stat Report: Not requested.
 Imaging Performed By: Stephanie Warga RDCS, RVT.

SPECIES

Canine

BREED

Labrador Retriever

SEX

Intact Male

AGE

6/10/19

WEIGHT

69 Pounds

INTERPRETED BY

Beth Johnson, DVM
 DACVIM

HOSPITAL NAME

Perry Hall AH

REFERRING VET

Dr. Baer

INVOICE

43477

ULTRASONOGRAPHIC EXAMINATION OF THE ABDOMEN**Urinary System**

The urinary bladder is moderately distended with anechoic contents. No masses, inflammatory changes, echogenic sediment or cystoliths are observed. The urinary bladder, trigone and visible pelvic urethra are normal in thickness with a smooth mucosal surface.

Prostate is normal in size for an intact male (3.46 cm wide). Parenchyma is diffusely homogenous and relatively hyperechoic. Normal distinct margins and symmetrical bilobed shape are maintained.

The right kidney is normal in size (6.46 cm), shape and echogenicity. It has smooth peripheral margination. There is a normal 1:3 cortex to medulla ratio with appropriate corticomedullary distinction. There is no evidence of pyelectasia, mineral or infarcts observed.

The left kidney is normal in size (7.34 cm), shape and echogenicity. It has smooth peripheral margination. There is a normal 1:3 cortex to medulla ratio with appropriate corticomedullary distinction. There is no evidence of pyelectasia, mineral or infarcts observed.

Adrenal Glands

The right adrenal gland is normal in size (2.75 cm long x 0.94 cm at the cranial pole and 0.83 cm at the caudal pole), shape and contour. Corticomedullary structure is unremarkable. Visible surrounding vasculature appears normal.

The left adrenal gland is normal in size (3.49 cm long x 0.59 cm at the cranial pole and 0.60 cm at the caudal pole), shape and contour. Corticomedullary structure is unremarkable. Visible surrounding vasculature appears normal.

Spleen

The spleen is subjectively normal in size with a normal smooth capsular contour. Parenchyma is appropriately finely textured and homogenous with normal echogenicity relative to surrounding tissue (hyperechoic to liver). No focal nodules or masses are observed. Splenic vasculature appears normal.

Liver

The liver is subjectively normal in size with normal smooth curvilinear peripheral contour. Parenchyma is appropriately hypoechoic to the spleen in echogenicity and appropriately mildly coarse and homogenous in echotexture. No focal lesions are observed. Visible vasculature and biliary tree appear normal without distension or congestion.

The gallbladder is non-distended in size. The wall is smooth without visible thickening. Luminal contents are primarily anechoic. There is no evidence of cystic or common bile duct dilation.

Gastrointestinal

The visible stomach wall is normal in thickness and layering. The lumen of the stomach is mildly distended with echogenic non-shadowing luminal contents and gas consistent with normal ingesta. There is no evidence of obstruction, foreign material or infiltrative disease. Pyloric outflow tract appears patent.

The visible small intestines are normal in wall thickness and layering (canine duodenum < 0.5 cm and feline duodenum < 0.4 cm; other < 0.3 cm). Small intestinal motility appears adequate (1-3 contractions per min). The lumen of the small intestine is empty with no evidence of obstruction, foreign material or infiltrative disease.

The visible colon is normal in wall thickness (< 0.2 cm) and layering. Contents are consistent with normal formed feces and gas.

Pancreas

The pancreatic parenchyma is appropriately isoechoic to surrounding tissue. Visible capsule is smooth and normal in contour. There is no visible pancreatic duct dilation. There is no evidence of active peripancreatic inflammation.

Free Abdomen

There is no evidence of free peritoneal effusion noted in these images.

There is no apparent lymphadenopathy noted in these images.

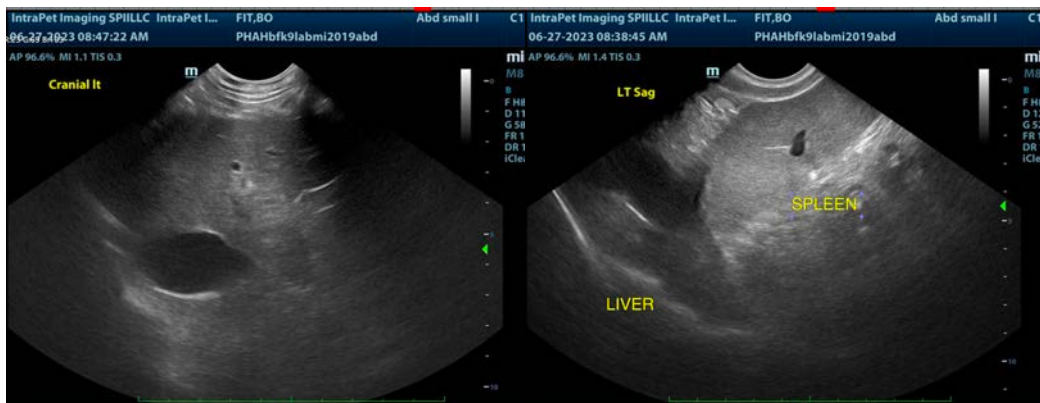
Both testicles are visualized without evident testicular pathology.

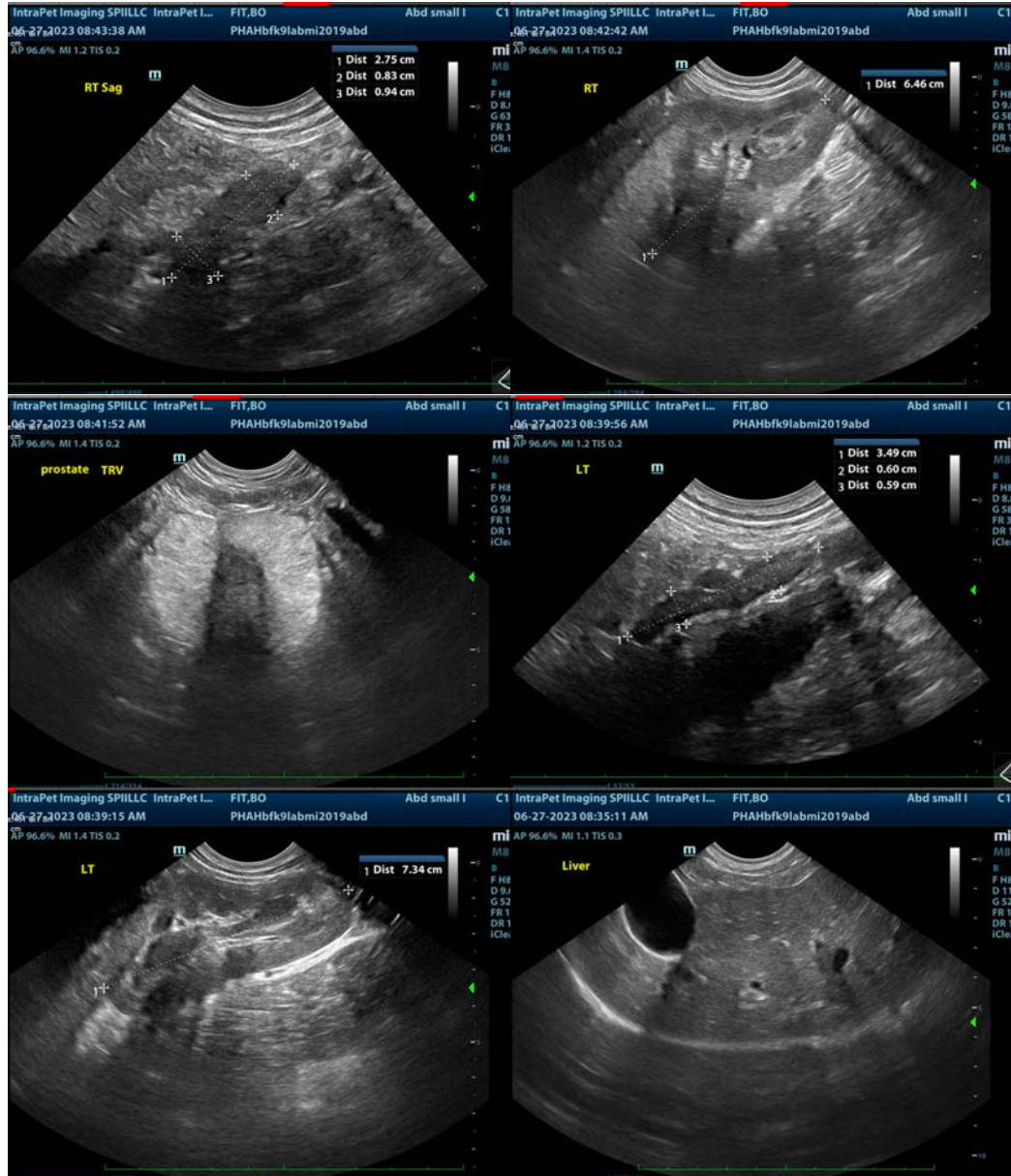
ULTRASONOGRAPHIC FINDINGS

- An obvious cause for the reported increased liver enzymes is not identified in these images. Microscopic disease such as Leptospirosis, bacterial cholangiohepatitis, chronic active hepatitis, copper-associated hepatotoxicity, other hepatotoxicity, infiltrative neoplasia (considered unlikely), etc. cannot be definitively ruled out.

INTERPRETATION OF THE FINDINGS & FURTHER RECOMMENDATIONS

Bile acids are recommended, if tбили is not increased. An empirical course of antibiotics and hepatic nutraceuticals may be tried empirically; however, ultimately, tissue sampling is likely warranted. FNA of the liver can be performed to assess inflammatory cell type, rule in/out round cell neoplasia, etc. If round cell neoplasia is not diagnosed, a liver biopsy (including copper level assessment) may be required to definitively diagnose the underlying hepatopathy.





The information and recommendations provided are based on the images presented by the referring veterinarian/sonographer. No evaluation can be communicated regarding pathology that was not visible in the image/video clips provided.

Thank you for this referral. If the clinical or image interpretation does not parallel your findings or if I can be of any further assistance please contact me.

Beth Johnson, DVM, DACVIM
 info@sonopath.com