

**DATE**

6/27/22

**PRESENTING CLINICAL SIGNS**

Patient presented for lethargy, decreased appetite. acute change to feces color- now orange. O unclear if urine has changed color but noted to be orange on cysto. On exam patient was generally ADR with no significant findings. Brief abd us showed potential mid abdominal mass, origin unknown. Labs show slight anemia at 32%, non regenerative at 22.4k retics. Chem showed TBili at 0.6 as only significant abnormality. UA showed 1.028 with trace protein and 3+ Bili

**PATIENT**

Cooper ORourke

Current Medications: None.

Radiographs: Brief abd us showed potential mid abdominal mass, origin unknown.

Date of Previous IntraPet Ultrasound: No previous.

**SPECIES**

Canine

Sedation: Not required to complete full diagnostic ultrasound.

Stat Report: Not requested.

Imaging Performed By: Stephanie Pearce RDCS, RVT.

**BREED**

Beagle Mix

**ULTRASONOGRAPHIC EXAMINATION OF THE ABDOMEN****SEX**

Neutered male

**Urinary System**

Urinary bladder is only mildly distended (empty). Visible contents are anechoic. Urinary bladder wall is unable to be fully assessed for pathology without further distension. No visible masses or cystoliths are observed. The trigone and visible pelvic urethra are normal thickness with a smooth mucosal surface. If there are urinary signs and/or concern for urinary bladder pathology, reassessment after complete filling is recommended.

**AGE**

2/26/12

The prostate is not able to be well visualized, yet the region was examined without evidence of pathology.

**WEIGHT**

41.6 lbs

Left kidney is normal is size (6.14 cm), shape and echogenicity. It has smooth peripheral margination. There is a normal 1:3 cortex to medulla ratio with appropriate corticomedullary distinction. There is no evidence of pyelectasia, mineral or infarcts observed.

**INTERPRETED BY**Beth Johnson, DVM  
DACVIM

Right kidney is normal is size (5.87 cm), shape and echogenicity. It has smooth peripheral margination. There is a normal 1:3 cortex to medulla ratio with appropriate corticomedullary distinction. There is no evidence of pyelectasia, mineral or infarcts observed.

**HOSPITAL NAME**

Everhart VH

**Adrenal Glands**

Left adrenal gland is normal in size (1.94 cm long, 0.41 cm at cranial pole and 0.62 cm at caudal pole), shape and overall architecture, echogenicity and echotexture. Visible surrounding vasculature appears normal.

Right adrenal gland is normal in size (2.07 cm long, 0.81 cm at cranial pole and 0.71 cm at caudal pole), shape and overall architecture, echogenicity and echotexture. Visible surrounding vasculature appears normal.

**REFERRING VET**

Dr. Hays

**Spleen**

Spleen is subjectively large in size with a mildly swollen but smooth capsule. Parenchyma is normal and homogenous in echogenicity and echotexture. Approximately 1.0 cm hypoechoic, non-capsular disrupting nodule was noted in the mid body. Splenic vasculature appears normal.

**INVOICE**

31263

**Liver**

Liver is subjectively normal in size with normal smooth curvilinear peripheral contour. Parenchyma is appropriately hypoechoic to the spleen in echogenicity and appropriately mildly coarse and homogenous in echotexture. No focal lesions are observed. Visible vasculature and biliary tree appear normal without distension or congestion.

Gallbladder is non-distended in size. The wall is smooth without visible thickening. Luminal contents are primarily anechoic. There is no evidence of cystic or common bile duct dilation.

### ***Gastrointestinal***

The visible stomach wall is normal in thickness and layering. The lumen of the stomach is mildly distended with very echogenic reverberation artifact from intraluminal gas. Pyloric outflow tract appears patent. A more prominent, echogenic, curvilinear interface with a stronger acoustic shadow than expected for gas near the pylorus. There was no obstructive pattern/distension, etc. is appreciated.

The visible small intestines are normal in wall thickness and layering. Small intestinal motility appears adequate (1-3 contractions per min). The lumen of the small intestine is empty with no evidence of obstruction, foreign material or infiltrative disease.

The visible colon is normal in wall thickness (< 0.2 cm) and layering. Contents are consistent with normal formed feces and gas.

### ***Pancreas***

The observed pancreas appears appropriately isoechoic to surrounding omental fat. Visible capsule is smooth and normal in contour. Visible pancreatic parenchyma is homogenous and unremarkable. There is no visible pancreatic duct dilation. There is no evidence of active peripancreatic inflammation.

### ***Free Abdomen***

There is no evidence of peritoneal effusion or apparent lymphadenopathy noted in these images.

## **ULTRASONOGRAPHIC FINDINGS**

### **PRIMARY FINDINGS:**

**Hypersplenism** – can be associated with congestion caused by sedation (if sedated) but can also be associated with diffuse infiltrative disease. Both benign conditions such as extramedullary hematopoiesis, lymphoid hyperplasia, as well as infiltrative neoplastic diseases such as round cell neoplasia should be considered.

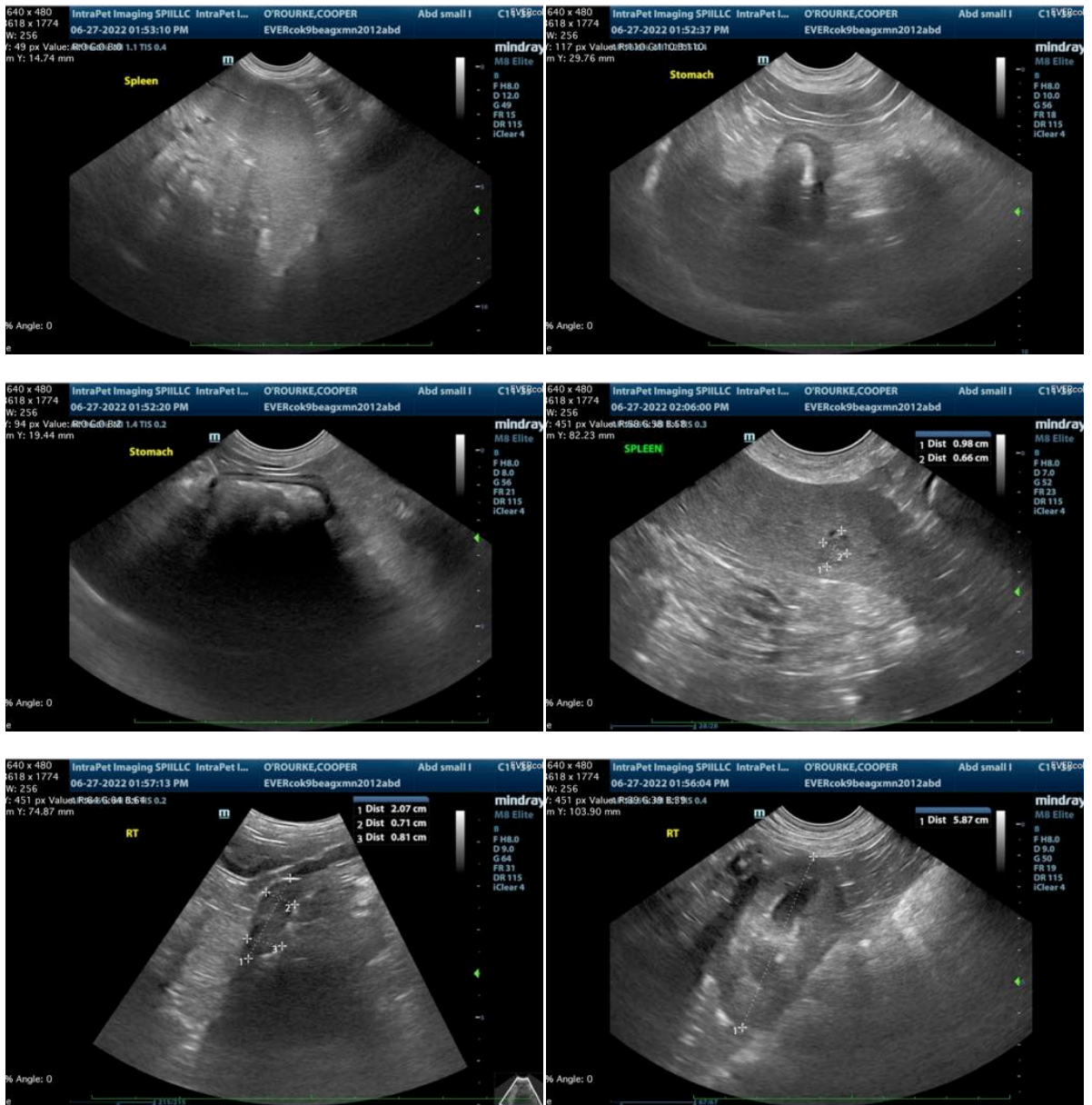
**Hypo to anechoic splenic nodule** – likely represents a benign lesion such as a cyst, hematoma, nodular hyperplasia, extramedullary hematopoiesis, etc., however, infiltrative neoplasia can mimic benign lesions and cannot be ruled out (while considered highly less likely).

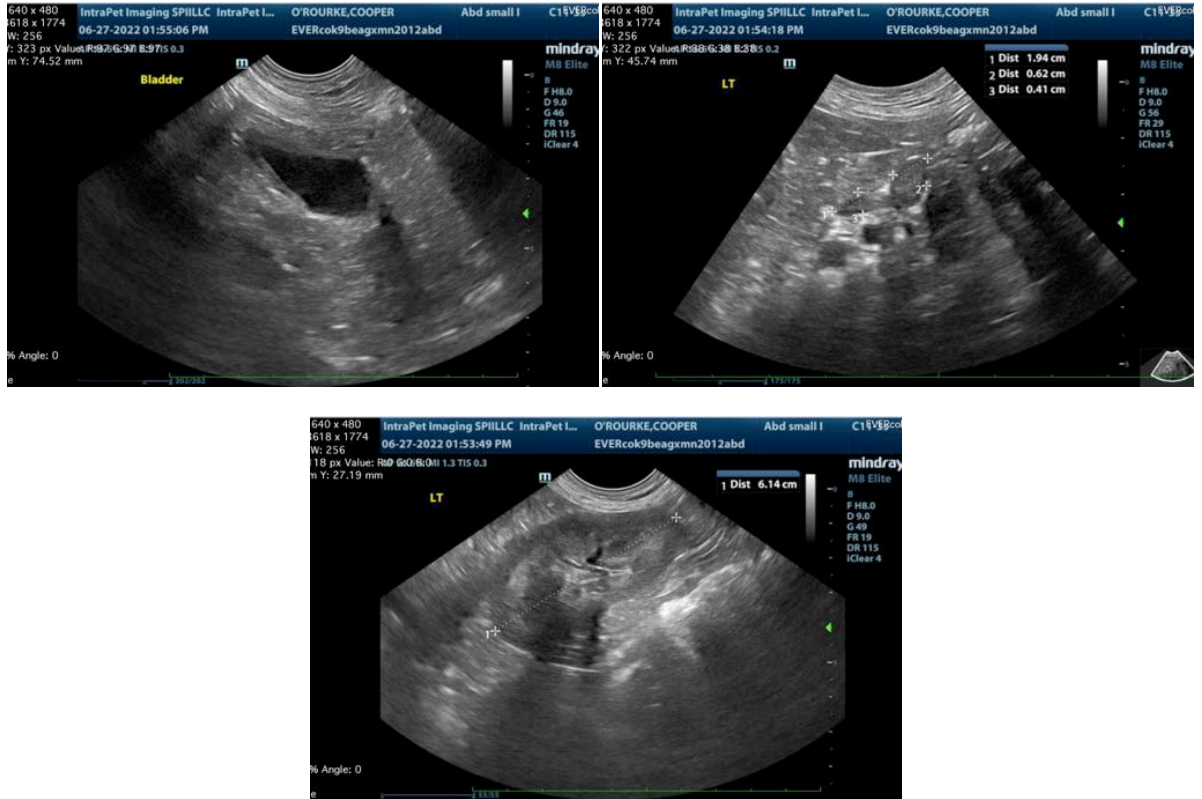
The echogenic interface with strong acoustic shadow in the stomach could represent a non-obstructive, small foreign object. However, normal ingesta/gas cannot be ruled out.

## **INTERPRETATION OF THE FINDINGS & FURTHER RECOMMENDATIONS**

- There are no obvious ultrasonographic causes to explain this patient's malaise and lethargy. Abdominal radiographs are recommended to rule out a metallic foreign body potentially contributing to the mild anemia/hemolysis.
- FNA of the spleen can be considered if the patient's coagulation status is appropriate.
- Given the malaise and lethargy a baseline cortisol can be considered to rule out unlikely, but possible hypoadrenocorticism if another reason cannot be found. If the baseline cortisol is less than 2 then a full follow-up ACTH stimulation test is recommended.

- Finally if the depression persists without an identifiable cause, a neurologic evaluation may be warranted.





The information and recommendations provided are based on the images presented by the referring veterinarian. No evaluation can be communicated regarding pathology that was not visible in the image/video clips provided.

Thank you for this referral. If the clinical or image interpretation does not parallel your findings or if I can be of any further assistance please contact me.

Beth Johnson, DVM DACVIM

Beth.Johnson@SonoPath.com