



PATIENT

Twobit Allen

SPECIES

Feline

BREED

DSH

SEX

Spayed Female

AGE

17 Years

WEIGHT

10.1 Pounds

INTERPRETED BY

Beth Johnson, DVM
DACVIM

IMAGING PERFORMED BY

Meghan Myers, DVM

HOSPITAL NAME

Hershire AH

REFERRING VET

Meghan Myers, DVM

INVOICE

16297

DATE

6/24/22

PRESENTING CLINICAL SIGNS

History: Pet presented with jaundice, decreased appetite, lethargy. No vomiting noted. Treated with sq fluids, cerenia and mirtaz while waiting to get ultrasound done- did show some improvement with appetite.

Abnormal PE/Chem/CBC/UA Results: cbc- monocytosis chem: increased t.bili (9.7), increased alt (598) increased ast (213) normal alkp spec fpl- increased at 4.4 (0-3.5) t4- wnl u/a- 3+ bilirubin, usg 1034, rare rods present (cysto sample)

ULTRASONOGRAPHIC EXAMINATION OF THE ABDOMEN

Urinary System

Urinary bladder is adequately distended with anechoic contents. No masses, inflammatory changes, echogenic sediment or cystoliths are observed. The urinary bladder, trigone and visible pelvic urethra are normal in thickness with a smooth mucosal surface.

The bilateral kidneys are overall normal in size and shape with smooth peripheral margination. A normal 1:3 cortex to medulla ratio is maintained. The medulla and cortices are uniform in texture with some mild increased cortical echogenicity and mild loss of corticomedullary distinction, expected in this age patient. There is no evidence of mineral or infarcts observed in the right kidney. Mild pyelectasia is noted in the left kidney. The left kidney measures 3.6 cm. The right kidney measures 4.0 cm.

Adrenal Glands

Left adrenal gland is normal in size (0.37 cm), shape and overall architecture, echogenicity and echotexture. Visible surrounding vasculature appears normal.

Right adrenal gland is normal in size (0.54 cm), shape and overall architecture, echogenicity and echotexture. Visible surrounding vasculature appears normal.

Spleen

Spleen is subjectively large in size with subtly scalloped or undulating capsular contour. Parenchyma is normal in echogenicity with a mildly coarse/heterogenous echotexture. No focal nodules or masses are observed. Splenic vasculature appears normal.

Liver

Liver is subjectively enlarged (swollen contour) without disruption of architecture. It has a normal homogenous echotexture. Parenchyma is diffusely hyperechoic characterized by less prominent than normal portal vein walls and increased echogenicity relative to the spleen and falciform fat. No focal lesions are observed. Multifocal intrahepatic biliary stones are noted.

Gallbladder is moderately distended in size with a thick hyperechoic wall and a large amount of mineral debris within the gallbladder. The cystic and common bile duct are markedly dilated, measuring over 1.0 cm dilated, leading to a cholecystolith with multiple other smaller cholecystoliths throughout the duct, combined with thick hyperechoic irregular duct walls and echogenic debris/sludge within the duct. A mineralized biliary mass cannot be ruled out but is difficult to distinguish due to the multiple cholecystoliths throughout the entire biliary system.

Gastrointestinal



PATIENT

Twobit Allen

The visible stomach wall is normal in thickness and layering. The lumen of the stomach is empty with no evidence of obstruction, foreign material or infiltrative disease. Pyloric outflow tract appears patent.

SPECIES

Feline

The visible small intestine demonstrates areas of thick muscularis layer relative to mucosa (disruption of the normal 1:3 muscularis:mucosa ratio). Small intestinal submucosa is slightly irregular, thick and hyperechoic, without evident loss of layering appreciated. The lumen of the small intestine is empty without evidence of obstruction or foreign material.

BREED

DSH

The visible colon is normal in wall thickness and layering. Contents are consistent with normal formed feces and gas.

SEX

Spayed Female

The observed pancreas appears appropriately isoechoic to surrounding omental fat. Visible capsule is smooth and normal in contour. Visible pancreatic parenchyma is homogenous and unremarkable. There is no visible pancreatic duct dilation. There is no evidence of active peripancreatic inflammation.

AGE

17 Years

Free Abdomen

There is no evidence of peritoneal effusion. There is no apparent lymphadenopathy.

ULTRASONOGRAPHIC FINDINGS

WEIGHT

10.1 Pounds

Primary Findings

- Hypoechoic hepatomegaly This appearance is most consistent with benign hepatic lipidosis. Infiltrative disease such as amyloidosis or round cell neoplasia, such as mast cell tumor or less likely, lymphoma, is also possible. An abundant amount of biliary and posthepatic biliary mineral with marked common bile duct dilation, suggestive of posthepatic cholestasis/obstruction. A mineralized mass cannot be ruled out but is not apparently visible in these images.
- Scalloped spleen can be associated with benign or malignant infiltrative disease. Common causes include a reactive spleen secondary to immune stimulus or early infiltrative round cell neoplasia such as lymphoma or mast cell tumor.
- Inflammatory bowel disease pattern. This finding has been reported with infiltrative bowel disease including both benign inflammatory disease as well as infiltrative neoplasia such as lymphoma. No concurrent lymphadenopathy, loss of layering, etc. is noted to make lymphoma more probably, but lymphoma cannot be definitively ruled out without tissue sampling.

INTERPRETED BY

Beth Johnson, DVM
DACVIM

IMAGING PERFORMED BY

Meghan Myers, DVM

HOSPITAL NAME

Hershire AH

REFERRING VET

Meghan Myers, DVM

Secondary Findings

- Age-related kidney change with mild right kidney pyelectasia

INTERPRETATION OF THE FINDINGS & FURTHER RECOMMENDATIONS

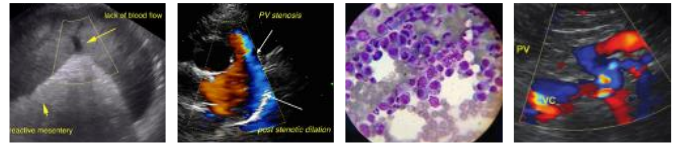
This patient has evidence of infiltrative disease possibly involving the spleen, liver and the bowel. However, the apparent cause of the acute illness, jaundice, etc. is a posthepatic biliary obstruction caused by a cholelith. Ultimately, an exploratory laparotomy may be necessary to alleviate the obstruction, at which time liver and GI +/- splenic biopsies should be obtained. However, if a more conservative approach is elected, a fine needle aspirate of the spleen and liver could be obtained to look for evidence of infiltrative round cell neoplasia while aggressively managing cholangiohepatitis with IV fluids, antiemetics, appetite stimulants (if necessary), pain management (as indicated) and

INVOICE

16297

DATE

6/24/22



PATIENT

broad-spectrum antibiotics. A urine culture is recommended prior to starting antibiotics given the reported bacteriuria. If this conservative approach is elevated, it's important to closely monitor liver enzymes for progression, at which time surgery would be the necessary approach.

Twobit Allen

SPECIES

Feline

BREED

DSH

SEX

Spayed Female

AGE

17 Years

WEIGHT

10.1 Pounds

INTERPRETED BY

Beth Johnson, DVM
DACVIM

IMAGING PERFORMED BY

Meghan Myers, DVM

HOSPITAL NAME

Hershire AH

REFERRING VET

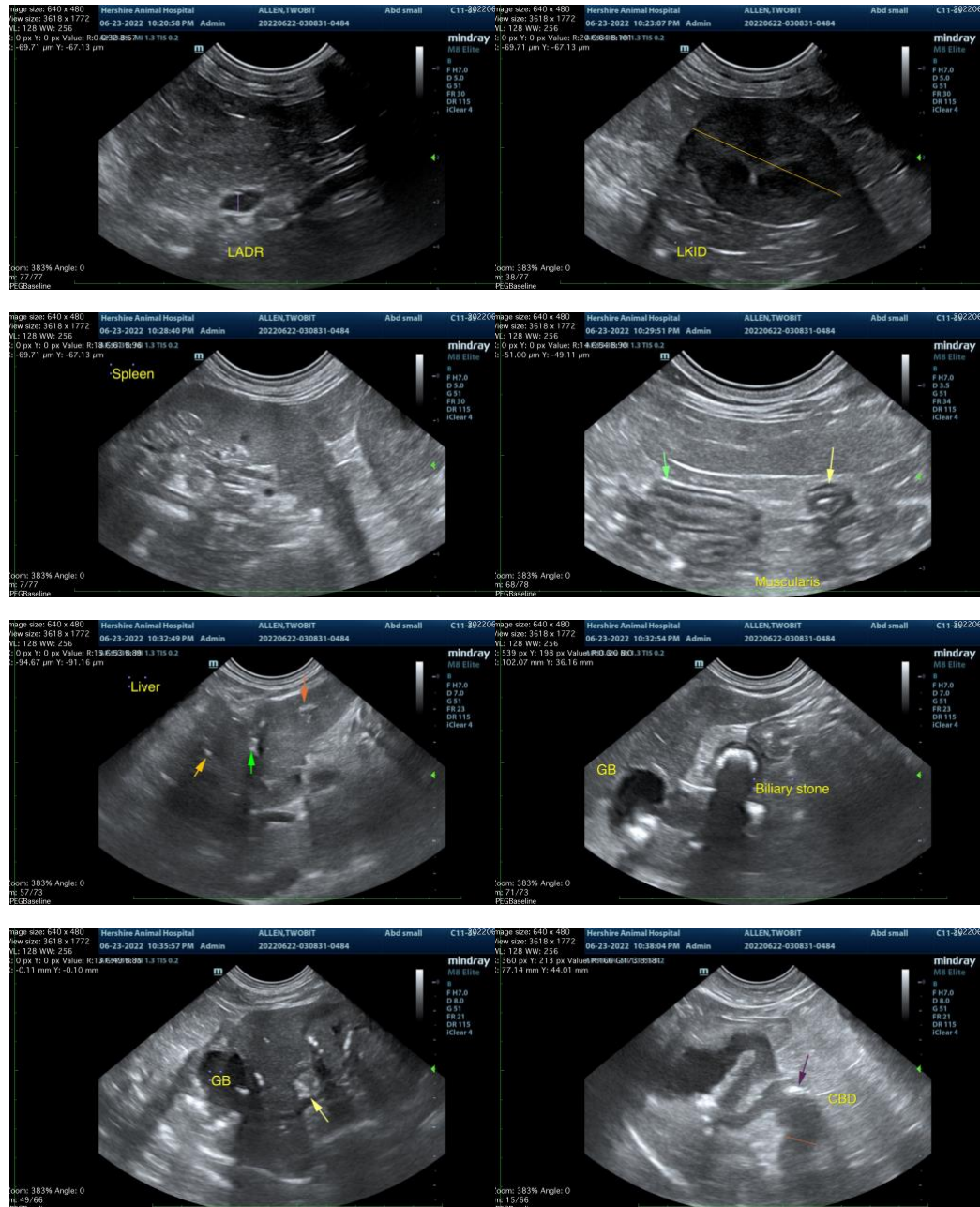
Meghan Myers, DVM

INVOICE

16297

DATE

6/24/22





PATIENT

Twobit Allen

SPECIES

Feline

BREED

DSH

SEX

Spayed Female

AGE

17 Years

WEIGHT

10.1 Pounds

INTERPRETED BY

Beth Johnson, DVM
DACVIM

IMAGING PERFORMED BY

Meghan Myers, DVM

HOSPITAL NAME

Hershire AH

REFERRING VET

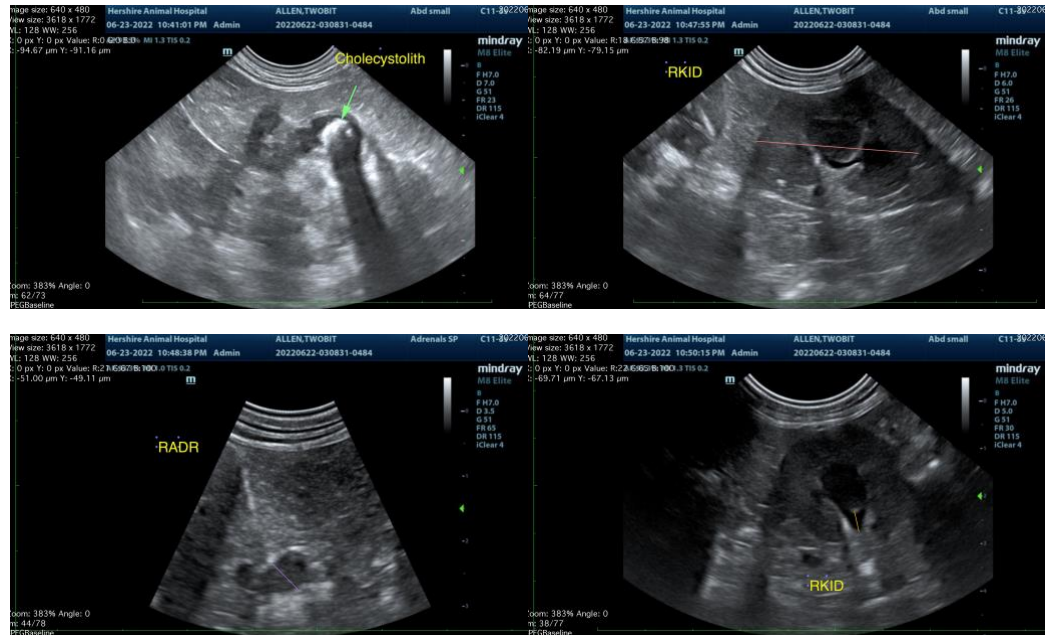
Meghan Myers, DVM

INVOICE

16297

DATE

6/24/22



The information and recommendations provided are based on the images presented by the referring veterinarian. No evaluation can be communicated regarding pathology that was not visible in the image/video clips provided.

Thank you for this referral. If the clinical or image interpretation does not parallel your findings or if I can be of any further assistance please contact me.

Beth Johnson, DVM DACVIM

Beth.Johnson@SonoPath.com