

**DATE**

6/24/22

**PRESENTING CLINICAL SIGNS****PATIENT**

Arlie Eidsmore

History: P was discharged on Thursday from AEH. O said that P was doing fine until Monday P went to rDVM and had repeat bloodwork which showed elevations in liver values (ALT: 217, ALP:840). but minimal change since repeat bloodwork here. Platelets were adequate, WBC increased. O said that Monday night P did not want to eat and O has been struggling to give medications. P has been lethargic and not himself.

**SPECIES**

Canine

Current Medications: None listed.

Date of Previous IntraPet Ultrasound: 6/14/22. See attached.

Sedation: Not required to complete full diagnostic ultrasound.

Stat Report: Not requested.

**BREED**

Labrador

Imaging Performed By: Rachel Brillhart, RDMS.

**ULTRASONOGRAPHIC EXAMINATION OF THE ABDOMEN****SEX**

Neutered Male

**Urinary System**

Urinary bladder is adequately distended with anechoic contents. No masses, inflammatory changes, echogenic sediment or cystoliths are observed. The urinary bladder, trigone and visible pelvic urethra are normal in thickness with a smooth mucosal surface.

**AGE**

6/30/15

Prostate (neutered) is normal in size, echotexture and echogenicity for a neutered male.

**WEIGHT**

85.5 Pounds

Left kidney is normal is size (7.23 cm), shape and echogenicity. It has smooth peripheral margination. There is a normal 1:3 cortex to medulla ratio with appropriate corticomedullary distinction. There is no evidence of pyelectasia, mineral or infarcts observed.

Right kidney is normal is size (7.99 cm), shape and echogenicity. It has smooth peripheral margination. There is a normal 1:3 cortex to medulla ratio with appropriate corticomedullary distinction. There is no evidence of pyelectasia, mineral or infarcts observed.

**INTERPRETED BY**Beth Johnson, DVM  
DACVIM**Adrenal Glands**

Left adrenal gland is normal in size (2.9 cm in length X 0.62 cm at cranial pole and 0.8 cm at caudal pole), shape and overall architecture, echogenicity and echotexture. Visible surrounding vasculature appears normal.

**HOSPITAL NAME**

Animal Emergency H

Right adrenal gland is normal in size (2.76 cm in length X 0.76 cm at cranial pole and 0.78 cm at caudal pole), shape and overall architecture, echogenicity and echotexture. Visible surrounding vasculature appears normal.

**REFERRING VET**

Dr. Roper

**Spleen**

Spleen is subjectively large in size with a mildly swollen but smooth capsule. Parenchyma is normal and homogenous in echogenicity and echotexture. An oblong to round, hypoechoic slightly heterogeneous nodule was present in the mid body of the caudal aspect of the spleen, slightly progressive in size today from the last ultrasound, measuring 3.0 cm x 4.0 cm. Splenic vasculature appears normal.

**INVOICE**

16291

**Liver**

Liver is subjectively enlarged (swollen contour). Mild parenchymal remodeling with diffusely mildly coarse architecture and increased portal markings is present. No focal nodules or masses are observed. Visible vasculature and biliary tree appear normal without distension or congestion.

Gallbladder is moderately distended with anechoic bile as well as suspended and gravity dependent echogenic debris. The wall is smooth without visible thickening. There is no evidence of cystic or CBD dilation. There is no evidence of effusion or inflammation.

### ***Gastrointestinal***

The visible stomach wall is normal in thickness and layering. The lumen of the stomach is empty with no evidence of obstruction, foreign material or infiltrative disease. Pyloric outflow tract appears patent.

The visible small intestines are normal in wall thickness and layering. Small intestinal motility appears adequate (1-3 contractions per min). The lumen of the small intestine is empty with no evidence of obstruction, foreign material or infiltrative disease.

The visible colon is normal in wall thickness and layering. Contents are consistent with normal formed feces and gas.

### ***Pancreas***

The observed pancreas appears appropriately isoechoic to surrounding omental fat. Visible capsule is smooth and normal in contour. Visible pancreatic parenchyma is homogenous and unremarkable. There is no visible pancreatic duct dilation. There is no evidence of active peripancreatic inflammation.

### ***Free Abdomen***

There is a scant amount of free abdominal fluid today that was not appreciated in the previous ultrasound. Similar appearing marked cranial abdominal lymphadenopathy is appreciated. The lymph nodes are round and hypoechoic/heterogeneous in appearance and measure 2.5 cm round to 2.0 cm x 3.0 cm round.

## **ULTRASONOGRAPHIC FINDINGS**

### **Primary Findings**

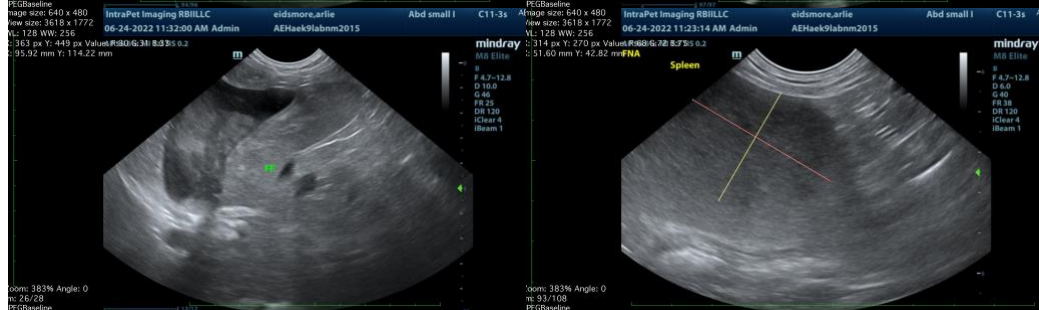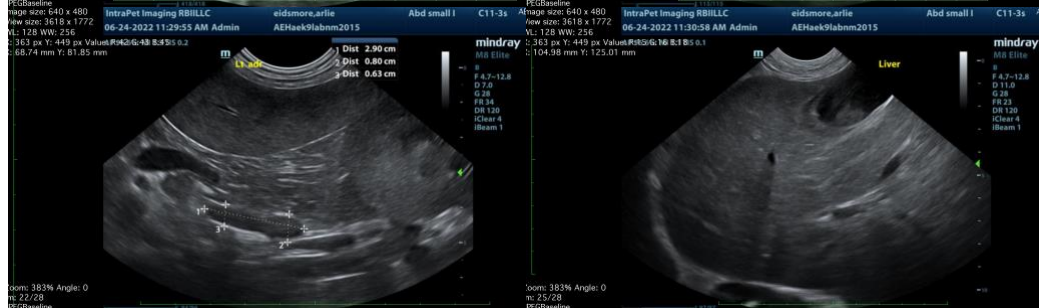
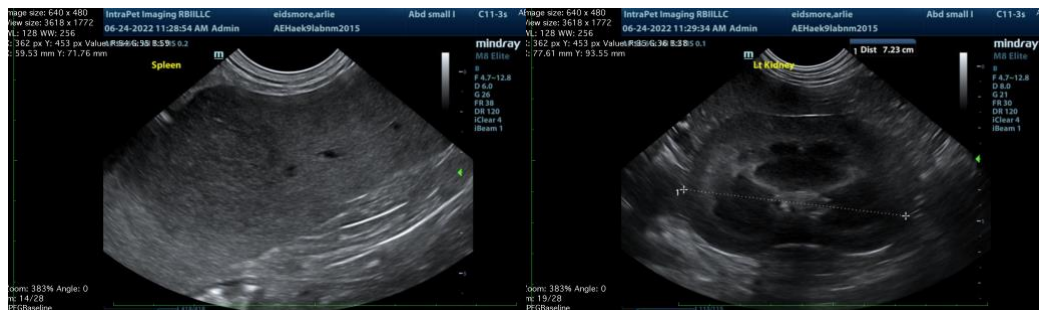
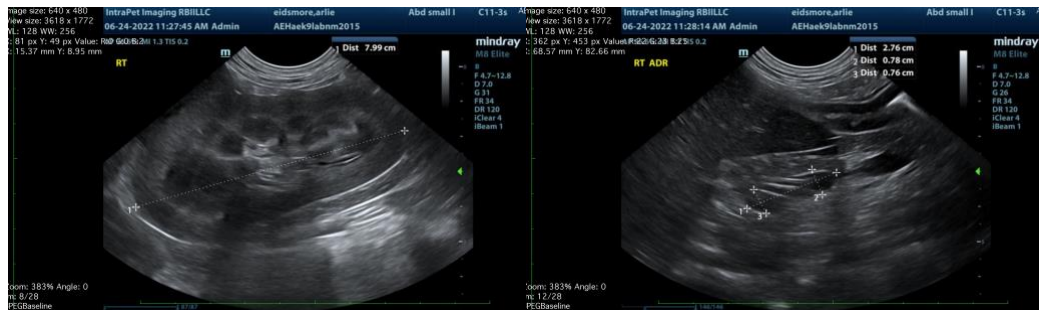- Hypoechoic hepatomegaly. This appearance is most consistent with a benign steroid (endocrine) or vacuolar hepatopathy or reactive or idiopathic hepatopathy. Infiltrative neoplasia such as round cell neoplasia is also possible but considered less likely.
- Hypersplenism can be associated with congestion caused by sedation (if sedated) but can also be associated with diffuse infiltrative disease. Both benign conditions such as extramedullary hematopoiesis, lymphoid hyperplasia, amyloidosis (leave amyloidosis out if canine) as well as infiltrative neoplastic diseases such as round cell neoplasia should be considered. A progressive in size hypoechoic splenic nodule was also present, most concerning for infiltrative neoplasia given the combination of findings in these images. Benign extramedullary hematopoiesis, etc. cannot be ruled out but is considered less likely.
- The diffuse cranial abdominal lymphadenopathy is most consistent with infiltrative round cell or metastatic neoplasia. A benign aggressive inflammatory response cannot be ruled out without tissue sampling +/- culture.

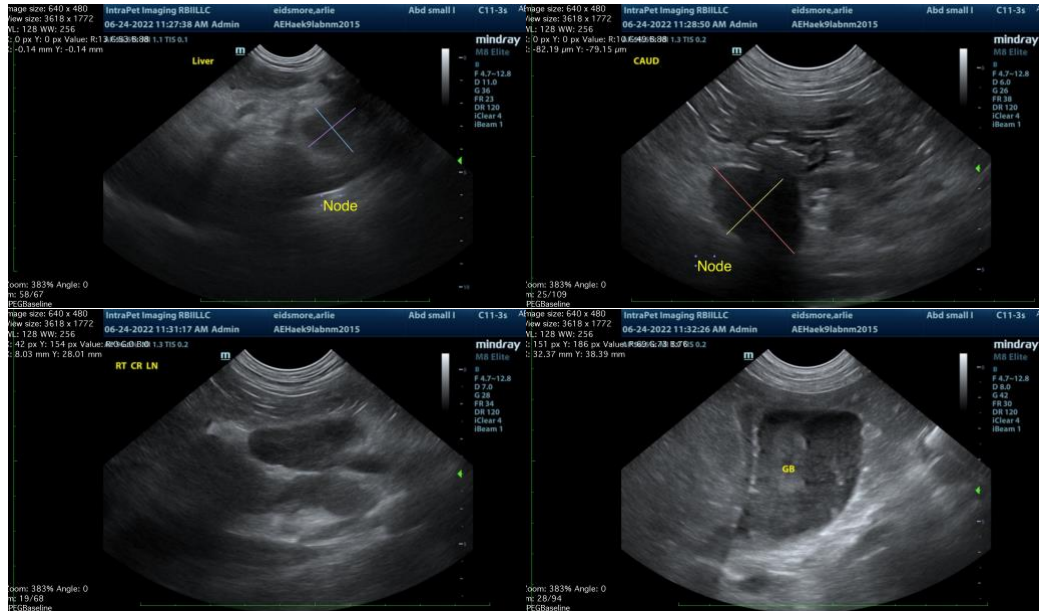
### **Secondary Findings**

- Cholecystic debris is of unknown clinical significance. It can be seen with biliary stasis from fasting or illness. Cholecystic debris is not necessarily related to hepatobiliary disease. Echogenic bile is most commonly an incidental finding in dogs and should be interpreted in combination with clinical signs such as nausea, inappetence, cranial abdominal discomfort and/or laboratory changes such as increased ALP and/or

## INTERPRETATION OF THE FINDINGS & FURTHER RECOMMENDATIONS

Recommendation for this patient include the already performed and pending fine needle aspirate of the liver and spleen to rule in/out suspected round cell neoplasia. If a diagnosis is not obtained cytologically from these aspirates, next steps to consider are fine needle aspirate of the enlarged cranial abdominal lymph nodes.





The information and recommendations provided are based on the images presented by the referring veterinarian. No evaluation can be communicated regarding pathology that was not visible in the image/video clips provided.

Thank you for this referral. If the clinical or image interpretation does not parallel your findings or if I can be of any further assistance please contact me.

**Beth Johnson, DVM DACVM**  
Beth.Johnson@SonoPath.com