**DATE**

6/23/22

**PRESENTING CLINICAL SIGNS**

Recheck ultrasound, 3 months after being diagnosed with early mucocele.  
 Current Medications: 3 month duration of Ursodiol 250mg 1.5 SID, Denamarin SID.  
 Date of Previous IntraPet Ultrasound: 3/3/22. See attached.  
 Sedation: Not required to complete full diagnostic ultrasound.  
 Stat Report: Not requested.  
 Imaging Performed By: Rachel Brillhart, RDMS.

**PATIENT**

Pierce Fry

**SPECIES**

Canine

**BREED**

Pitbull

**SEX**

Neutered male

**AGE**

3/5/08

**WEIGHT**

58.5 lbs

**INTERPRETED BY**Beth Johnson, DVM  
DACVIM**HOSPITAL NAME**

Eastern AH

**REFERRING VET**

Dr. Wu

**INVOICE**

31214

**ULTRASONOGRAPHIC EXAMINATION OF THE ABDOMEN****Urinary System**

Urinary bladder is adequately distended with anechoic contents. No masses, inflammatory changes, echogenic sediment or cystoliths are observed. The urinary bladder, trigone and visible pelvic urethra are normal in thickness with a smooth mucosal surface.

The prostate is normal for a neutered dog.

Left kidney is normal is size (6.38 cm), shape and echogenicity. It has smooth peripheral margination. There is a normal 1:3 cortex to medulla ratio with appropriate corticomedullary distinction. There is no evidence of pyelectasia, mineral or infarcts observed.

Right kidney is normal is size (6.3 cm), shape and echogenicity. It has smooth peripheral margination. There is a normal 1:3 cortex to medulla ratio with appropriate corticomedullary distinction. There is no evidence of pyelectasia, mineral or infarcts observed.

**Adrenal Glands**

Adrenal glands are plump/swollen in size (left adrenal gland measured 3.28 cm long, 0.88 cm at the cranial pole and 0.84 cm at the caudal pole and the right adrenal measured 3.62 cm long, 1.0 cm at the cranial pole and 0.86 cm at the caudal pole). Normal shape and contour are maintained without evidence of capsular invasion. Corticomedullary structure is unremarkable. Visible surrounding vasculature appears normal.

**Spleen**

Spleen is generally normal in size and shape with a smooth capsular contour. Parenchyma is diffusely nodular in appearance characterized by small discrete hypoechoic nodules. Splenic vasculature appears normal.

**Liver**

Liver is subjectively enlarged (swollen contour) without disruption of architecture. It has a normal homogenous echotexture. Parenchyma is diffusely hyperechoic characterized by less prominent than normal portal vein walls and increased echogenicity relative to the spleen and falciform fat. There was a slightly progressive, rounded appearance to the right caudal liver. An emerging homogenous, isoechoic mass cannot be ruled out. No focal lesions are observed. Visible vasculature and biliary tree appear normal without distension or congestion.

Gallbladder is moderately overdistended with organized, aggregated and centralized non-gravity dependent sludge. Striations of sludge separated by anechoic areas are noted extending from the lumen to the luminal wall. The wall is mildly thick, irregular and hyperechoic. There is no evidence of CBD dilation.

### ***Gastrointestinal***

The visible stomach wall is normal in thickness and layering. The lumen of the stomach is mildly distended with very echogenic reverberation artifact from intraluminal gas. There is no evidence of obstruction, foreign material or infiltrative disease; however, complete visualization of far wall is partially inhibited by gas. Pyloric outflow tract appears patent.

The visible small intestines are normal in wall thickness and layering. Small intestinal motility appears adequate (1-3 contractions per min). The lumen of the small intestine is empty with no evidence of obstruction, foreign material or infiltrative disease.

The visible colon is normal in wall thickness (< 0.2 cm) and layering. Contents are consistent with normal formed feces and gas.

### ***Pancreas***

The observed pancreas appears appropriately isoechoic to surrounding omental fat. The capsule is mildly irregular in shape. Parenchyma is mildly heterogenous and coarse. There is no visible pancreatic duct dilation. There is no evidence of active peripancreatic inflammation.

### ***Free Abdomen***

There is no evidence of peritoneal effusion or apparent lymphadenopathy noted in these images.

## **ULTRASONOGRAPHIC FINDINGS**

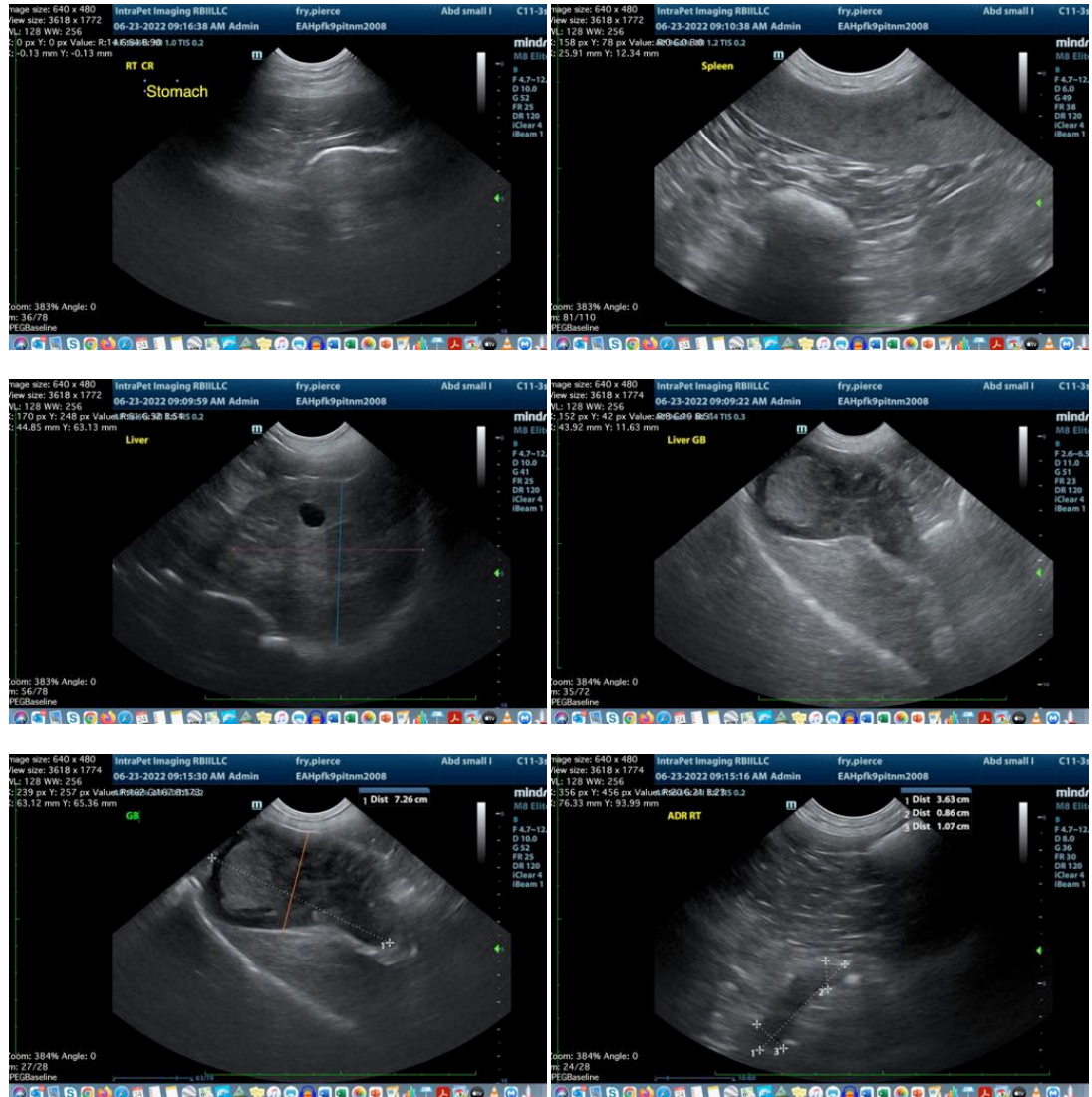
1. **Gallbladder mucocele.** The change in this study appears subjectively slightly progressive. However, there is no evidence of enhanced, hyperechoic tissue, free fluid, etc. to indicate inflammation.
2. **Hyperechoic hepatomegaly (canine)** – This appearance is most consistent with a benign steroid (endocrine) or vacuolar hepatopathy or reactive or idiopathic hepatopathy. Infiltrative neoplasia such as round cell neoplasia is also possible, but considered less likely.
3. Mild progressive, rounded appearance to the caudal right liver and emerging early mass cannot be ruled out.
4. **Splenic micronodular hyperplasia pattern**– This nodular change is often associated with benign aging nodular hyperplasia. Infiltrative neoplasia, however, including both early hemangiosarcoma as well as round cell neoplasia cannot be ruled out.
5. **Bilateral adrenomegaly** – consistent with adrenal hyperplasia secondary to pituitary dependent hyperadrenocorticism vs stress or normal variant. Interpret in combination with clinical signs of hyperadrenocorticism.
6. **Pancreatic age related remodeling.** Mild irregularities are consistent with benign age-related change. Low-grade smoldering chronic pancreatitis cannot be ruled out and should be suspected in the face of appropriate clinical signs.

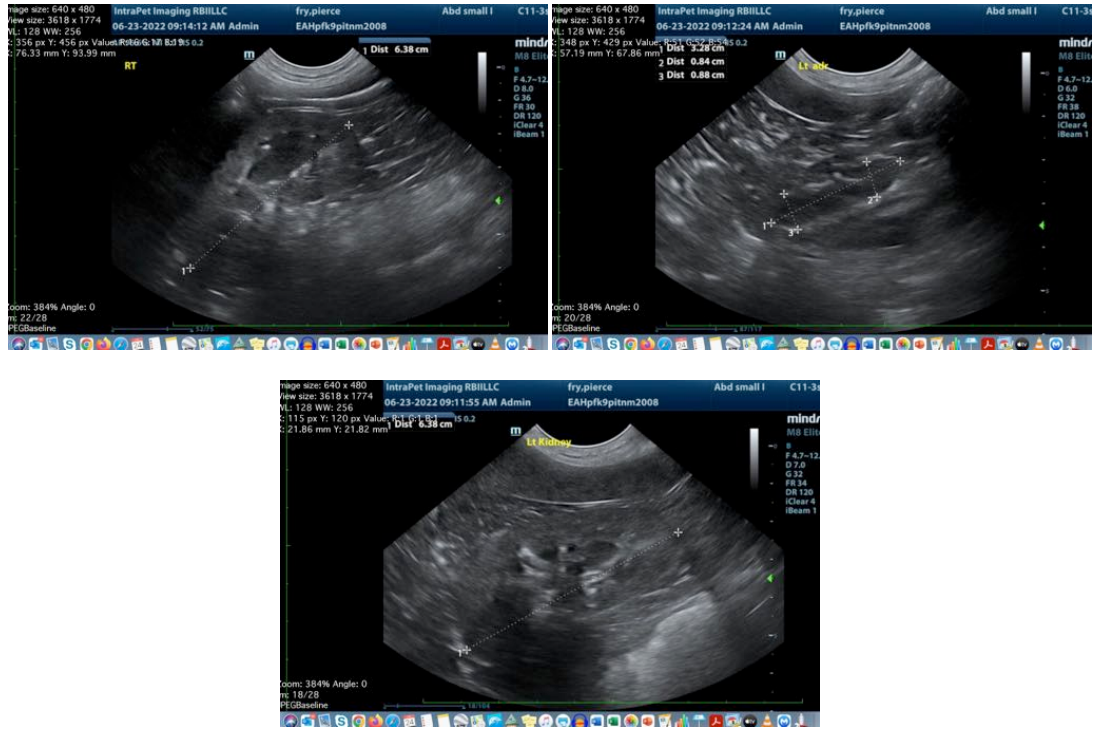
## **INTERPRETATION OF THE FINDINGS & FURTHER RECOMMENDATIONS**

At the time of initial exam this patient was reportedly having gastrointestinal signs and had a markedly increased ALT. If clinical signs and/or laboratory changes have or are improving continued current medical management is recommended, as ultrasonographic changes don't always match/follow laboratory value improvement. If however gastrointestinal signs have persisted and/or there is cranial abdominal pain, etc. a

cholecystectomy could still be considered.

If the primary abnormality is still ALT versus ALKP, and not already evaluated, testing for Leptospirosis as well as a FNA of the liver +/- the spleen, if the patient's coagulation status is appropriate, can be considered.





The information and recommendations provided are based on the images presented by the referring veterinarian. No evaluation can be communicated regarding pathology that was not visible in the image/video clips provided.

Thank you for this referral. If the clinical or image interpretation does not parallel your findings or if I can be of any further assistance please contact me.

Beth Johnson, DVM DACVIM

Beth.Johnson@SonoPath.com