



**PATIENT PRESENTING CLINICAL SIGNS**

**Patient:** Birdie Ness  
**History:** Previously diagnosed with diabetes mellitus which went into remission ~6 months ago. Decreased appetite at home, owner reports drinking more water. Concern for recurrence of diabetes - recent bloodwork shows hypercalcemia. Currently feeding z/d due to suspected IBD.  
**Species:** Feline  
**Abnormal PE/Chem/CBC/UA Results:** Bloodwork 6/18/22: SDMA 18 (0-14) Calcium 12.9 (8.2-11.2) Cholesterol 330 (91-305) Fructosamine 365 (191-349) Glucose 121 (72-125) GI Panel (Feb 2022) Spec fPL - 1.5 (0.0-3.5) TLI - 37.8 (12-82) Cobalamine - 638 (276-1425) Folate - 14.7 (8.9-19.9)

**BREED ULTRASONOGRAPHIC EXAMINATION OF THE ABDOMEN**

Domestic Shorthair

**Urinary System**

**SEX**

Neutered male

Urinary bladder is adequately distended. It has a normal uniform wall thickness. Contents include primarily anechoic fluid with occasional echogenic non-shadowing debris, most consistent with incidental suspended lipid in a cat, possibly combined with exfoliated cells, mucous and/or small blood clots. Both sterile inflammation as well as urinary tract infection can also present with echogenic debris. No masses or cystoliths are observed. The trigone and visible pelvic urethra are normal in thickness with a smooth mucosal surface.

**AGE**

10 years

Left kidney is normal is size (4.43 cm), shape and echogenicity. It has smooth peripheral margination. There is a normal 1:3 cortex to medulla ratio with appropriate corticomedullary distinction. There is no evidence of pyelectasia, mineral or infarcts observed.

**WEIGHT**

12.1 lbs

Right kidney is normal is size (3.92 cm), shape and echogenicity. It has smooth peripheral margination. There is a normal 1:3 cortex to medulla ratio with appropriate corticomedullary distinction. There is no evidence of pyelectasia, mineral or infarcts observed.

**INTERPRETED BY**

Beth Johnson, DVM  
DACVIM

**Adrenal Glands**

Left adrenal gland is normal in size (0.4 cm at cranial pole and 0.39 cm at caudal pole), shape and overall architecture, echogenicity and echotexture. Visible surrounding vasculature appears normal.

**IMAGING PERFORMED BY**

Jack Reese DVM

Right adrenal gland is normal in size (0.47 cm thick), shape and overall architecture, echogenicity and echotexture. Visible surrounding vasculature appears normal.

**HOSPITAL NAME**

Willow Run VC

**Spleen**

Spleen is subjectively normal in size with a normal smooth capsular contour. Parenchyma is appropriately finely textured and homogenous with normal echogenicity relative to surrounding tissue (hyperechoic to liver). No focal nodules or masses are observed. Splenic vasculature appears normal.

**REFERRING VET**

Dr. Reese

**Liver**

**INVOICE**

31209

Liver is subjectively normal in size with normal smooth curvilinear peripheral contour. Parenchyma is appropriately hypoechoic to the spleen in echogenicity and appropriately mildly coarse and homogenous in echotexture. No focal lesions are observed. Visible vasculature and biliary tree appear normal without distension or congestion.

**DATE**

6/23/22



<b>PATIENT</b>	Gallbladder is non-distended in size. The wall is smooth without visible thickening. Luminal contents are primarily anechoic. There is no evidence of cystic or common bile duct dilation.
Birdie Ness	
<b>SPECIES</b>	<b>Gastrointestinal</b>
Feline	The visible stomach wall is normal in thickness and layering. The lumen of the stomach is empty with no evidence of obstruction, foreign material or infiltrative disease. Pyloric outflow tract appears patent.
<b>BREED</b>	The visible small intestine demonstrates areas of thick muscularis layer relative to mucosa (disruption of the normal 1:3 muscularis:mucosa ratio). Small intestinal submucosa is slightly irregular, thick and hyperechoic, without evident loss of layering appreciated. The lumen of the small intestine is empty with no evidence of obstruction, foreign material or infiltrative disease.
Domestic Shorthair	
<b>SEX</b>	The visible colon is normal in wall thickness (< 0.2 cm) and layering. Contents are consistent with normal formed feces and gas.
Neutered male	
<b>AGE</b>	<b>Pancreas</b>
10 years	The observed pancreas appears appropriately isoechoic to surrounding omental fat. Visible capsule is smooth and normal in contour. Visible pancreatic parenchyma is homogenous and unremarkable. There is no visible pancreatic duct dilation. There is no evidence of active peripancreatic inflammation.
<b>WEIGHT</b>	<b>Free Abdomen</b>
12.1 lbs	Lymph node(s) is(are) prominent in size with swollen capsular contour. Normal elongated shape (length to width ratio) is maintained. There is no loss of parenchymal detail.
<b>INTERPRETED BY</b>	
Beth Johnson, DVM DACVIM	
<b>IMAGING PERFORMED BY</b>	<b>ULTRASONOGRAPHIC FINDINGS</b>
Jack Reese DVM	<b>Primary Findings</b>
<b>HOSPITAL NAME</b>	<b>Inflammatory bowel disease pattern (IBD)</b> - This finding has been reported with infiltrative bowel disease including both benign inflammatory disease as well as infiltrative neoplasia such as lymphoma. No aggressive lymphadenopathy, loss of layering, etc. is noted to make lymphoma more probably, but lymphoma cannot be definitively ruled out without tissue sampling.
Willow Run VC	<b>Reactive lymph nodes</b> – infiltrative neoplastic disease cannot be ruled out but is considered less likely
<b>REFERRING VET</b>	<b>Secondary Findings</b>
Dr. Reese	<b>Urinary bladder debris.</b>
<b>INVOICE</b>	
31209	
<b>DATE</b>	
6/23/22	



**PATIENT**

Birdie Ness

**SPECIES**

Feline

**BREED**

Domestic Shorthair

**SEX**

Neutered male

**AGE**

10 years

**WEIGHT**

12.1 lbs

**INTERPRETED BY**

Beth Johnson, DVM  
DACVIM

**IMAGING PERFORMED BY**

Jack Reese DVM

**HOSPITAL NAME**

Willow Run VC

**REFERRING VET**

Dr. Reese

**INVOICE**

31209

**DATE**

6/23/22

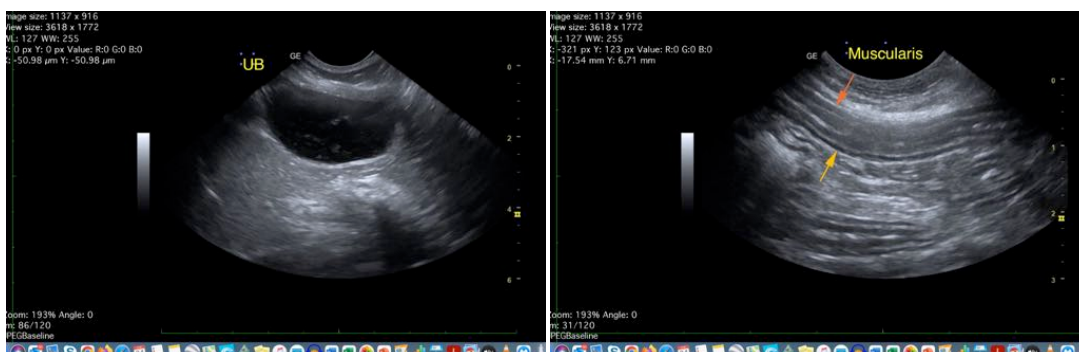
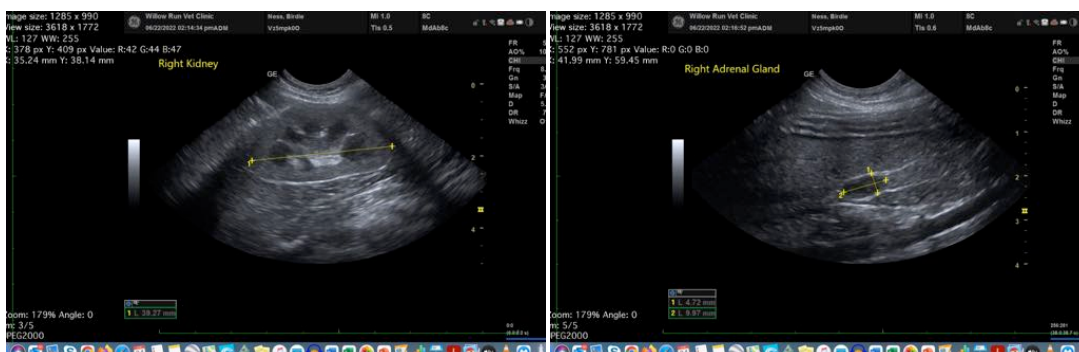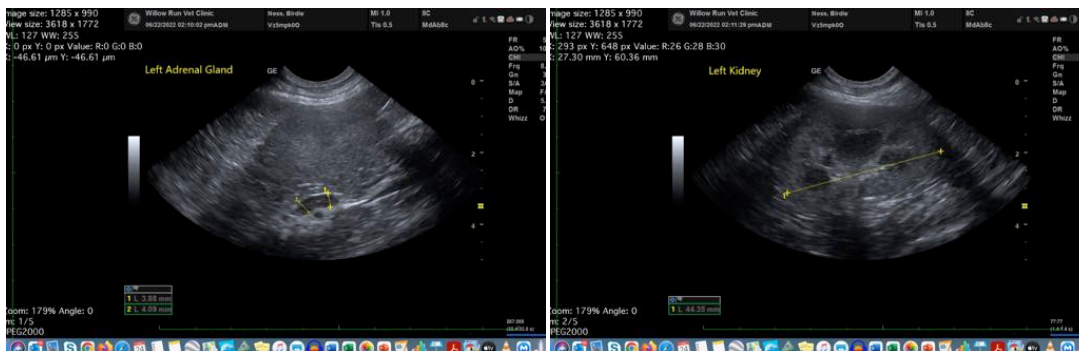
**INTERPRETATION OF THE FINDINGS & FURTHER RECOMMENDATIONS**

The ultrasound findings are consistent with the reported history of inflammatory bowel disease; however, given the new hypercalcemia infiltrative lymphoma has to be considered.

Recommendations include further evaluation of the hypercalcemia in the form of a malignancy panel to include PTH, PTHrP and ionized calcium.

Pending the results of the malignancy panel, biopsies of the GI tract ensuring to include ileum if possible are recommended to definitively diagnose and manage the infiltrative bowel disease.

Urinalysis and, if indicated based on urinalysis results, urine culture are recommended. If protein is present in an otherwise quiet sediment, protein quantification with a urine protein to creatinine ration is recommended.





**PATIENT**

Birdie Ness

**SPECIES**

Feline

**BREED**

Domestic Shorthair

**SEX**

Neutered male

**AGE**

10 years

**WEIGHT**

12.1 lbs

**INTERPRETED BY**

Beth Johnson, DVM  
DACVIM

**IMAGING  
PERFORMED BY**

Jack Reese DVM

**HOSPITAL NAME**

Willow Run VC

**REFERRING VET**

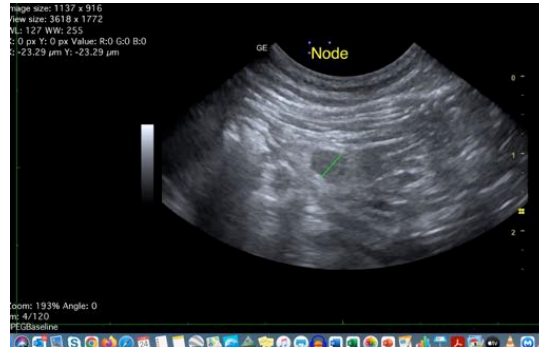Dr. Reese

**INVOICE**

31209

**DATE**

6/23/22



The information and recommendations provided are based on the images presented by the referring veterinarian/sonographer. No evaluation can be communicated regarding pathology that was not visible in the image/video clips provided.

Thank you for this referral. If the clinical or image interpretation does not parallel your findings or if I can be of any further assistance please contact me.

**Beth Johnson, DVM DACVIM**

Beth.Johnson@SonoPath.com