

**PATIENT**

Sophia Amalio

SPECIES

Canine

BREED

Yorkie

SEX

Spayed Female

AGE

7 Years

WEIGHT

8.6 Pounds

INTERPRETED BYBeth Johnson, DVM
DACVIM**IMAGING PERFORMED BY**

Amy Mayhew, LVT

HOSPITAL NAME

SVS Imaging MI

REFERRING VET

Dr. Totin

INVOICE

43379

DATE

6/22/23

PRESENTING CLINICAL SIGNS

Chronic allergies, chronic urinary tract infections as well as vaginitis Current ecoli urinary tract infection Most recently chronic vomiting with bilious vomiting. Controlled with cerenia but once off cerenia vomits.

Abnormal PE/Chem/CBC/UA Results: Recently noted UTI culture pending. Non painful abdomen BW shows mild elevation in Phosphorous and mild decrease in ALT, rest of BW all normal Noted ecoli urinary infection >100,000 as of 5/24. Susceptible to Baytril Recent ecoli infection tx out of state 2/2023

ULTRASONOGRAPHIC EXAMINATION OF THE ABDOMEN**Urinary System**

The urinary bladder is moderately distended with anechoic contents. No masses, inflammatory changes, echogenic sediment or cystoliths are observed. The urinary bladder, trigone and visible pelvic urethra are normal in thickness with a smooth mucosal surface.

The right kidney is normal in size (3.42 cm), shape and echogenicity. It has smooth peripheral margination. There is a normal 1:3 cortex to medulla ratio with appropriate corticomedullary distinction. There is no evidence of pyelectasia or infarcts observed. Tiny punctate non-obstructive nephroliths noted.

The left kidney is normal in size (3.26 cm), shape and echogenicity. It has smooth peripheral margination. There is a normal 1:3 cortex to medulla ratio with appropriate corticomedullary distinction. There is no evidence of pyelectasia or infarcts observed. Tiny punctate non-obstructive nephroliths noted.

Adrenal Glands

The right adrenal gland is normal in size (0.45 cm at the cranial pole and 0.43 cm at the caudal pole), shape and contour. Corticomedullary structure is unremarkable. Visible surrounding vasculature appears normal.

The left adrenal gland is normal in size (0.32 cm at the cranial pole and 0.32 cm at the caudal pole), shape and contour. Corticomedullary structure is unremarkable. Visible surrounding vasculature appears normal.

Spleen

The spleen is subjectively normal in size with a normal smooth capsular contour. Parenchyma is appropriately finely textured and homogenous with normal echogenicity relative to surrounding tissue (hyperechoic to liver). No focal nodules or masses are observed. Splenic vasculature appears normal.

Liver

The liver is subjectively normal in size with normal smooth curvilinear peripheral contour. Parenchyma is appropriately hypoechoic to the spleen in echogenicity and appropriately mildly coarse and homogenous in echotexture. No focal lesions are observed. Visible vasculature and biliary tree appear normal without distension or congestion.

Gallbladder is moderately distended with anechoic bile as well as suspended and gravity dependent echogenic debris. The wall is smooth without visible thickening. There is no evidence of cystic or CBD dilation. There is no evidence of effusion or inflammation.

**PATIENT**

Sophia Amalio

SPECIES

Canine

BREED

Yorkie

SEX

Spayed Female

AGE

7 Years

WEIGHT

8.6 Pounds

INTERPRETED BYBeth Johnson, DVM
DACVIM**IMAGING PERFORMED BY**

Amy Mayhew, LVT

HOSPITAL NAME

SVS Imaging MI

REFERRING VET

Dr. Totin

INVOICE

43379

DATE

6/22/23

Gastrointestinal

The visible stomach wall is normal in thickness and layering. The lumen of the stomach is mildly distended with very echogenic reverberation artifact from intraluminal gas. There is no evidence of obstruction, foreign material or infiltrative disease; however, complete visualization of far wall is partially inhibited by gas. Pyloric outflow tract appears patent.

The visible small intestines are normal in wall thickness and layering. Hyperechoic mucosal fogging or speckling is noted. Small intestinal motility appears adequate (1-3 contractions per min). The lumen is empty with no evidence of obstruction or foreign material.

The visible colon is normal in wall thickness (< 0.2 cm) and layering. Contents are consistent with normal formed feces and gas.

Pancreas

The pancreatic parenchyma is appropriately isoechoic to surrounding tissue. Visible capsule is smooth and normal in contour. There is no visible pancreatic duct dilation. There is no evidence of active peripancreatic inflammation.

Free Abdomen

Very trace anechoic free fluid noted in the caudal abdomen adjacent to the urinary bladder.

The mesenteric lymph nodes are prominent in size with swollen capsular contour. Normal elongated shape (length to width ratio) is maintained. There is no loss of parenchymal detail.

ULTRASONOGRAPHIC FINDINGS

- **Subtle/mild mucosal speckling** – Mucosal speckling is often present with inflammatory bowel disease (IBD). It is not specific for type or severity of disease. Mild speckling change can occur as a normal patient variant in the post-prandial state.
- **Mild gallbladder debris** - Cholecystic debris is of unknown clinical significance. It can be seen with biliary stasis from fasting or illness. Cholecystic debris is not necessarily related to hepatobiliary disease. Echogenic bile is most commonly an incidental finding in dogs and should be interpreted in combination with clinical signs such as nausea, inappetence, cranial abdominal discomfort and/or laboratory changes such as increased ALP and/or increased Tbili.
- **Reactive mesenteric lymph nodes** – infiltrative neoplastic disease cannot be ruled out but is considered less likely.
- Punctate non-obstructive nephrolithiasis bilaterally

INTERPRETATION OF THE FINDINGS & FURTHER RECOMMENDATIONS

Given the subtle mucosal speckling, further diagnostic recommendations for this patient's vomiting workup include:

A gastrointestinal malabsorption panel (including cobalamin, folate, TLI and PLI) to Texas A&M GI Laboratory is recommended for further evaluation of GI and pancreatic function.

A baseline cortisol is recommended. If baseline cortisol is less than 2, a full ACTH stimulation test is recommended to rule out hypoadrenocorticism.

In the meantime, in addition to supportive/symptomatic care with antiemetics, gastroprotectants, etc., empirical deworming with a 5-day course of Panacur is recommended as well as, if tolerated, transition in diet based on trial and error response. Trials could include a bland easy to digest or low-fat diet, or

IMAGING PERFORMED BY

SVS Mobile Imaging MI 734-637-7711
svsimagingmi@gmail.com



EDUCATIONAL TELECONSULTATION SERVICES™
1-800-838-4268 info@sonopath.com SonoPath.com

PATIENT

Sophia Amalio

potentially a hydrolyzed protein diet, and some patients respond better to one brand or version of hydrolyzed protein diet better than another, so sometimes several trials of the same type of diet are indicated.

SPECIES

Canine

There is not an ultrasonographically visible structural or pathologic change noted to explain this patient's urinary tract infections. Recommendations include treating it as a persistent urinary tract infection, meaning a longer-term course of treatment if not already done (i.e., 4-6 weeks based on culture and sensitivity results), and this plan should include a follow up culture a week to 10 days after starting antibiotics to ensure no secondary organisms etc., and be completed with a final culture a week to 10 days after finishing antibiotic to ensure the infection has fully cleared. If at that time infections return, then recurrent urinary tract infections are suspected, and given this patient's history, could potentially be secondary to the vaginitis or a perivaginal pyoderma, etc., in which case addressing the pruritis, itching, pyoderma, etc. in the area could help prevent urinary tract infections. This could be attempted potentially with a hydrolyzed food trial, or potentially anti-yeast antibacterial wiping of the area.

BREED

Yorkie

SEX

Spayed Female

AGE

7 Years

WEIGHT

8.6 Pounds

INTERPRETED BY

Beth Johnson, DVM
DACVIM

IMAGING PERFORMED BY

Amy Mayhew, LVT

HOSPITAL NAME

SVS Imaging MI

REFERRING VET

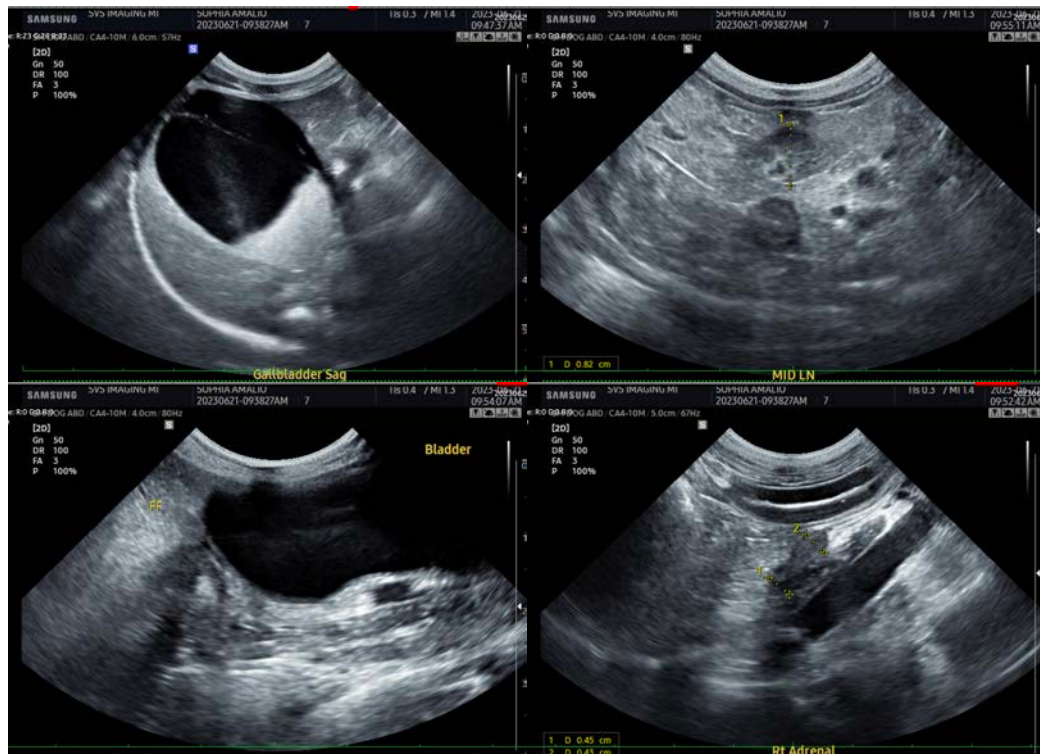
Dr. Totin

INVOICE

43379

DATE

6/22/23



IMAGING PERFORMED BY

SVS Mobile Imaging MI 734-637-7711
svsimagingmi@gmail.com



PATIENT

Sophia Amalio

SPECIES

Canine

BREED

Yorkie

SEX

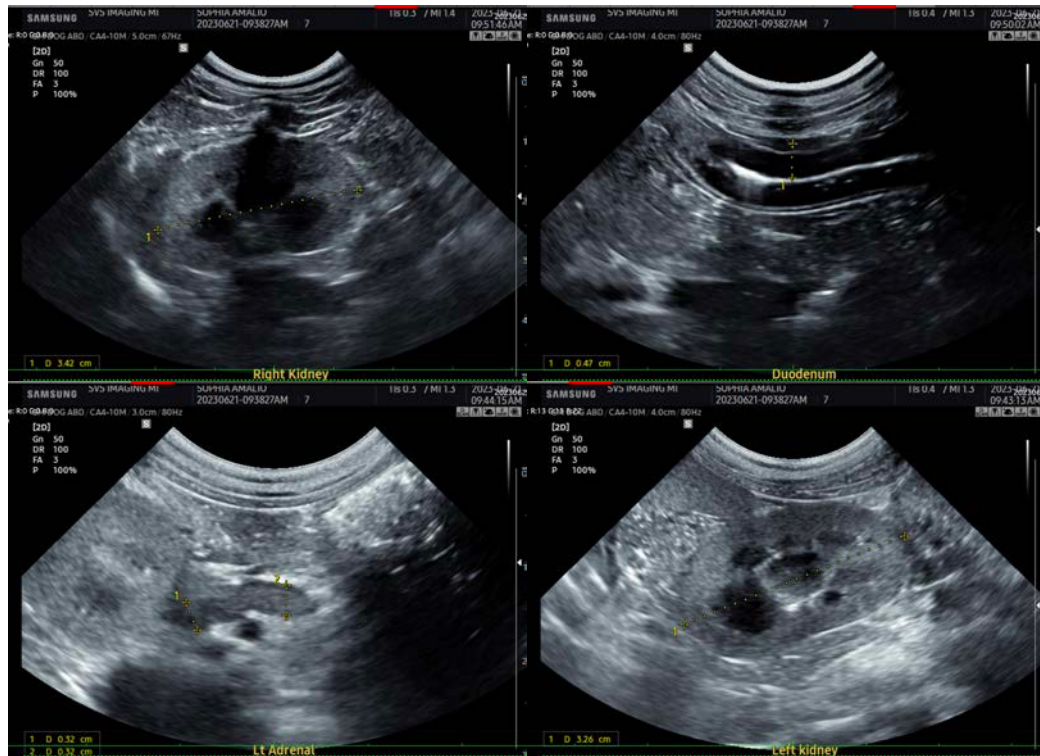
Spayed Female

AGE

7 Years

WEIGHT

8.6 Pounds



INTERPRETED BY

Beth Johnson, DVM
DACVIM

IMAGING PERFORMED BY

Amy Mayhew, LVT

HOSPITAL NAME

SVS Imaging MI

REFERRING VET

Dr. Totin

INVOICE

43379

DATE

6/22/23

The information and recommendations provided are based on the images presented by the referring veterinarian/sonographer. No evaluation can be communicated regarding pathology that was not visible in the image/video clips provided.

Thank you for this referral. If the clinical or image interpretation does not parallel your findings or if I can be of any further assistance please contact me.

Beth Johnson, DVM, DACVIM
info@sonopath.com