

**DATE PRESENTING CLINICAL SIGNS**

6/22/23 Doing well overall- hx of grade 2/6 murmur with no signs of heart dysfunction. PE is WNL otherwise.

PATIENT

Shiloh Klimovitz Current Medications: None.
Date of Previous IntraPet Ultrasound: No previous.
Sedation: Not required to complete full diagnostic ultrasound.
Stat Report: Not requested.
Imaging Performed By: Stephanie Warga RDCS, RVT.

SPECIES

Canine

BREED

Beagle

SEX

Spayed Female

AGE

1/8/12

WEIGHT

38 Pounds

INTERPRETED BY

Beth Johnson, DVM
DACVIM

HOSPITAL NAME

Stay Pet Veterinary

REFERRING VET

Dr. Klimovitz

INVOICE

43396

ULTRASONOGRAPHIC EXAMINATION OF THE ABDOMEN**Urinary System**

The urinary bladder is moderately distended with anechoic contents. No masses, inflammatory changes, echogenic sediment or cystoliths are observed. The urinary bladder, trigone and visible pelvic urethra are normal in thickness with a smooth mucosal surface.

Kidneys are overall normal in size and shape with smooth peripheral margination. A normal 1:3 cortex to medulla ratio is maintained. The medulla and cortices are uniform in texture with some mild increased cortical echogenicity and mild loss of corticomedullary distinction, expected in this age patient. There is no evidence of pyelectasia, mineral or infarcts observed. The left kidney measures 6.31 cm. The right kidney measured 6.37 cm.

Adrenal Glands

The right adrenal gland is normal in size (2.5 cm long x 0.66 cm at the cranial pole and 0.71 cm at the caudal pole), shape and contour. Corticomedullary structure is unremarkable. Visible surrounding vasculature appears normal.

The left adrenal gland is normal in size (2.1 cm long x 0.50 cm at the cranial pole and 0.56 cm at the caudal pole), shape and contour. Corticomedullary structure is unremarkable. Visible surrounding vasculature appears normal.

Spleen

Spleen is generally normal in size and shape with a smooth capsular contour. Parenchyma is diffusely nodular in appearance characterized by small discrete hypoechoic nodules. Splenic vasculature appears normal.

Liver

The liver is subjectively normal in size with normal smooth curvilinear peripheral contour. Parenchyma is appropriately hypoechoic to the spleen in echogenicity and appropriately mildly coarse and homogenous in echotexture. No focal lesions are observed. Visible vasculature and biliary tree appear normal without distension or congestion.

The gallbladder is non-distended in size. The wall is smooth without visible thickening. Luminal contents are primarily anechoic. There is no evidence of cystic or common bile duct dilation.

Gastrointestinal

The stomach wall is normal in thickness (canine < 0.5 cm and feline < 0.4 cm) and layering. The lumen of the stomach is empty with no evidence of obstruction, foreign material or infiltrative disease. Pyloric outflow tract appears patent.

The visible small intestines are normal in wall thickness and layering (canine duodenum < 0.5 cm and feline duodenum < 0.4 cm; other < 0.3 cm). Small intestinal motility appears adequate (1-3 contractions per min).

The lumen of the small intestine is empty with no evidence of obstruction, foreign material or infiltrative disease.

The visible colon is normal in wall thickness (< 0.2 cm) and layering. Contents are consistent with normal formed feces and gas.

Pancreas

The pancreatic parenchyma is appropriately isoechoic to surrounding tissue. Visible capsule is smooth and normal in contour. There is no visible pancreatic duct dilation. There is no evidence of active peripancreatic inflammation.

Free Abdomen

There is no evidence of free peritoneal effusion noted in these images.

There is no apparent lymphadenopathy noted in these images.

PRIMARY FINDINGS

- Splenic micronodular hyperplasia pattern – This nodular change is often associated with benign aging nodular hyperplasia. Infiltrative neoplasia, however, including both early hemangiosarcoma as well as round cell neoplasia cannot be ruled out.

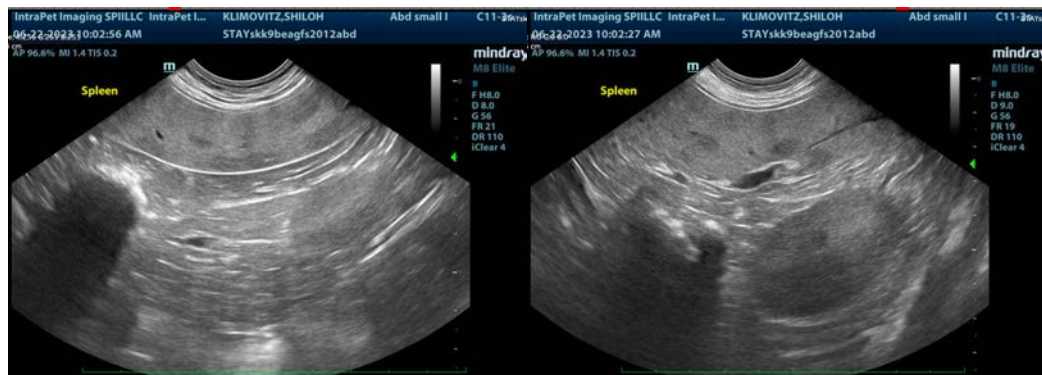
SECONDARY FINDINGS

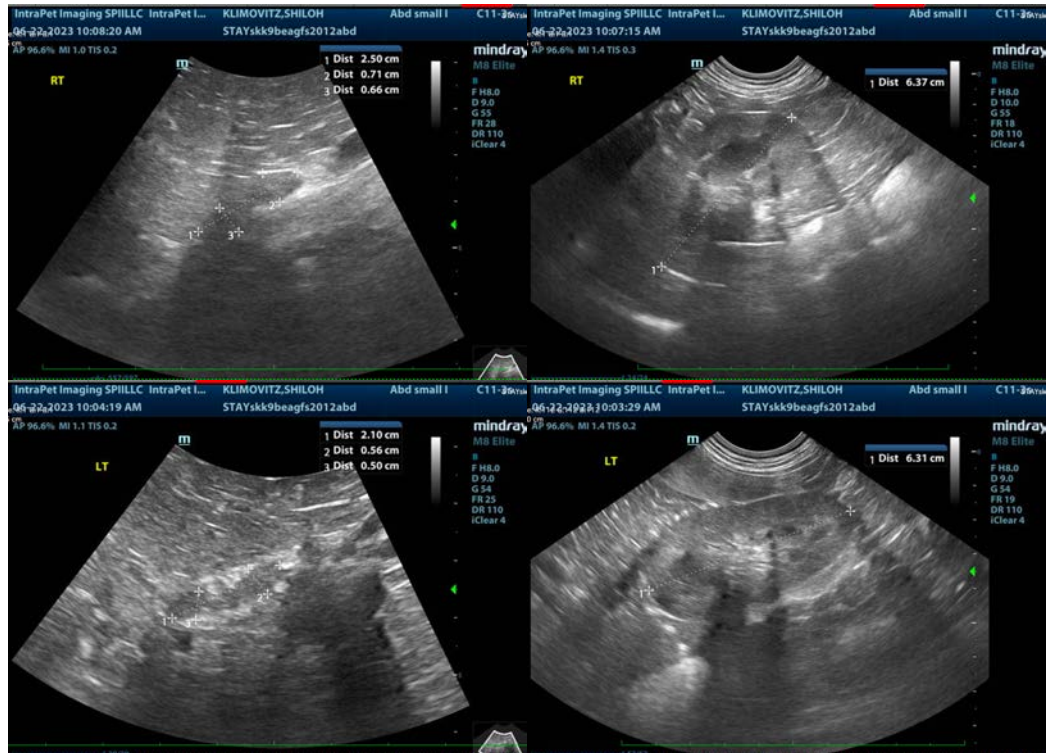
- Age related kidney changes

INTERPRETATION OF THE FINDINGS & FURTHER RECOMMENDATIONS

Given this patient's reported heart murmur and as is reportedly already planned, an echocardiogram is recommended.

While the changes in the spleen trend toward benign in appearance, a fine needle aspirate of the spleen is recommended to rule out infiltrative round cell neoplasia versus other if patient's coagulation status is appropriate.





The information and recommendations provided are based on the images presented by the referring veterinarian/sonographer. No evaluation can be communicated regarding pathology that was not visible in the image/video clips provided.

Thank you for this referral. If the clinical or image interpretation does not parallel your findings or if I can be of any further assistance please contact me.

Beth Johnson, DVM, DACVIM
info@sonopath.com