

**DATE PRESENTING CLINICAL SIGNS**

6/22/22

Vomiting bile, lethargy, decreased appetite for ~ one month. Vomiting initially undigested food, progressed to yellow/brown bile. Weight loss of 0.8lbs in 60 days.

**PATIENT**

Figaro Janney

Current Medications: Cerenia 8mg SID 6/17/22, Mirataz 1 ¼ inch strip SID 6/17/22.

Lab Results: CBC/Chem/T4 WNL.

Date of Previous IntraPet Ultrasound: No previous.

Sedation: Not required to complete full diagnostic ultrasound.

Stat Report: Not requested.

**SPECIES**

Feline

**ULTRASONOGRAPHIC EXAMINATION OF THE ABDOMEN****BREED**

DSH

**Urinary System**

Urinary bladder is moderately distended. It has a normal uniform wall thickness (<0.2 cm). Contents include primarily anechoic fluid combined with suspended echogenic non-shadowing debris within the fluid. No masses or cystoliths are observed. The trigone and visible pelvic urethra are normal in thickness with a smooth mucosal surface.

**SEX**

Neutered Male

The right kidney is normal in size (3.5 cm), shape and echogenicity. It has smooth peripheral margination. There is a normal 1:3 cortex to medulla ratio with appropriate corticomedullary distinction. There is no evidence of pyelectasia, mineral or infarcts observed.

**AGE**

5/1/13

The left kidney is normal in size (3.35 cm), shape and echogenicity. It has smooth peripheral margination. There is a normal 1:3 cortex to medulla ratio with appropriate corticomedullary distinction. There is no evidence of pyelectasia or infarcts observed. Non-obstructive areas of mineralization/nephroliths are noted, primarily in the diverticular of the kidney.

**WEIGHT**

8.7 Pounds

**INTERPRETED BY**Beth Johnson, DVM  
DACVIM**Adrenal Glands**

The adrenal glands are bilaterally uniformly plump egg-shaped adrenals (left is 0.43, right is 0.68 cm), hypoechoic in echogenicity. This is most likely a benign age-related change. This change can be caused by chronic stress/disease, so investigation for/management of other disease (chronic kidney disease, hyperthyroidism, etc.) is recommended.

**IMAGING PERFORMED BY**

Rachel Brilhart RDMS

**Spleen**

The spleen is subjectively normal in size with a normal smooth capsular contour. Parenchyma is appropriately finely textured and homogenous with normal echogenicity relative to surrounding tissue (hyperechoic to liver). No focal nodules or masses are observed. Splenic vasculature appears normal.

**HOSPITAL NAME**

Paradise AH

**Liver**

The liver is subjectively normal in size with normal smooth curvilinear peripheral contour. Parenchyma is appropriately hypoechoic to the spleen in echogenicity and appropriately mildly coarse and homogenous in echotexture. No focal lesions are observed. Visible vasculature and biliary tree appear normal without distension or congestion.

**REFERRING VET**

Dr. Pound

**INVOICE**

38994

The gallbladder is moderately distended with anechoic bile as well as suspended and gravity dependent echogenic debris. The wall is smooth without visible thickening. There is no evidence of cystic or CBD dilation. There is no evidence of effusion or inflammation.

**Gastrointestinal**

The stomach wall is normal in thickness (canine < 0.5 cm and feline < 0.4 cm) and layering. The lumen of the stomach is empty with no evidence of obstruction, foreign material or infiltrative disease. Pyloric outflow tract appears patent.

The visible small intestine demonstrates areas of thick muscularis layer relative to mucosa (disruption of the normal 1:3 muscularis:mucosa ratio). Small intestinal submucosa is slightly irregular, thick and hyperechoic, without evident loss of layering appreciated. The lumen is empty without evidence of obstruction or foreign material.

The visible colon is normal in wall thickness (< 0.2 cm) and layering. Contents are consistent with normal formed feces and gas.

### ***Pancreas***

The pancreatic parenchyma is appropriately isoechoic to surrounding tissue. Visible capsule is smooth and normal in contour. There is no visible pancreatic duct dilation. There is no evidence of active peripancreatic inflammation.

### ***Free Abdomen***

There is no evidence of peritoneal effusion.

Mesenteric lymph nodes are prominent in size with swollen capsular contour. Normal elongated shape (length to width ratio) is maintained. There is no loss of parenchymal detail.

## **PRIMARY FINDINGS**

- Inflammatory bowel disease (IBD) pattern - This finding has been reported with infiltrative bowel disease including both benign inflammatory disease as well as infiltrative neoplasia such as lymphoma.
- Reactive mesenteric lymph nodes – infiltrative neoplastic disease cannot be ruled out but is considered less likely.

## **SECONDARY FINDINGS**

- Gallbladder debris - Cholecystic debris is of unknown clinical significance. It can be seen with biliary stasis from fasting or illness, however, it can also be associated with hepatobiliary disease in cats and should be interpreted in combination with clinical signs such as nausea, inappetence, cranial abdominal discomfort and/or laboratory changes such as increased ALP and/or increased Tbili.
- Non-obstructive nephrolith in the left kidney
- Age related adrenomegaly
- Urinary bladder debris

## **INTERPRETATION OF THE FINDINGS & FURTHER RECOMMENDATIONS**

A gastrointestinal malabsorption panel (including cobalamin, folate, TLI and PLI) to Texas A&M GI Laboratory is recommended for further evaluation of GI and pancreatic function.

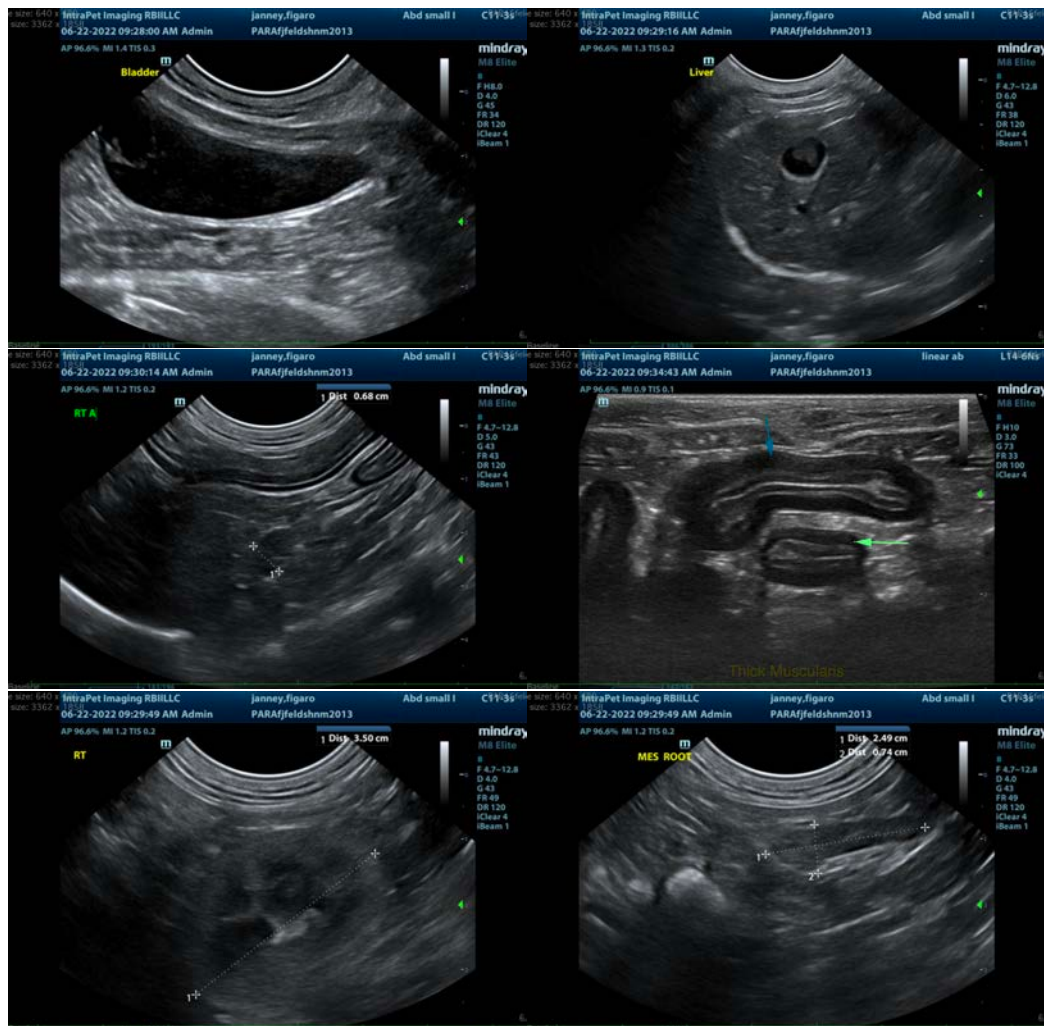
Ideally, biopsies of the GI tract, being sure to include ileum if possible, are recommended to definitively diagnose and therefore manage the infiltrative bowel disease.

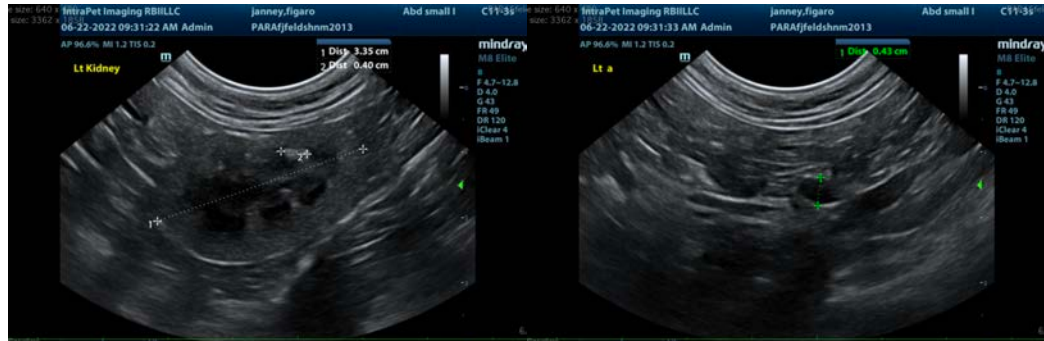
If biopsies cannot be obtained, empirical therapies could include diet change, empirical deworming with a 5 day course of Panacur, cobalamin supplementation (unless cobalamin level is evaluated and supplementation is not warranted) and prednisolone (if not contraindicated based on patient contraindications, co-

morbidities, etc.). Other supportive therapeutic considerations could include fiber supplementation, especially with large bowel diarrhea and/or a probiotic.

Urinalysis and, if indicated based on urinalysis results, urine culture are recommended. If protein is present in an otherwise quiet sediment, protein quantification with a urine protein to creatinine ration is recommended.

A fine needle aspirate of the enlarged mesenteric lymph nodes could be considered if the patient's coagulation status is appropriate, as a less invasive way to rule out round cell neoplasia such as lymphoma, prior to pursuing biopsies.





The information and recommendations provided are based on the images presented by the referring veterinarian/sonographer. No evaluation can be communicated regarding pathology that was not visible in the image/video clips provided.

Thank you for this referral. If the clinical or image interpretation does not parallel your findings or if I can be of any further assistance please contact me.

**Beth Johnson, DVM, DACVIM**  
Beth.Johnson@sonopath.com