

**DATE PRESENTING CLINICAL SIGNS**

6/22/22

Recurrent UTI- had UTI signs last month that responded well to Clavacillin. Recheck urine after ab's WNL. 4 days ago UTI and bloody urine started again. Eating and drinking normally.

PATIENT

Diana Morrish

Current Medications: None.
Date of Previous IntraPet Ultrasound: No previous.
Sedation: Not required to complete full diagnostic ultrasound.
Stat Report: Not requested.

SPECIES

Canine

ULTRASONOGRAPHIC EXAMINATION OF THE ABDOMEN**BREED**

Golden Retriever

Urinary System

The urinary bladder is mildly distended. It could be further distended for a more thorough evaluation, but the distention was adequate with primarily anechoic contents, to appreciate diffuse apical urinary bladder wall thickening measuring approximately 1.0 cm with a diffusely irregular hyperechoic mucosa. Along the mid dorsal wall, there is a 1.5 cm wide x 1.0 cm extension into the lumen, echogenic, irregular, mixed structure, concerning for a mass. No cystoliths are observed. The trigone and visible pelvic urethra are normal in thickness with a smooth mucosal surface.

SEX

Spayed Female

AGE

1/1/10

The right kidney is normal in size (6.63 cm), shape and echogenicity. It has smooth peripheral margination. There is a normal 1:3 cortex to medulla ratio with appropriate corticomedullary distinction. There is no evidence of pyelectasia, mineral or infarcts observed.

WEIGHT

64.5 Pounds

The left kidney is normal in size (7.26 cm), shape and echogenicity. It has smooth peripheral margination. There is a normal 1:3 cortex to medulla ratio with appropriate corticomedullary distinction. There is no evidence of pyelectasia or mineral observed. Several chronic infarcts present.

INTERPRETED BYBeth Johnson, DVM
DACVIM**Adrenal Glands**

The right adrenal gland is normal in size (3.16 cm long x 0.87 cm at the cranial pole and 0.90 cm at the caudal pole), shape and contour. Corticomedullary structure is unremarkable. Visible surrounding vasculature appears normal.

IMAGING PERFORMED BY

Rachel Brilhart RDMS

The left adrenal gland is normal in size (2.91 cm long x 0.58 cm at the cranial pole and 0.74 cm at the caudal pole), shape and contour. Corticomedullary structure is unremarkable. Visible surrounding vasculature appears normal.

HOSPITAL NAME

Pet Vet of Clarksville

Spleen

Spleen is subjectively normal in size with a normal smooth capsular contour. Parenchyma is appropriately finely textured and homogenous with normal echogenicity relative to surrounding tissue (hyperechoic to liver). Multifocal well-demarcated hyperechoic homogenous nodules are present. Splenic vasculature appears normal.

REFERRING VET

Dr. Martof

Liver

Liver is subjectively enlarged. Margins are smooth but round. It has a normal homogenous echotexture. Parenchyma is diffusely hyperechoic characterized by less prominent than normal portal vein walls and increased echogenicity relative to the spleen. No focal lesions are observed. Visible vasculature and biliary tree appear normal without distension or congestion.

INVOICE

38990

The gallbladder is moderately distended with anechoic bile as well as suspended and gravity dependent echogenic debris. The wall is smooth without visible thickening. There is no evidence of cystic or CBD dilation. There is no evidence of effusion or inflammation.

Gastrointestinal

The stomach wall is normal in thickness (canine < 0.5 cm and feline < 0.4 cm) and layering. The lumen of the stomach is mildly distended with very echogenic reverberation artifact from intraluminal gas. There is no evidence of obstruction, foreign material or infiltrative disease; however, complete visualization of far wall is partially inhibited by gas. Pyloric outflow tract appears patent.

The visible small intestines are normal in wall thickness and layering (canine duodenum < 0.5 cm and feline duodenum < 0.4 cm; other < 0.3 cm). Small intestinal motility appears adequate (1-3 contractions per min). The lumen of the small intestine is empty with no evidence of obstruction, foreign material or infiltrative disease.

The visible colon is normal in wall thickness (< 0.2 cm) and layering. Contents are consistent with normal formed feces and gas.

Pancreas

The pancreatic parenchyma is appropriately isoechoic to surrounding tissue. Visible capsule is smooth and normal in contour. There is no visible pancreatic duct dilation. There is no evidence of active peripancreatic inflammation.

Free Abdomen

There is no evidence of peritoneal effusion. There is no apparent lymphadenopathy.

PRIMARY FINDINGS

- Chronic cystitis with a focal mucosal irregular – concerning for infiltrative neoplasia. A benign polyp or benign inflammatory tissue with accumulated mucus or blood clot can't be ruled out, but is considered less likely.

SECONDARY FINDINGS

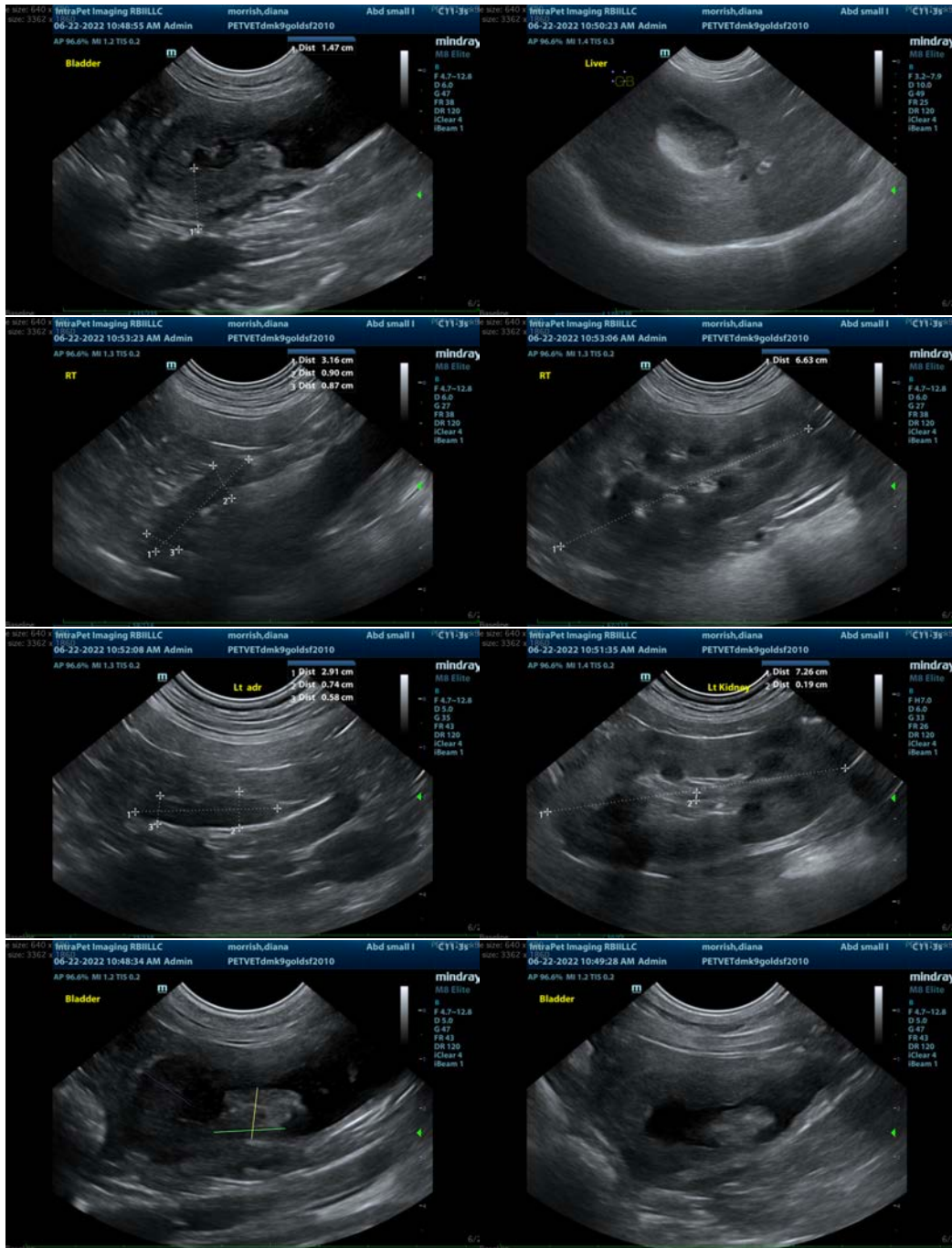
- Hyperechoic splenic nodules – most consistent with benign myelolipomas. Other differentials such as fibrosis or calcification caused by old hematomas or infarcts, chronic inflammation, granulomatous disease or metastatic disease cannot be ruled out, but are less likely.
- Hyperechoic hepatomegaly – most consistent with benign steroid (endocrine) hepatopathy or reactive or idiopathic hepatopathy. Infiltrative neoplasia such as round cell neoplasia is also possible, but considered less likely.
- Gallbladder debris - Cholecystic debris is of unknown clinical significance. It can be seen with biliary stasis from fasting or illness. Cholecystic debris is not necessarily related to hepatobiliary disease. Echogenic bile is most commonly an incidental finding in dogs and should be interpreted in combination with clinical signs such as nausea, inappetence, cranial abdominal discomfort and/or laboratory changes such as increased ALP and/or increased Tbili.
- Chronic renal cortical cysts in the left kidney.

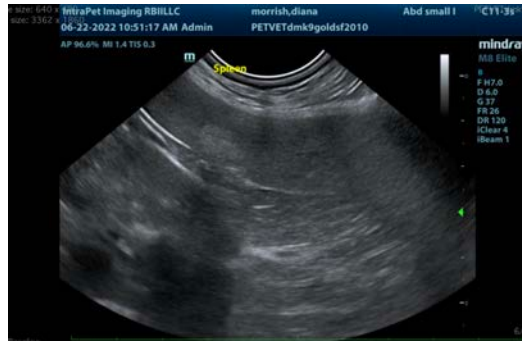INTERPRETATION OF THE FINDINGS & FURTHER RECOMMENDATIONS

- Three view thoracic radiographs are recommended for further assessment of cardio-pulmonary status as well as to further evaluate for any evidence of metastatic disease, if not recently evaluated.
- Urinalysis and urine culture, if indicated based on urinalysis results, are recommended. Submission of urine to look for BRAF gene mutation, which is associated with urinary bladder cancer, could be

considered. Other diagnostic options include traumatic catheterization, fine needle aspirate (with small risk of tumor seeding/trailing) or cystoscopy for further sampling.

- In the meantime, empirical therapy could include broad-spectrum antibiotics to address suspected bacterial shedding from deep within the mass, causing the recurrent urinary tract infections as well as an anti-inflammatory for comfort.





The information and recommendations provided are based on the images presented by the referring veterinarian/sonographer. No evaluation can be communicated regarding pathology that was not visible in the image/video clips provided.

Thank you for this referral. If the clinical or image interpretation does not parallel your findings or if I can be of any further assistance please contact me.

Beth Johnson, DVM, DACVIM
Beth.Johnson@sonopath.com