



PATIENT

Jack Kegley

SPECIES

Canine

BREED

English Setter

SEX

Neutered Male

AGE

9 Years 10 Months

WEIGHT

34.2 Pounds

INTERPRETED BY

Beth Johnson, DVM
DACVIM

IMAGING PERFORMED BY

A Murphy, CVT

HOSPITAL NAME

Wauwatosa VC

REFERRING VET

Dr. Jamie Oakes

INVOICE

38946

DATE

6/21/22

PRESENTING CLINICAL SIGNS

Jack has a history of vomiting and diarrhea. On June 16 he presented for lethargy and diarrhea. Blood work showed significant decrease on all proteins. Concern for PLE. Imaging to assess for underlying cause.

ULTRASONOGRAPHIC EXAMINATION OF THE ABDOMEN

Urinary System

Urinary bladder is mildly to moderately distended with anechoic contents. Apical urinary bladder wall is diffusely thick (0.64 cm). Mucosa is hyperechoic and irregular. No masses or cystoliths are observed. The trigone and visible pelvic urethra are normal thickness with a smooth mucosal surface.

Prostate (neutered) is normal in size, echotexture and echogenicity for a neutered male.

The right kidney is normal in size (5.0 cm) and shape with smooth peripheral margination. A normal 1:3 cortex to medulla ratio is maintained. The medulla and cortices are uniform in texture with some mild increased echogenicity and mild loss of corticomedullary distinction. There is no evidence of pyelectasia, mineral or infarcts observed.

The left kidney is normal in size (5.36 cm) and shape with smooth peripheral margination. A normal 1:3 cortex to medulla ratio is maintained. The medulla and cortices are uniform in texture with some mild increased echogenicity and mild loss of corticomedullary distinction. There is no evidence of pyelectasia, mineral or infarcts observed.

Adrenal Glands

The right adrenal gland is normal in size (0.90 cm at the cranial pole and 0.56 cm at the caudal pole), shape and contour. Corticomedullary structure is unremarkable. Visible surrounding vasculature appears normal.

The left adrenal gland is normal in size (0.48 cm at the cranial pole and 0.49 cm at the caudal pole), shape and contour. Corticomedullary structure is unremarkable. Visible surrounding vasculature appears normal.

Spleen

The spleen is subjectively normal in size with a normal smooth capsular contour. Parenchyma is appropriately finely textured and homogenous with normal echogenicity relative to surrounding tissue (hyperechoic to liver). No focal nodules or masses are observed. Splenic vasculature appears normal.

Liver

The liver is subjectively normal in size with normal smooth curvilinear peripheral contour. Parenchyma is appropriately hypoechoic to the spleen in echogenicity and appropriately mildly coarse and homogenous in echotexture. No focal lesions are observed. Visible vasculature and biliary tree appear normal without distension or congestion.

The gallbladder is moderately distended with anechoic bile as well as suspended and gravity dependent echogenic debris. The wall is smooth without visible thickening. There is no evidence of cystic or CBD dilation. There is no evidence of effusion or inflammation.

Gastrointestinal



PATIENT

Jack Kegley

The stomach wall is normal in thickness (canine < 0.5 cm and feline < 0.4 cm) and layering. The lumen of the stomach is empty with no evidence of obstruction, foreign material or infiltrative disease. Pyloric outflow tract appears patent.

SPECIES

Canine

The small intestine is diffusely mildly thick with a relatively thick mucosa compared to other layers. Normal wall layering is preserved; however, the mucosa is more echogenic than normal and contains hyperechoic striations perpendicular to the lumen. The lumen of the small intestine is empty with no evidence of obstruction, foreign material or infiltrative disease.

BREED

English Setter

The visible colon is normal in wall thickness (< 0.2 cm) and layering. Contents are consistent with normal formed feces and gas.

Pancreas

SEX

Neutered Male

The pancreatic parenchyma is appropriately isoechoic to surrounding tissue. Visible capsule is smooth and normal in contour. There is no visible pancreatic duct dilation. There is no evidence of active peripancreatic inflammation.

Free Abdomen

AGE

9 Years 10 Months

There is no evidence of peritoneal effusion. There is no apparent lymphadenopathy.

PRIMARY FINDINGS

WEIGHT

34.2 Pounds

- Lymphangiectasia - Small bowel findings are most consistent with lacteal dilation. These findings can be observed with protein-losing enteropathies caused by either primary lymphangiectasia or primary infiltrative inflammatory disease with secondary lymphangiectasia. Infiltrative neoplasia is possible but considered less likely. Histopathology is necessary to definitively determine underlying cause.

INTERPRETED BY

Beth Johnson, DVM
DACVIM

SECONDARY FINDINGS

IMAGING PERFORMED BY

A Murphy, CVT

- Chronic Cystitis – Urinary bladder wall changes are most consistent with chronic cystitis. Infiltrative neoplasia cannot be ruled out but is considered less likely give the location and diffuse nature of the changes.
- Age related kidney change – This finding is expected/consistent with age-related mild degenerative disease and should be interpreted clinically in combination with laboratory changes.
- Gallbladder debris - Cholecystic debris is of unknown clinical significance. It can be seen with biliary stasis from fasting or illness. Cholecystic debris is not necessarily related to hepatobiliary disease. Echogenic bile is most commonly an incidental finding in dogs and should be interpreted in combination with clinical signs such as nausea, inappetence, cranial abdominal discomfort and/or laboratory changes such as increased ALP and/or increased Tbili.

HOSPITAL NAME

Wauwatosa VC

REFERRING VET

Dr. Jamie Oakes

INTERPRETATION OF THE FINDINGS & FURTHER RECOMMENDATIONS

INVOICE

38946

- Urinalysis and, if indicated based on urinalysis results, urine culture are recommended. If protein is present in an otherwise quiet sediment, protein quantification with a urine protein to creatinine ration is recommended.
- A gastrointestinal malabsorption panel (including cobalamin, folate, TLI and PLI) to Texas A&M GI Laboratory is recommended for further evaluation of GI and pancreatic function.

DATE

6/21/22



PATIENT

Jack Kegley

- Ideally, biopsies of the GI tract are recommended to definitively diagnose and therefore manage the infiltrative bowel process.

SPECIES

Canine

- If biopsies cannot be obtained safely due to low albumin or patient stability, etc., empirical therapies could include diet change to an ultra-low fat diet, empirical deworming with a 5 day course of Panacur, cobalamin supplementation (unless cobalamin level is evaluated and supplementation is not warranted) a probiotic and prednisolone (if not contraindicated based on patient contraindications, co-morbidities, etc.). Calcium monitoring, and supplementation if necessary, is also recommended.

BREED

English Setter

SEX

Neutered Male

AGE

9 Years 10 Months

WEIGHT

34.2 Pounds

INTERPRETED BY

Beth Johnson, DVM
DACVIM

IMAGING PERFORMED BY

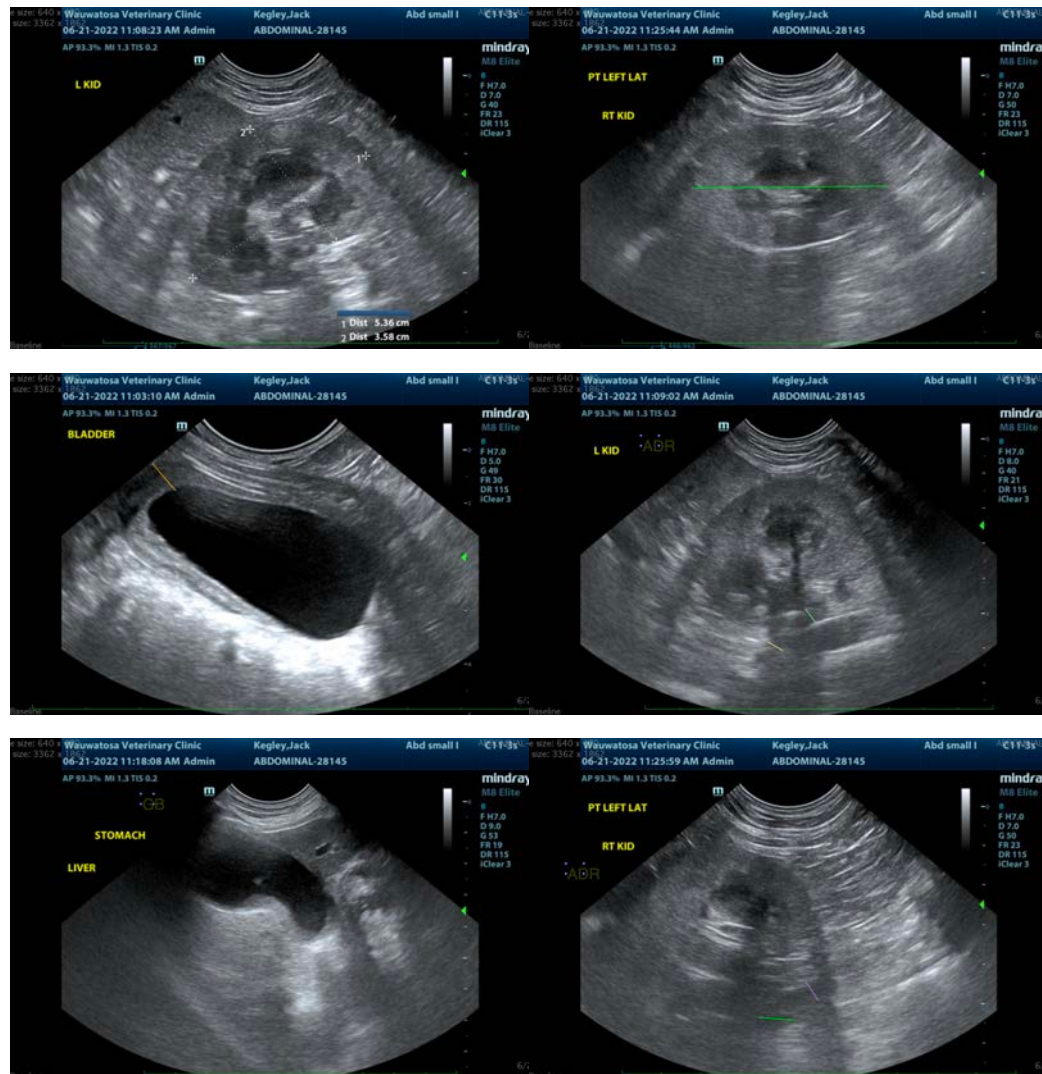
A Murphy, CVT

HOSPITAL NAME

Wauwatosa VC

REFERRING VET

Dr. Jamie Oakes



INVOICE

38946

DATE

6/21/22



PATIENT

Jack Kegley

SPECIES

Canine

BREED

English Setter

SEX

Neutered Male

AGE

9 Years 10 Months

WEIGHT

34.2 Pounds

INTERPRETED BY

Beth Johnson, DVM
DACVIM

IMAGING PERFORMED BY

A Murphy, CVT

HOSPITAL NAME

Wauwatosa VC

REFERRING VET

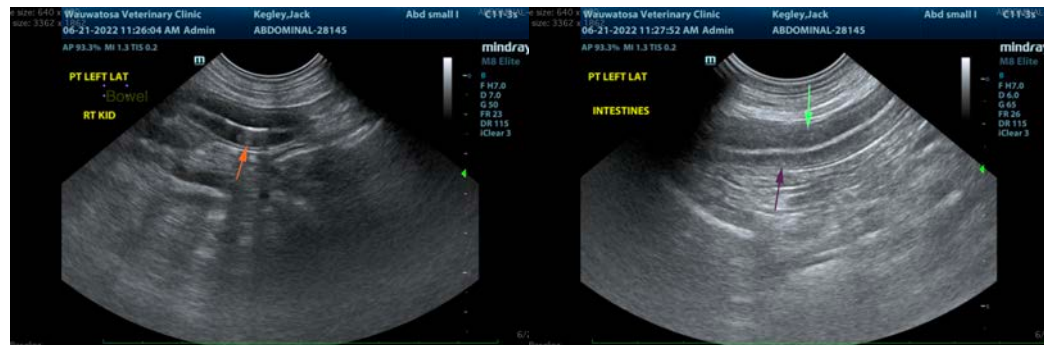
Dr. Jamie Oakes

INVOICE

38946

DATE

6/21/22



The information and recommendations provided are based on the images presented by the referring veterinarian/sonographer. No evaluation can be communicated regarding pathology that was not visible in the image/video clips provided.

Thank you for this referral. If the clinical or image interpretation does not parallel your findings or if I can be of any further assistance please contact me.

Beth Johnson, DVM, DACVIM
Beth.Johnson@sonopath.com