

**DATE PRESENTING CLINICAL SIGNS**

6/21/22 Gastroenteritis, projectile vomiting since last night.

PATIENT Current Medications: Buscopan last night, IV fluid therapy, Famotidine this am.
Lab Results: Hemoconcentration, neutrophilia.

Camo Kelly Radiographs: Decreased detail in the cranial abdomen.
Date of Previous IntraPet Ultrasound: No previous.

SPECIES Sedation: Dex/Torb IV.
Stat Report: Declined.

Canine

ULTRASONOGRAPHIC EXAMINATION OF THE ABDOMEN**BREED** *Urinary System*

Boxer

The urinary bladder is moderately distended with anechoic contents. No masses, inflammatory changes, echogenic sediment or cystoliths are observed. The urinary bladder, trigone and visible pelvic urethra are normal in thickness with a smooth mucosal surface.

SEX

Spayed Female

The right kidney is normal in size (5.69 cm), shape and echogenicity. It has smooth peripheral margination. There is a normal 1:3 cortex to medulla ratio with appropriate corticomedullary distinction. There is no evidence of pyelectasia, mineral or infarcts observed.

AGE

1/27/10

The left kidney is normal in size (6.67 cm), shape and echogenicity. It has smooth peripheral margination. There is a normal 1:3 cortex to medulla ratio with appropriate corticomedullary distinction. There is no evidence of pyelectasia, mineral or infarcts observed.

WEIGHT

60.2 Pounds

Adrenal Glands**INTERPRETED BY**

Beth Johnson, DVM
DACVIM

The right adrenal gland is normal in size (3.3 cm long x 0.73 cm at the cranial pole and 0.60 cm at the caudal pole), shape and contour. Corticomedullary structure is unremarkable. Visible surrounding vasculature appears normal.

The left adrenal gland is normal in size (2.78 cm long x 0.78 cm at the cranial pole and 0.79 cm at the caudal pole), shape and contour. Corticomedullary structure is unremarkable. Visible surrounding vasculature appears normal.

IMAGING PERFORMED BY

Stephanie Pearce
RDCCS, RVT

Spleen

Spleen is subjectively normal in size with a normal smooth capsular contour. Parenchyma is appropriately finely textured and homogenous with normal echogenicity relative to surrounding tissue (hyperechoic to liver). Multifocal well-demarcated hyperechoic homogenous nodules are present. Splenic vasculature appears normal.

HOSPITAL NAME

Bel Air VH

Liver

The liver is subjectively normal in size with normal smooth curvilinear peripheral contour. Parenchyma is appropriately hypoechoic to the spleen in echogenicity and appropriately mildly coarse and homogenous in echotexture. A small, almost 1.0 cm anechoic cyst is present. Visible vasculature and biliary tree appear normal without distension or congestion.

REFERRING VET

Dr. Kelly

INVOICE

38929

GB is moderately distended with anechoic bile and gravity dependent echogenic sediment. The wall is smooth without visible thickening. There is no evidence of cystic or CBD dilation. There is no evidence of effusion or inflammation.

Gastrointestinal

The visible stomach wall appears normal in thickness with normal layering. The stomach is mildly fluid distended with the presence of an echogenic structure with strong acoustic shadowing that appears to be anchored in the pylorus and extending into the small bowel, which is also normal in thickness with normal layering, but is plicated and contains an echogenic linear structure consistent with a linear foreign body leading to an intussusception.

The visible colon is normal in wall thickness (< 0.2 cm) and layering. Contents are consistent with normal formed feces and gas.

Pancreas

The pancreatic parenchyma is appropriately isoechoic to surrounding tissue. Visible capsule is smooth and normal in contour. There is no visible pancreatic duct dilation. There is no evidence of active peripancreatic inflammation.

Free Abdomen

There is no evidence of peritoneal effusion. There is no apparent lymphadenopathy.

There is no pericardial effusion noted in these images.

PRIMARY FINDINGS

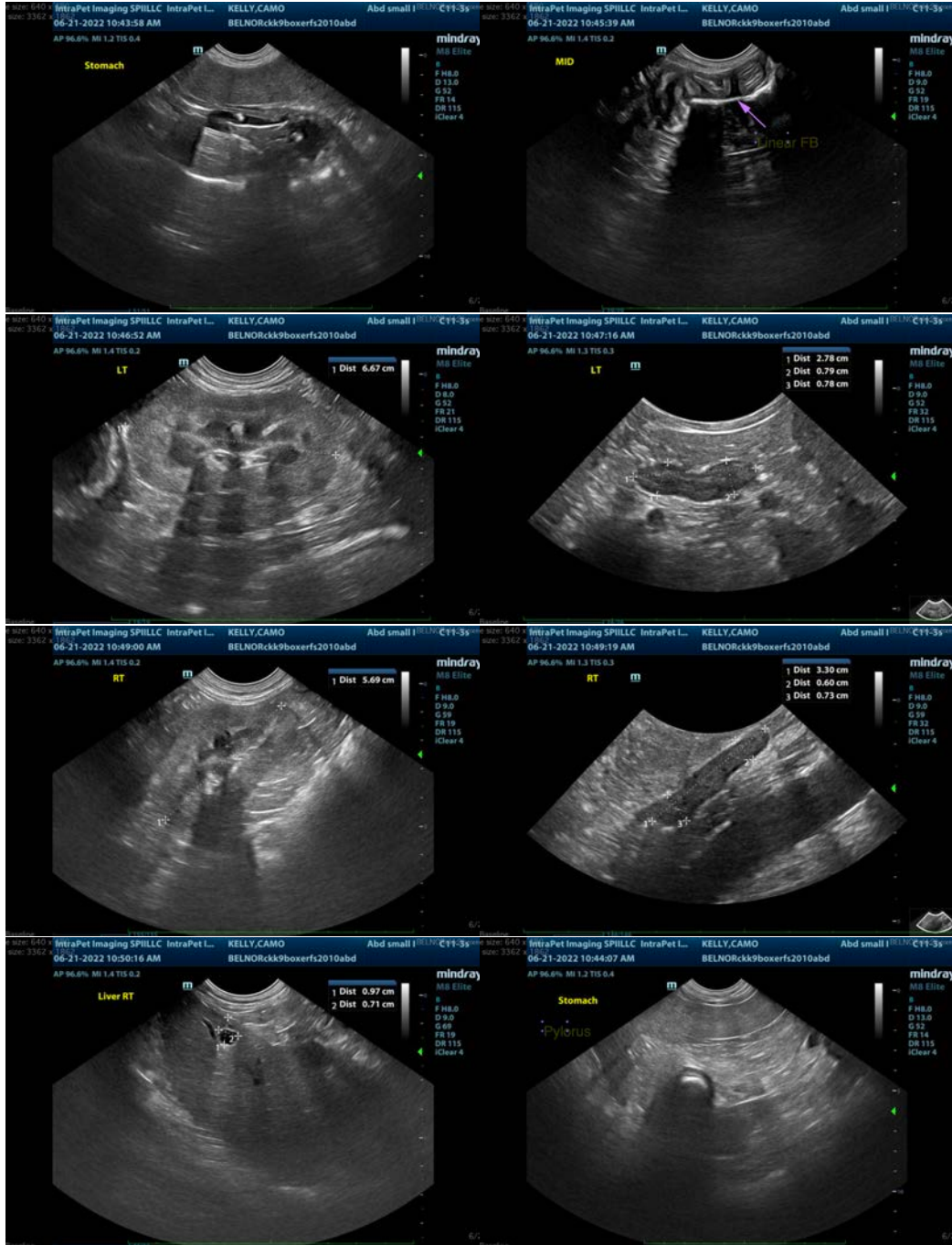
- Linear small bowel foreign body that appears to be anchored in the pylorus and appears to be causing an intussusception.

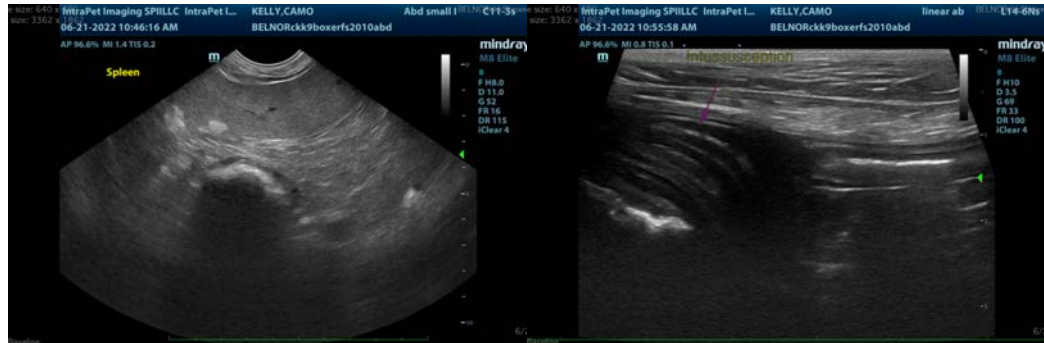SECONDARY FINDINGS

- Hyperechoic splenic nodules – most consistent with benign myelolipomas. Other differentials such as fibrosis or calcification caused by old hematomas or infarcts, chronic inflammation, granulomatous disease or metastatic disease cannot be ruled out, but are less likely.
- Gallbladder debris - Cholecystic debris is of unknown clinical significance. It can be seen with biliary stasis from fasting or illness. Cholecystic debris is not necessarily related to hepatobiliary disease. Echogenic bile is most commonly an incidental finding in dogs and should be interpreted in combination with clinical signs such as nausea, inappetence, cranial abdominal discomfort and/or laboratory changes such as increased ALP and/or increased Tbili.
- Incidental small benign liver cyst

INTERPRETATION OF THE FINDINGS & FURTHER RECOMMENDATIONS

- Three view thoracic radiographs are recommended for further assessment of cardio-pulmonary status as well as to further evaluate for any evidence of metastatic disease, if not recently evaluated.
- An exploratory laparotomy for foreign body removal as well as biopsy of any visibly or palpably abnormal bowel.





The information and recommendations provided are based on the images presented by the referring veterinarian/sonographer. No evaluation can be communicated regarding pathology that was not visible in the image/video clips provided.

Thank you for this referral. If the clinical or image interpretation does not parallel your findings or if I can be of any further assistance please contact me.

Beth Johnson, DVM, DACVIM
Beth.Johnson@sonopath.com