
**PATIENT PRESENTING CLINICAL SIGNS**

Patches Moreau Hyporexia for about one week, on and off lethargy, PE WNL. Has been on Denamarin and Mirtaz.

**SPECIES**

Feline

Abnormal PE/Chem/CBC/UA Results: Creatinine 52(71-159) ALT 163(0-100) ALP 238(0-90) FPL normal. CBC normal.

**BREED**

DSH

**ULTRASONOGRAPHIC EXAMINATION OF THE ABDOMEN**
**Urinary System**
**SEX**

Spayed Female

The urinary bladder is moderately distended with anechoic contents. No masses, inflammatory changes, echogenic sediment, or cystoliths are observed. The urinary bladder, trigone, and visible pelvic urethra are normal in thickness with a smooth mucosal surface.

**AGE**

13yr

Kidneys are overall normal in size and shape with smooth peripheral margination. A normal 1:3 cortex-to-medulla ratio is maintained. The medulla and cortices are uniform in texture with some mild increased cortical echogenicity and mild loss of corticomedullary distinction, expected in this age patient. There is no evidence of pyelectasia, mineral, or infarcts observed. The left kidney measures 3.01 cm. The right kidney measures 3.55 cm.

**WEIGHT**

7.3lbs

**Adrenal Glands**
**INTERPRETED BY**

Beth Johnson, DVM  
 DACVIM

The right adrenal gland is normal in size (0.39 cm), shape, and contour. Corticomedullary structure is unremarkable. Visible surrounding vasculature appears normal.

The left adrenal gland is normal in size (0.4 cm), shape, and contour. Corticomedullary structure is unremarkable. Visible surrounding vasculature appears normal.

**IMAGING PERFORMED BY**

Crystal Hill

**Spleen**

The spleen is subjectively normal in size with a normal smooth capsular contour. Parenchyma is appropriately finely textured and homogenous with normal echogenicity relative to surrounding tissue (hyperechoic to liver). No focal nodules or masses are observed. Splenic vasculature appears normal.

**HOSPITAL NAME**

St. Catharines Animal  
 Hospital

**Liver**

The liver is subjectively normal in size with normal smooth curvilinear peripheral contour. Parenchyma is appropriately hypoechoic to the spleen in echogenicity and appropriately mildly coarse and homogenous in echotexture. Multi-focal nodules/masses of mixed echogenicity primarily hyperechoic in echogenicity but containing multiple cysts of varying size. Primarily in the mid-caudal liver with the most discrete cystic mass measuring approximately 3 cm in diameter. Visible vasculature and biliary tree appear normal without distension or congestion.

**REFERRING VET**

Dr. Gokhale

**INVOICE**

10269

The gallbladder is non-distended in size. The wall is smooth without visible thickening. Luminal contents are primarily anechoic. There is no evidence of cystic or common bile duct dilation.

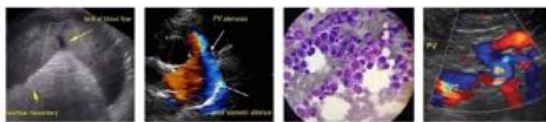
**DATE**

6/20/23

**Gastrointestinal**

The stomach wall is normal in thickness (canine < 0.5 cm and feline < 0.4 cm) and layering. The lumen of the stomach is empty with no evidence of obstruction or foreign material. Pyloric outflow tract appears patent.

The visible small intestines are normal in wall thickness and layering (canine duodenum < 0.5 cm and feline duodenum < 0.4 cm; other < 0.3 cm). Small intestinal motility appears adequate (1-3



**PATIENT**

Patches Moreau

**SPECIES**

Feline

**BREED**

DSH

**SEX**

Spayed Female

**AGE**

13yr

**WEIGHT**

7.3lbs

**INTERPRETED BY**

Beth Johnson, DVM  
DACVIM

**IMAGING  
PERFORMED BY**

Crystal Hill

**HOSPITAL NAME**

St. Catharines Animal  
Hospital

**REFERRING VET**

Dr. Gokhale

**INVOICE**

10269

**DATE**

6/20/23

contractions per min). The lumen of the small intestine is empty with no evidence of obstruction or foreign material.

The visible colon is normal in wall thickness (< 0.2 cm) and layering. Contents are consistent with normal formed feces and gas.

**Pancreas**

Pancreas is prominent (enlarged) in size, hypoechoic to surrounding tissue and has a mildly irregular undulating contour. Parenchyma is coarse with mixed echogenic remodeling noted. Pancreatic duct dilation is noted.

**Free Abdomen**

There is no evidence of free peritoneal effusion noted in these images.

There is no apparent lymphadenopathy noted in these images.

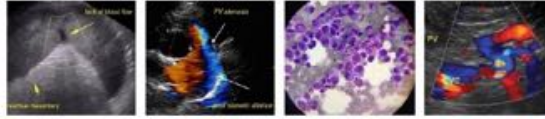
**ULTRASONOGRAPHIC FINDINGS**

- **Feline biliary cystadenomas** – In a senior cat, this liver lesion is most consistent with multiple benign biliary cystadenomas. Malignancy cannot be ruled out but is considered less likely given lack of clinical signs and/or laboratory changes.
- Chronic active pancreatitis with possible concurrent pancreatic cysts versus pancreatic nodular hyperplasia suspected.

**INTERPRETATION OF THE FINDINGS & FURTHER RECOMMENDATIONS**

Given this patient's decreased appetite further evaluation of the digestion and absorption could be considered via a gastrointestinal malabsorption panel (including cobalamin, folate, TLI, and PLI) to Texas A&M GI Laboratory is recommended for further evaluation of GI and pancreatic function. Additionally, a fine needle aspirate of the liver could be considered if the patient's coagulation status is appropriate.

In the meantime, treatment recommendations include fluid therapy, anti-emetics, gastroprotectants, hepatic nutraceuticals such as ursodiol and/or Denamarin, and broad-spectrum antibiotics. Nutritional support is critical to prevent/manage concurrent hepatic lipidosis, so appetite stimulants and/or, if indicated, feeding tube placement is also recommended.



**PATIENT**

Patches Moreau

**SPECIES**

Feline

**BREED**

DSH

**SEX**

Spayed Female

**AGE**

13yr

**WEIGHT**

7.3lbs

**INTERPRETED BY**

Beth Johnson, DVM  
DACVIM

**IMAGING PERFORMED BY**

Crystal Hill

**HOSPITAL NAME**

St. Catharines Animal  
Hospital

**REFERRING VET**

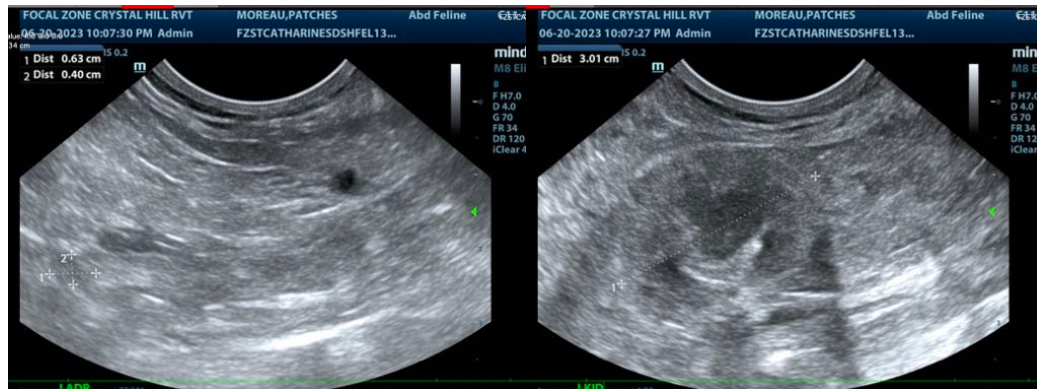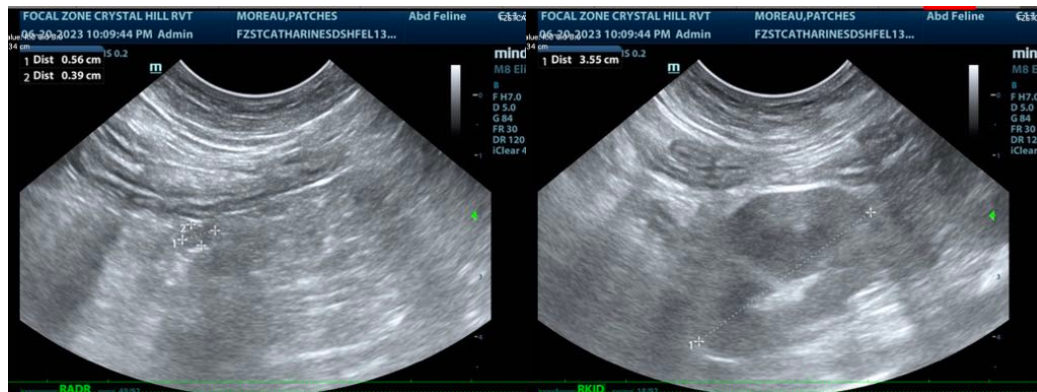
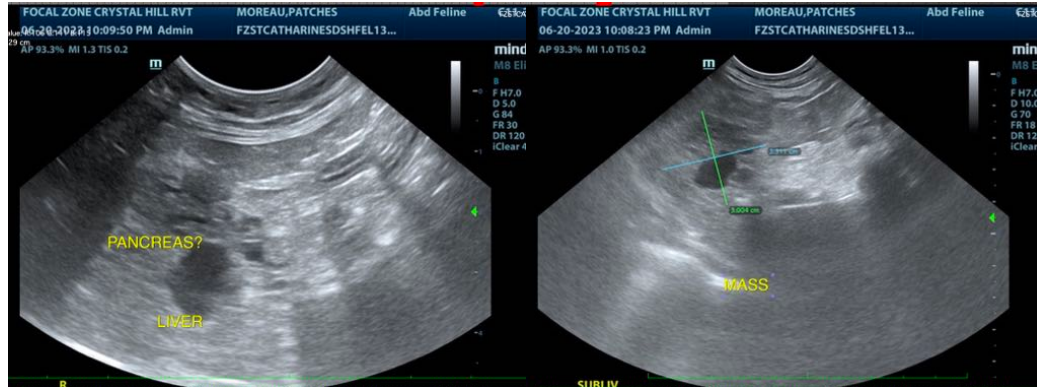
Dr. Gokhale

**INVOICE**

10269

**DATE**

6/20/23



The information and recommendations provided are based on the images presented by the referring veterinarian/sonographer. No evaluation can be communicated regarding pathology that was not visible in the image/video clips provided.

Thank you for this referral. If the clinical or image interpretation does not parallel your findings or if I can be of any further assistance, please contact me.

**Beth Johnson, DVM, DACVIM**  
info@sonopath.com