

PATIENT

Wally Toth

SPECIES

Canine

BREED

Shih Tzu

SEX

Neutered Male

AGE

12

WEIGHT

20

INTERPRETED BY

Beth Johnson, DVM
DACVIM

IMAGING PERFORMED BY

Hope Gallo

HOSPITAL NAME

Animal Mansion
Veterinary Hospital

REFERRING VET

Shelley Parker, DVM

INVOICE

75590

DATE

6/2/26

PRESENTING CLINICAL SIGNS

Had AUS in 204 due for anorexia and PU/PD. Patient seems to be back his normal self. At time of previous AUS ALK was 534

Abnormal PE/Chem/CBC/UA Results: ALK 564 after 1 month of Denemarin (was previously 588)

ULTRASONOGRAPHIC EXAMINATION OF THE ABDOMEN

Urinary System

Urinary bladder is only mildly distended (empty). Visible contents are anechoic. Urinary bladder wall is unable to be fully assessed for pathology without further distension. No visible masses or definitive cystoliths are observed. The trigone and visible pelvic urethra are normal thickness with a smooth mucosal surface. In the face of urinary signs and/or suspected urinary bladder pathology, reassessment after complete filling is recommended.

Prostate is normal in size, echotexture and echogenicity for a neutered male.

The right kidney is normal is size (5.6 cm), shape and echogenicity. It has smooth peripheral margination. There is a normal 1:3 cortex to medulla ratio with appropriate corticomedullary distinction. There is no evidence of pyelectasia or infarcts observed. Non-obstructive linear multifocal hyperechoic diverticular foci with acoustic shadowing are noted.

The left kidney is normal is size (5.0 cm), shape and echogenicity. It has smooth peripheral margination. There is a normal 1:3 cortex to medulla ratio with appropriate corticomedullary distinction. There is no evidence of pyelectasia or infarcts observed. Non-obstructive linear multifocal hyperechoic diverticular foci with acoustic shadowing are noted.

Adrenal Glands

Adrenal glands are mildly plump. Normal shape and contour are maintained without evidence of capsular invasion. Corticomedullary structure is unremarkable. Visible surrounding vasculature appears normal. Left caudal measures 0.84 cm. Right caudal measures 0.77 cm. The cranial poles are difficult to fully visualize/isolate for measurement.

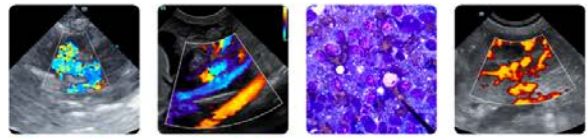
Spleen

The spleen is subjectively normal in size with a normal smooth capsular contour. Parenchyma is appropriately finely textured and homogenous with normal echogenicity relative to surrounding tissue (hyperechoic to liver). No focal nodules or masses are observed. Splenic vasculature appears normal.

Liver

The liver is subjectively normal in size with normal smooth curvilinear peripheral contour. Parenchyma is appropriately hypoechoic to the spleen in echogenicity and appropriately mildly coarse and homogenous in echotexture. No focal lesions are observed. Visible vasculature and biliary tree appear normal without distension or congestion.

The gallbladder is non-distended in size. The wall is smooth without visible thickening. Luminal contents are primarily anechoic. There is no evidence of cystic or common bile duct dilation.



PATIENT

Wally Toth

SPECIES

Canine

BREED

Shih Tzu

SEX

Neutered Male

AGE

12

WEIGHT

20

INTERPRETED BY

Beth Johnson, DVM
DACVIM

IMAGING PERFORMED BY

Hope Gallo

HOSPITAL NAME

Animal Mansion
Veterinary Hospital

REFERRING VET

Shelley Parker, DVM

INVOICE

75590

DATE

6/2/26

Gastrointestinal

The visible stomach wall is normal in thickness and layering. The lumen of the stomach is mildly distended with a small to moderate amount of echogenic non-shadowing luminal contents and gas consistent with normal ingesta. There is no evidence of obstruction, foreign material or infiltrative disease. Pyloric outflow tract appears patent.

The visible small intestines are normal in wall thickness and layering. Small intestinal motility appears adequate (1-3 contractions per min). The lumen of the small intestine is empty with no evidence of obstruction, foreign material or infiltrative disease.

The visible colon is normal in wall thickness (< 0.2 cm) and layering. Contents are consistent with normal formed feces and gas.

Pancreas

The pancreas that is observed appears appropriately isoechoic to surrounding omental fat. Visible capsule is smooth and normal in contour. Visible pancreatic parenchyma is homogenous and unremarkable. There is no visible pancreatic duct dilation. There is no evidence of active peripancreatic inflammation.

Free Abdomen

There is no visible free peritoneal effusion noted in these images.

There is no apparent pathologic lymphadenopathy noted in these images.

PRIMARY FINDINGS

- Mildly/subjective bilateral adrenomegaly – In a patient diagnosed with hyperadrenocorticism, this finding is most consistent with adrenal hyperplasia secondary to pituitary dependent hyperadrenocorticism. This finding can also be seen with stress and/or normal patient variant. Interpret in combination with clinical signs of hyperadrenocorticism and/or other adrenal disease.

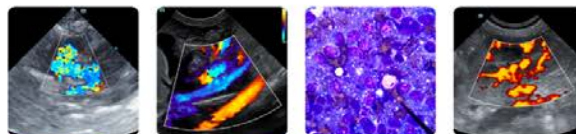
SECONDARY FINDINGS

- Non-obstructive dystrophic mineralization bilaterally in the kidneys.

INTERPRETATION OF THE FINDINGS & FURTHER RECOMMENDATIONS

Differentials for a primary cholestatic liver enzyme pattern (increased ALP) are vast and non-specific. Differentials include, but are not limited to, benign nodular hyperplasia which occurs in 70% of older dogs and often does not result in an abnormal ultrasound, reactive or idiopathic/vacuolar hepatopathy, cholestasis and/or hyperadrenocorticism as well as many chronic non-hepatobiliary diseases such as chronic infections/inflammation from dental disease, IBD, neoplasia, hyperlipidemia, hypothyroidism, chronic pancreatitis, chronic stress, etc.

- Especially given the mild bilateral adrenomegaly, adrenocortical testing such as a low dose dexamethasone suppression test could be considered if clinical signs of hyperadrenocorticism are present.
- A blood pressure is recommended if not recently evaluated.



PATIENT

Wally Toth

SPECIES

Canine

BREED

Shih Tzu

SEX

Neutered Male

AGE

12

WEIGHT

20

INTERPRETED BY

Beth Johnson, DVM
DACVIM

IMAGING PERFORMED BY

Hope Gallo

HOSPITAL NAME

Animal Mansion
Veterinary Hospital

REFERRING VET

Shelley Parker, DVM

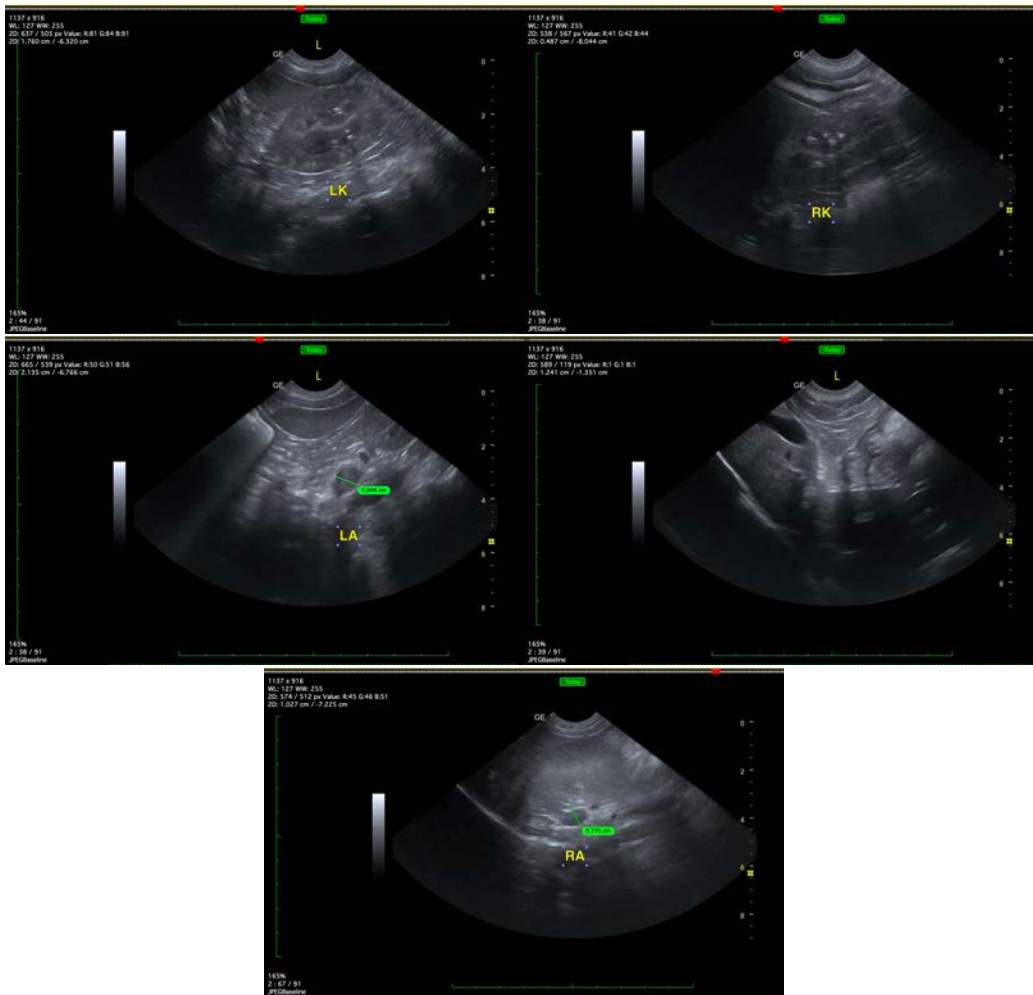
INVOICE

75590

DATE

6/2/26

- Ursodiol could be considered if gallbladder sludge is noted as a finding.
- A fine needle aspirate of the liver could be considered if patient's coagulation status is appropriate.
- Otherwise, recommendations include addressing any other concurrent disease and monitoring. If values are progressive, recheck imaging is recommended.



The information and recommendations provided are based on the images presented by the referring veterinarian/sonographer. No evaluation can be communicated regarding pathology that was not visible in the image/video clips provided.

Thank you for this referral. If the clinical or image interpretation does not parallel your findings or if I can be of any further assistance please contact me.

Beth Johnson, DVM, DACVIM
info@sonopath.com