



**PATIENT**

Dora Brigmantas

**SPECIES**

Canine

**BREED**

Staffy

**SEX**

Spayed Female

**AGE**

10 Years

**WEIGHT**

27.2 kg

**INTERPRETED BY**

Beth Johnson, DVM  
 DACVIM

**IMAGING PERFORMED BY**

Kelly Reschny

**HOSPITAL NAME**

BPH Stoney Creek

**REFERRING VET**

Dr. Wittenrich

**INVOICE**

75598

**DATE**

6/2/26

**PRESENTING CLINICAL SIGNS**

Collapsed when admitted for lump removal Sx  
 Abnormal PE/Chem/CBC/UA Results: Increased ALKP, decreased lymphocytes

**ULTRASONOGRAPHIC EXAMINATION OF THE ABDOMEN**

**Urinary System**

The urinary bladder is adequately distended with anechoic contents. No masses, inflammatory changes, echogenic sediment or cystoliths are observed. The urinary bladder, trigone and visible pelvic urethra are normal in thickness with a smooth mucosal surface.

The right kidney is normal in size (6.5 cm), shape and echogenicity. It has smooth peripheral margination. There is a normal 1:3 cortex to medulla ratio with appropriate corticomedullary distinction. There is no evidence of pyelectasia, mineral or infarcts observed.

The left kidney is normal in size (6.7 cm), shape and echogenicity. It has smooth peripheral margination. There is a normal 1:3 cortex to medulla ratio with appropriate corticomedullary distinction. There is no evidence of pyelectasia, mineral or infarcts observed.

**Adrenal Glands**

The right adrenal gland is normal in size (1.7 cm at cranial pole and 0.80 cm at caudal pole), shape and overall architecture, echogenicity and echotexture. Visible surrounding vasculature appears normal.

The left adrenal gland is normal in size (0.40 cm at cranial pole and 0.60 cm at caudal pole), shape and overall architecture, echogenicity and echotexture. Visible surrounding vasculature appears normal.

**Spleen**

The spleen is subjectively normal in size with a normal smooth capsular contour. Parenchyma is appropriately finely textured and homogenous with normal echogenicity relative to surrounding tissue (hyperechoic to liver). No focal nodules or masses are observed. Splenic vasculature appears normal.

**Liver**

The liver is subjectively normal in size with normal smooth curvilinear peripheral contour. Parenchyma is appropriately hypoechoic to the spleen in echogenicity and appropriately mildly coarse and homogenous in echotexture. No focal lesions are observed. Visible vasculature and biliary tree appear normal without distension or congestion.

The gallbladder is non-distended in size. The wall is smooth without visible thickening. Luminal contents are primarily anechoic. There is no evidence of cystic or common bile duct dilation.

**Gastrointestinal**

The visible stomach wall is normal in thickness and layering. The lumen of the stomach is mildly distended with very echogenic reverberation artifact from intraluminal gas. There is no evidence of obstruction, foreign material, or infiltrative disease; however, visualization is partially inhibited by gas.

The visible small intestines are normal in wall thickness and layering. Small intestinal motility appears adequate (1-3 contractions per min). The lumen of the small intestine is mildly distended with very



**PATIENT**

Dora Brigmantas

**SPECIES**

Canine

**BREED**

Staffy

**SEX**

Spayed Female

**AGE**

10 Years

**WEIGHT**

27.2 kg

**INTERPRETED BY**

Beth Johnson, DVM  
DACVIM

**IMAGING PERFORMED BY**

Kelly Reschny

**HOSPITAL NAME**

BPH Stoney Creek

**REFERRING VET**

Dr. Wittenrich

**INVOICE**

75598

**DATE**

6/2/26

echogenic reverberation artifact from intraluminal gas. There is no evidence of obstruction, foreign material, or infiltrative disease; however, visualization is partially inhibited by gas.

The visible colon is normal in wall thickness (< 0.2 cm) and layering. Contents are consistent with normal formed feces and gas.

**Pancreas**

The pancreas that is observed appears appropriately isoechoic to surrounding omental fat. Visible capsule is smooth and normal in contour. Visible pancreatic parenchyma is homogenous and unremarkable. There is no visible pancreatic duct dilation. There is no evidence of active peripancreatic inflammation.

**Free Abdomen**

There is no visible free peritoneal effusion noted in these images.

There is no apparent pathologic lymphadenopathy noted in these images.

**ULTRASONOGRAPHIC FINDINGS**

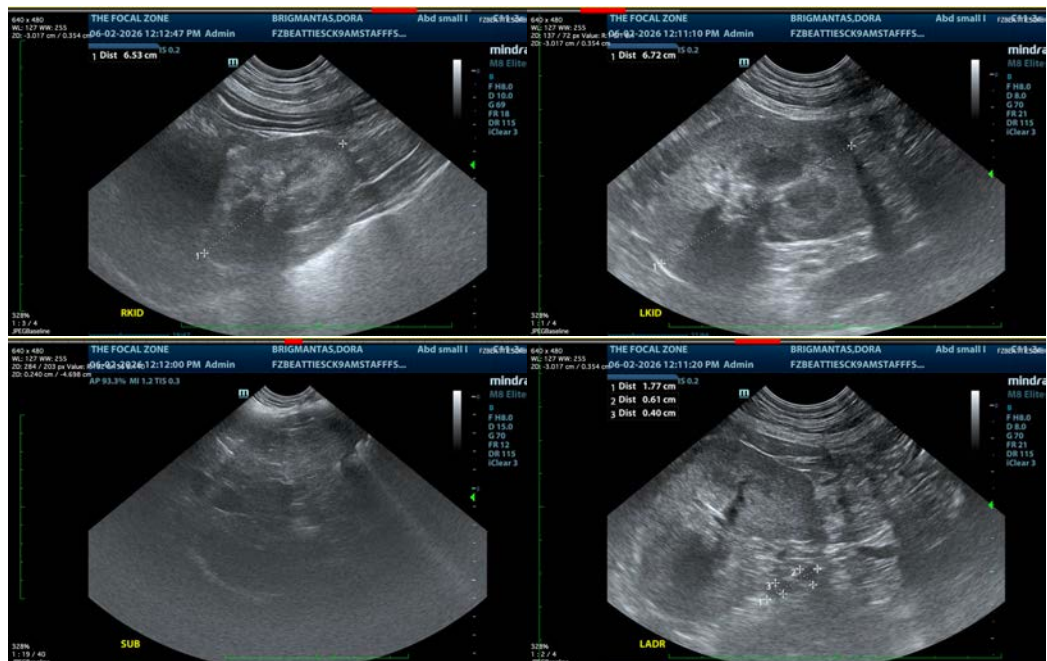
- This is a largely unremarkable/structurally normal abdomen without a definitive ultrasonographically visible intraabdominal explanation for patient's reported collapse.

**INTERPRETATION OF THE FINDINGS & FURTHER RECOMMENDATIONS**

Three view thoracic radiographs are recommended for further assessment of cardio-pulmonary status as well as to further evaluate for any evidence of metastatic disease, if not recently evaluated.

As is reportedly already in place, full cardiac evaluation is recommended.

A blood pressure is recommended if not recently evaluated.





**PATIENT**

Dora Brigmantas

**SPECIES**

Canine

**BREED**

Staffy

**SEX**

Spayed Female

**AGE**

10 Years

**WEIGHT**

27.2 kg

**INTERPRETED BY**

Beth Johnson, DVM  
DACVIM

**IMAGING PERFORMED BY**

Kelly Reschny

**HOSPITAL NAME**

BPH Stoney Creek

**REFERRING VET**

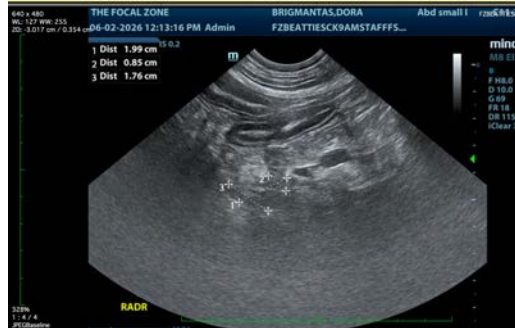Dr. Wittenrich

**INVOICE**

75598

**DATE**

6/2/26



The information and recommendations provided are based on the images presented by the referring veterinarian/sonographer. No evaluation can be communicated regarding pathology that was not visible in the image/video clips provided.

Thank you for this referral. If the clinical or image interpretation does not parallel your findings or if I can be of any further assistance please contact me.

**Beth Johnson, DVM, DACVIM**  
info@sonopath.com