



PATIENT

Oreo Urinyi

SPECIES

Canine

BREED

Shih Tzu

SEX

Spayed Female

AGE

14 Years 2 Months

WEIGHT

15.5 Pounds

INTERPRETED BY

Beth Johnson, DVM
DACVIM

IMAGING PERFORMED BY

Dr. Gillian Striano-Kaplan

HOSPITAL NAME

Ramsey Vet Hospital

REFERRING VET

Dr. Gillian Striano-Kaplan

INVOICE

38795

DATE

6/16/22

PRESENTING CLINICAL SIGNS

pre-anesthetic, mild liver enzyme elevation
Abnormal PE/Chem/CBC/UA Results: WBC: 5.5L, MONO: 0.08L, MONO %: 1.4L, RBC: 9.33H, HGB: 20.9H, HCT: 63.3H, Albumin: 4.3H, Cholesterol: 365H, ALT: 126H, ALP: >993H,

ULTRASONOGRAPHIC EXAMINATION OF THE ABDOMEN

Urinary System

Urinary bladder is moderately distended. It has a normal uniform wall thickness (<0.2 cm). Contents include primarily anechoic fluid combined with both gravity dependent and suspended echogenic non-shadowing debris within the fluid. No masses or cystoliths are observed. The trigone and visible pelvic urethra are normal in thickness with a smooth mucosal surface.

The right kidney is normal in size (4.6 cm) and shape with smooth peripheral margination. A normal 1:3 cortex to medulla ratio is maintained. The medulla and cortices are uniform in texture with some mild increased echogenicity and mild loss of corticomedullary distinction. There is no evidence of pyelectasia or infarcts observed. Non-obstructive areas of mineralization/nephroliths are noted, primarily in the diverticular of the kidney.

The left kidney is normal in size (4.3 cm) and shape with smooth peripheral margination. A normal 1:3 cortex to medulla ratio is maintained. The medulla and cortices are uniform in texture with some mild increased echogenicity and mild loss of corticomedullary distinction. There is no evidence of pyelectasia or infarcts observed. Non-obstructive areas of mineralization/nephroliths are noted, primarily in the diverticular of the kidney.

Bilateral renal cortical cysts are present.

Adrenal Glands

The right adrenal gland is normal in size (0.99 cm at the cranial pole and 0.66 cm at the caudal pole), shape and contour. Corticomedullary structure is unremarkable. Visible surrounding vasculature appears normal.

The left adrenal gland is normal in size (0.52 cm at the cranial pole and 0.69 cm at the caudal pole), shape and contour. Corticomedullary structure is unremarkable. Visible surrounding vasculature appears normal.

Spleen

The spleen is subjectively normal in size with a normal smooth capsular contour. Parenchyma is appropriately finely textured and homogenous with normal echogenicity relative to surrounding tissue (hyperechoic to liver). No focal nodules or masses are observed. Splenic vasculature appears normal.

Liver

Liver is subjectively enlarged. Margins are smooth but round. It has a normal homogenous echotexture. Parenchyma is diffusely hyperechoic characterized by less prominent than normal portal vein walls and increased echogenicity relative to the spleen. No focal lesions are observed. Visible vasculature and biliary tree appear normal without distension or congestion.

GB is moderately distended with anechoic bile and gravity dependent echogenic sediment. The wall is smooth without visible thickening. There is no evidence of cystic or CBD dilation. There is no evidence of effusion or inflammation.



PATIENT

Oreo Urinyi

Gastrointestinal

The stomach wall is normal in thickness (canine < 0.5 cm and feline < 0.4 cm) and layering. The lumen of the stomach is empty with no evidence of obstruction, foreign material or infiltrative disease. Pyloric outflow tract appears patent.

SPECIES

Canine

The visible small intestines are normal in wall thickness and layering (canine duodenum < 0.5 cm and feline duodenum < 0.4 cm; other < 0.3 cm). Small intestinal motility appears adequate (1-3 contractions per min). The lumen of the small intestine is empty with no evidence of obstruction, foreign material or infiltrative disease.

BREED

Shih Tzu

The visible colon is normal in wall thickness (< 0.2 cm) and layering. Contents are consistent with normal formed feces and gas.

SEX

Spayed Female

Pancreas

The pancreatic parenchyma is appropriately isoechoic to surrounding tissue. Visible capsule is smooth and normal in contour. There is no visible pancreatic duct dilation. There is no evidence of active peripancreatic inflammation.

AGE

14 Years 2 Months

Free Abdomen

There is no evidence of peritoneal effusion. There is no apparent lymphadenopathy.

WEIGHT

15.5 Pounds

ULTRASONOGRAPHIC FINDINGS

- Hyperechoic hepatomegaly – most consistent with benign steroid (endocrine) hepatopathy or reactive or idiopathic hepatopathy. Infiltrative neoplasia such as round cell neoplasia is also possible, but considered less likely.
- Gallbladder debris - Cholecystic debris is of unknown clinical significance. It can be seen with biliary stasis from fasting or illness. Cholecystic debris is not necessarily related to hepatobiliary disease. Echogenic bile is most commonly an incidental finding in dogs and should be interpreted in combination with clinical signs such as nausea, inappetence, cranial abdominal discomfort and/or laboratory changes such as increased ALP and/or increased Tbili.

INTERPRETED BY

Beth Johnson, DVM
DACVIM

IMAGING PERFORMED BY

Dr. Gillian Striano-Kaplan

HOSPITAL NAME

Ramsey Vet Hospital

SECONDARY FINDINGS

- Urinary bladder sediment – Urine changes are most consistent with cellular debris or crystalluria.
- Age related kidney change – This finding is expected/consistent with age-related mild degenerative disease and should be interpreted clinically in combination with laboratory changes.
- Non-obstructive nephrolithiasis in both kidneys.

REFERRING VET

Dr. Gillian Striano-Kaplan

INTERPRETATION OF THE FINDINGS & FURTHER RECOMMENDATIONS

INVOICE

38795

ALP – Differentials are vast and non-specific. Differentials include, but are not limited to, benign nodular hyperplasia which occurs in 70% of older dogs and often does not result in an abnormal ultrasound, reactive or idiopathic/vacuolar hepatopathy, cholestasis and/or hyperadrenocorticism as well as many chronic non-hepatobiliary diseases such as chronic infections/inflammation from dental disease, IBD, neoplasia, hyperlipidemia, hypothyroidism, chronic pancreatitis, chronic stress, etc.

DATE

6/16/22



PATIENT

Oreo Urinyi

There is no ultrasonographic evidence of cholestasis. Adrenocortical testing such as a low dose dexamethasone suppression test could be considered if clinical signs of hyperadrenocorticism are present. Ursodiol could be considered if gallbladder sludge is noted. A fine needle aspirate of the liver could be considered if patient's coagulation status is appropriate. Otherwise, recommendations include addressing any other concurrent disease and monitoring. If values are progressive, recheck imaging is recommended.

SPECIES

Canine

Specifically for this patient, if clinical signs of hyperadrenocorticism are present, such as polyuria, polydipsia, panting, hair loss, etc., then testing for hyperadrenocorticism with a low dose Dexamethasone suppression test could be considered, as hyperadrenocorticism can result in a large liver and gallbladder debris, as seen here. However, without clinical signs, recommendations include monitoring, and only considering testing when and if clinical signs develop. In the meantime, a blood pressure is recommended if not recently evaluated, as is a urinalysis and urine culture, if indicated based on urinalysis results.

BREED

Shih Tzu

SEX

Spayed Female

No contraindications to surgery are present.

AGE

14 Years 2 Months

WEIGHT

15.5 Pounds

INTERPRETED BY

Beth Johnson, DVM
DACVIM

IMAGING PERFORMED BY

Dr. Gillian Striano-Kaplan

HOSPITAL NAME

Ramsey Vet Hospital

REFERRING VET

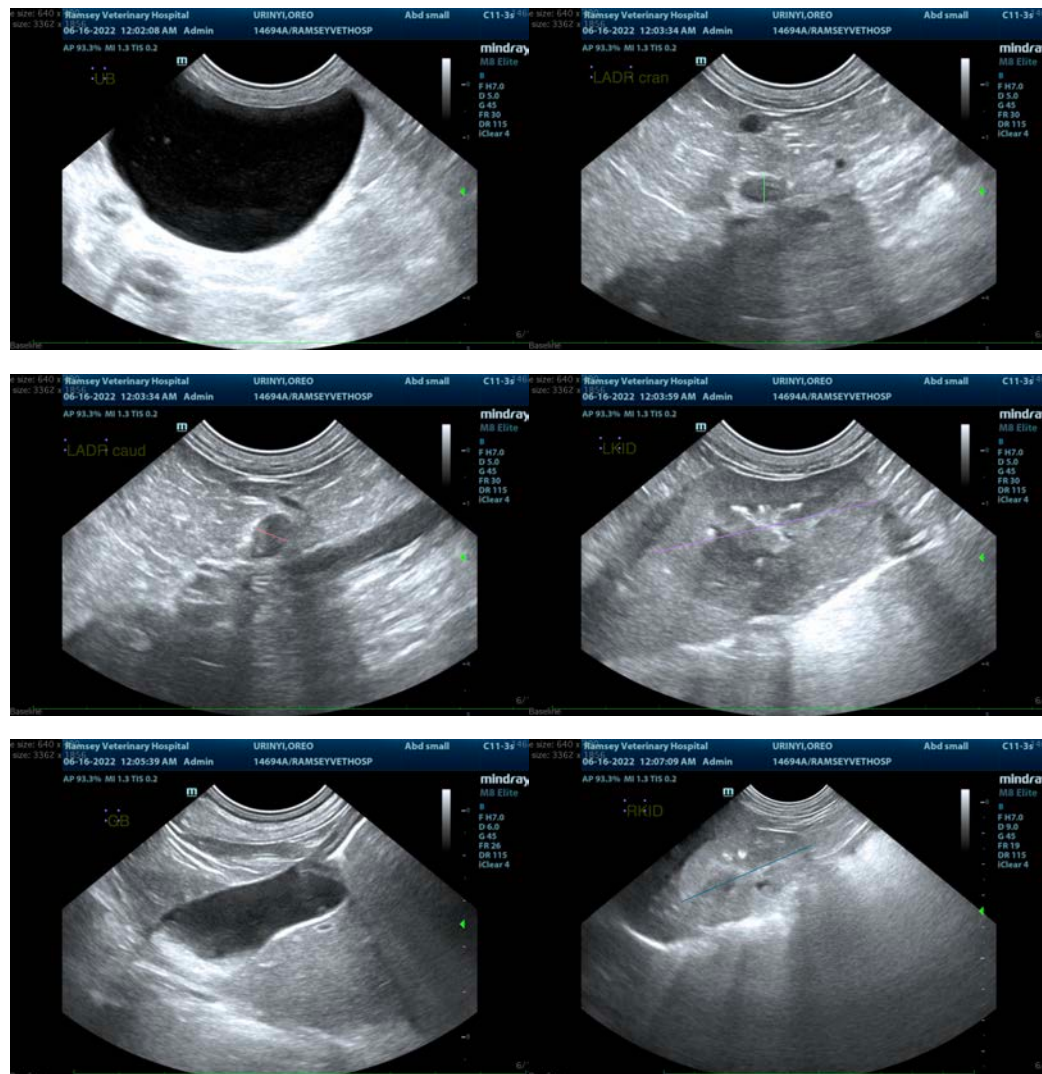
Dr. Gillian Striano-Kaplan

INVOICE

38795

DATE

6/16/22





PATIENT

Oreo Urinyi

SPECIES

Canine

BREED

Shih Tzu

SEX

Spayed Female

AGE

14 Years 2 Months

WEIGHT

15.5 Pounds

INTERPRETED BY

Beth Johnson, DVM
DACVIM

IMAGING PERFORMED BY

Dr. Gillian Striano-Kaplan

HOSPITAL NAME

Ramsey Vet Hospital

REFERRING VET

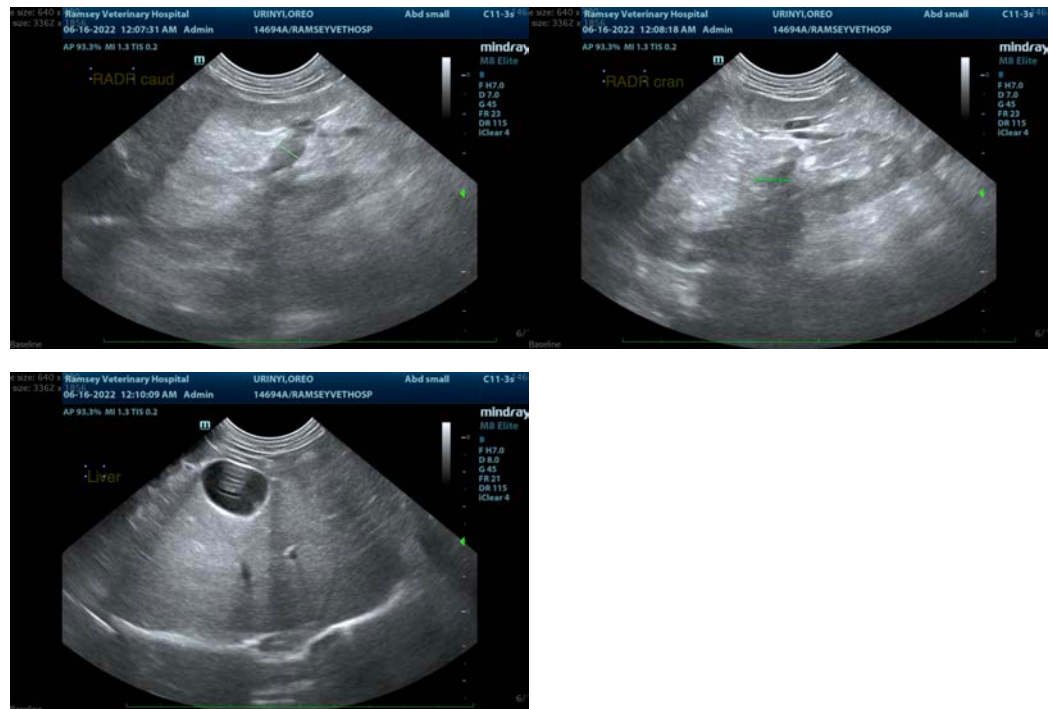
Dr. Gillian Striano-Kaplan

INVOICE

38795

DATE

6/16/22



The information and recommendations provided are based on the images presented by the referring veterinarian/sonographer. No evaluation can be communicated regarding pathology that was not visible in the image/video clips provided.

Thank you for this referral. If the clinical or image interpretation does not parallel your findings or if I can be of any further assistance please contact me.

Beth Johnson, DVM, DACVIM
Beth.Johnson@sonopath.com