



**PATIENT**

Kash Engelman

**SPECIES**

Canine

**BREED**

Golden Retriever

**SEX**

Neutered Male

**AGE**

8 Years

**WEIGHT**

81 Pounds

**INTERPRETED BY**

Beth Johnson, DVM  
DACVIM

**IMAGING PERFORMED BY**

Amy Priest

**HOSPITAL NAME**

Long Valley AH

**REFERRING VET**

Dr. Stephanie Welch

**INVOICE**

38802

**DATE**

6/16/22

**PRESENTING CLINICAL SIGNS**

O reports history of groaning when pet is laying down and appears tense/painful on abd. palpation, concern for pancreatitis or other abdominal pain/discomfort. Had mild lipase elevation on previous BW. No other clinical signs. Has history of mild OA - did rimadyl and dasuquin trial - O reports no improvement (back in May). Presented for routine wellness and O reports pet still will groan slightly when going to lie down. Normal appetite, energy etc.  
Abnormal PE/Chem/CBC/UA Results: 5/23/22: Plts 114K BUT only appear sl. decreased on blood film; clumps & large plts seen Glob's 4.1 Lipase 892

**ULTRASONOGRAPHIC EXAMINATION OF THE ABDOMEN**

**Urinary System**

The urinary bladder is moderately distended with anechoic contents. No masses, inflammatory changes, echogenic sediment or cystoliths are observed. The urinary bladder, trigone and visible pelvic urethra are normal in thickness with a smooth mucosal surface.

Prostate (neutered) is normal in size, echotexture and echogenicity for a neutered male.

The right kidney is normal in size (7.3 cm), shape and echogenicity. It has smooth peripheral margination. There is a normal 1:3 cortex to medulla ratio with appropriate corticomedullary distinction. There is no evidence of pyelectasia, mineral or infarcts observed.

The left kidney is normal in size (5.4 cm), shape and echogenicity. It has smooth peripheral margination. There is a normal 1:3 cortex to medulla ratio with appropriate corticomedullary distinction. There is no evidence of pyelectasia, mineral or infarcts observed.

**Adrenal Glands**

The right adrenal gland is normal in size (0.84 cm at the cranial pole and 0.84 cm at the caudal pole), shape and contour. Corticomedullary structure is unremarkable. Visible surrounding vasculature appears normal.

The left adrenal gland is normal in size (0.31 cm at the cranial pole and 0.31 cm at the caudal pole), shape and contour. Corticomedullary structure is unremarkable. Visible surrounding vasculature appears normal.

**Spleen**

The spleen is subjectively normal in size with a normal smooth capsular contour. Parenchyma is appropriately finely textured and homogenous with normal echogenicity relative to surrounding tissue (hyperechoic to liver). No focal nodules or masses are observed. Splenic vasculature appears normal.

**Liver**

The liver is subjectively normal in size with normal smooth curvilinear peripheral contour. Parenchyma is appropriately hypoechoic to the spleen in echogenicity and appropriately mildly coarse and homogenous in echotexture. No focal lesions are observed. Visible vasculature and biliary tree appear normal without distension or congestion.

GB is moderately distended with anechoic bile and gravity dependent echogenic sediment, some of which appears mineral in nature. The wall is smooth without visible thickening. There is no evidence of cystic or CBD dilation. There is no evidence of effusion or inflammation.



**PATIENT**

Kash Engelman

**SPECIES**

Canine

**BREED**

Golden Retriever

**SEX**

Neutered Male

**AGE**

8 Years

**WEIGHT**

81 Pounds

**INTERPRETED BY**

Beth Johnson, DVM  
DACVIM

**IMAGING PERFORMED BY**

Amy Priest

**HOSPITAL NAME**

Long Valley AH

**REFERRING VET**

Dr. Stephanie Welch

**INVOICE**

38802

**DATE**

6/16/22

**Gastrointestinal**

The stomach wall is normal in thickness (canine < 0.5 cm and feline < 0.4 cm) and layering. The lumen of the stomach is mildly distended with echogenic non-shadowing luminal contents and gas consistent with normal ingesta. There is no evidence of obstruction, foreign material or infiltrative disease. Pyloric outflow tract appears patent. \*\*Note: see "other".

The visible small intestines are normal in wall thickness and layering (canine duodenum < 0.5 cm and feline duodenum < 0.4 cm; other < 0.3 cm). Small intestinal motility appears adequate (1-3 contractions per min). The lumen of the small intestine is empty with no evidence of obstruction, foreign material or infiltrative disease.

The visible colon is normal in wall thickness (< 0.2 cm) and layering. Contents are consistent with normal formed feces and gas.

**Pancreas**

The pancreatic parenchyma is appropriately isoechoic to surrounding tissue. Visible capsule is smooth and normal in contour. There is no visible pancreatic duct dilation. There is no evidence of active peripancreatic inflammation. \*\*Note: see "other".

**Other**

There is no evidence of peritoneal effusion. There is no apparent lymphadenopathy.

In the cranial abdomen, adjacent to the stomach, there is a 3-4 cm hypoechoic structure that appears to be associated with the gastric mucosa. However, the stomach is full of ingesta and gas, and is not overdistended. There is no evidence of an obstructive pattern that would be expected with a gastric mass. Therefore, a hypoechoic pancreas adjacent to the stomach versus other normal tissue is possible. Fluid within the stomach is possible, or even a foreign object. Again, there is no obstructive pattern and no gastric dilation.

**ULTRASONOGRAPHIC FINDINGS**

- Hypoechoic structure adjacent to stomach (described above) – Rule outs include a gastric mass versus normal hypoechoic pancreatic or other tissue pressing up against a full stomach, making it look like a mass, versus fluid or foreign object within the stomach. No obstructive pattern is present.
- Gallbladder debris - Cholecystic debris is of unknown clinical significance. It can be seen with biliary stasis from fasting or illness. Cholecystic debris is not necessarily related to hepatobiliary disease. Echogenic bile is most commonly an incidental finding in dogs and should be interpreted in combination with clinical signs such as nausea, inappetence, cranial abdominal discomfort and/or laboratory changes such as increased ALP and/or increased Tbili.

**INTERPRETATION OF THE FINDINGS & FURTHER RECOMMENDATIONS**

The hypoechoic structure adjacent to the stomach cannot be differentiated as pathologic or not based on these images. Without gastric signs of vomiting or decreased appetite, it is thought more likely that this does not represent pathology. However, if another cause for the patient's reported abdominal pain cannot be discovered, and clinical signs persist, reassessment of the gastric area with an empty stomach and power doppler would be recommended to help differentiate a true lesion versus other.

In the meantime, recommendations include antacid therapy such as twice daily Omeprazole, in case there is some acid reflux causing the reported discomfort. Diet change to a bland, easy to digest diet could be considered. Otherwise, further evaluation of orthopedic, cervical and/or spinal pain is



**PATIENT**

recommended.

Kash Engelman

**SPECIES**

Canine

**BREED**

Golden Retriever

**SEX**

Neutered Male

**AGE**

8 Years

**WEIGHT**

81 Pounds

**INTERPRETED BY**

Beth Johnson, DVM  
DACVIM

**IMAGING PERFORMED BY**

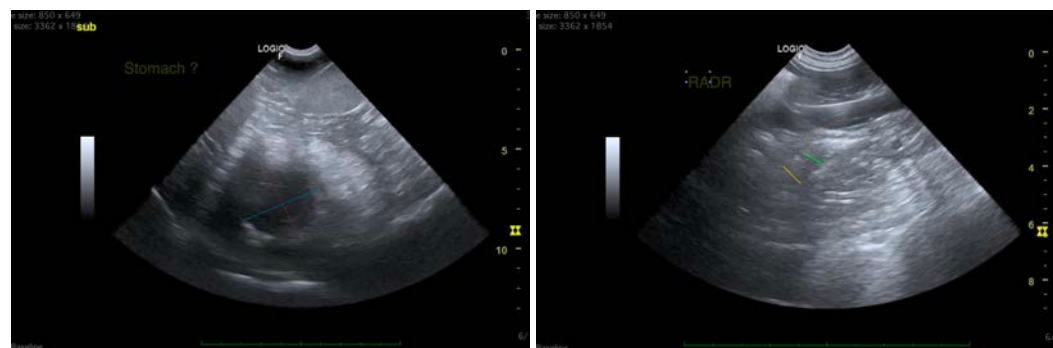
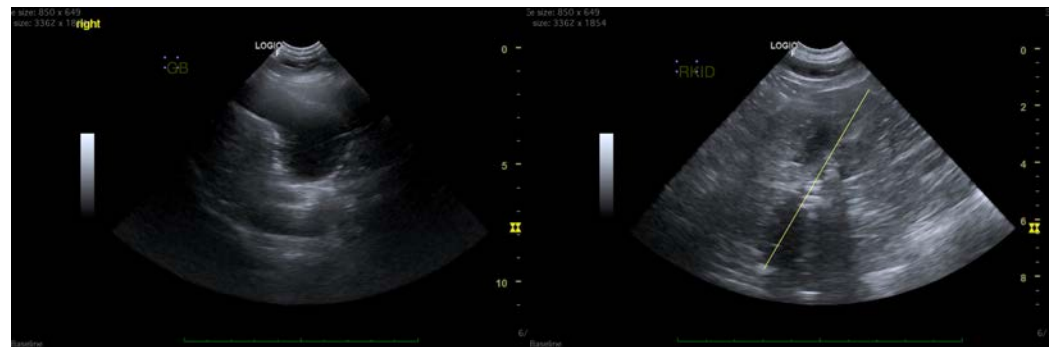
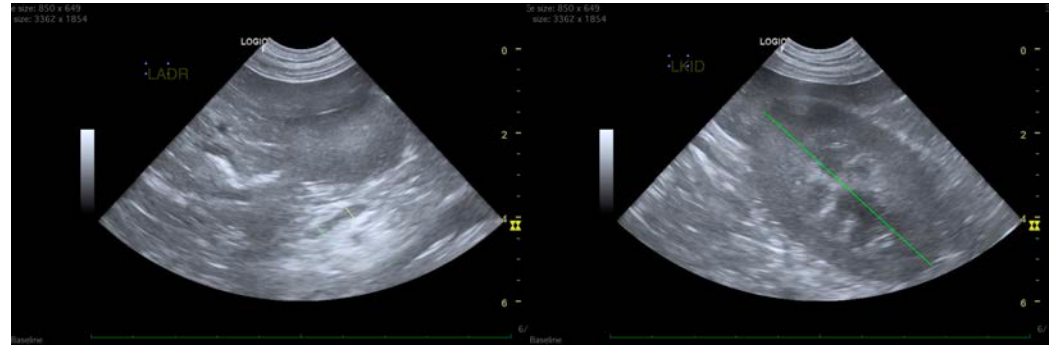
Amy Priest

**HOSPITAL NAME**

Long Valley AH

**REFERRING VET**

Dr. Stephanie Welch



The information and recommendations provided are based on the images presented by the referring veterinarian/sonographer. No evaluation can be communicated regarding pathology that was not visible in the image/video clips provided.

Thank you for this referral. If the clinical or image interpretation does not parallel your findings or if I can be of any further assistance please contact me.

**Beth Johnson, DVM, DACVIM**  
Beth.Johnson@sonopath.com

**INVOICE**

38802

**DATE**

6/16/22