

**DATE PRESENTING CLINICAL SIGNS**

6/15/23 CC- Yellow ears, not eating, vomiting last couple of weeks. PE- Alert, weight loss, ++jaundiced
Spleen palpates enlarged. T- 102.8; HR 188.

PATIENT

Wicked Cirigliano

Current Medications: None before exam. Did Rx Metronidazole 160mg/ml, 0.5ml BID.
Lab Results: T. Bili- 12.2TP- 10.6, Glob- 7.8, Platelets 77 (may be clotted), HCT- WNL, 36.5.
Radiographs: spleen appears enlarged; liver also mildly enlarged; food in stomach.

SPECIES

Feline

Date of Previous IntraPet Ultrasound: No previous.
Sedation: Not required to complete full diagnostic ultrasound.
Stat Report: Not requested.
Imaging Performed By: Andi Parkinson, BS, RDMS.

BREED

DSH

ULTRASONOGRAPHIC EXAMINATION OF THE ABDOMEN**SEX**

Spayed Female

Urinary System

The urinary bladder is moderately distended with anechoic contents. No masses, inflammatory changes, echogenic sediment or cystoliths are observed. The urinary bladder, trigone and visible pelvic urethra are normal in thickness with a smooth mucosal surface.

AGE

6/12/14

Kidneys are overall normal in size and shape with smooth peripheral margination. A normal 1:3 cortex to medulla ratio is maintained. The medulla and cortices are uniform in texture with some mild increased cortical echogenicity and mild loss of corticomedullary distinction, expected in this age patient. There is no evidence of pyelectasia, mineral or infarcts observed. The left kidney measured 3.68 cm. The right kidney measures 3.64 cm.

WEIGHT

9.1 kg

Adrenal Glands

The areas of the adrenal glands are imaged without evident adrenal gland pathology.

INTERPRETED BYBeth Johnson, DVM
DACVIM**Spleen**

Spleen is markedly large in size with subtly scalloped or undulating capsular contour. Parenchyma is normal in echogenicity with a mildly coarse/heterogenous echotexture. No focal nodules or masses are observed. Splenic vasculature appears normal.

HOSPITAL NAME

Essex Middle River VC

Liver

Liver is subjectively enlarged (swollen contour). Mild parenchymal remodeling with diffusely mildly coarse architecture and increased portal markings is present. No focal nodules or masses are observed. Visible vasculature and biliary tree appear normal without distension or congestion.

REFERRING VET

Dr. Hicks

Gallbladder is moderately distended with anechoic bile as well as suspended and gravity dependent echogenic debris. The wall is smooth without visible thickening. There is no evidence of cystic or CBD dilation. There is no evidence of effusion or inflammation.

INVOICE

43221

Gastrointestinal

The stomach wall is normal in thickness (canine < 0.5 cm and feline < 0.4 cm) and layering. The lumen of the stomach is empty with no evidence of obstruction, foreign material or infiltrative disease. Pyloric outflow tract appears patent.

The visible small intestines are normal in wall thickness and layering (canine duodenum < 0.5 cm and feline duodenum < 0.4 cm; other < 0.3 cm). Small intestinal motility appears adequate (1-3 contractions per min). The lumen of the small intestine is empty with no evidence of obstruction, foreign material or infiltrative disease.

The visible colon is normal in wall thickness (< 0.2 cm) and layering. Contents are consistent with normal formed feces and gas.

Pancreas

The pancreatic parenchyma is appropriately isoechoic to surrounding tissue. Visible capsule is smooth and normal in contour. There is no visible pancreatic duct dilation. There is no evidence of active peripancreatic inflammation.

Free Abdomen

There is no evidence of free peritoneal effusion noted in these images.

There is no apparent lymphadenopathy noted in these images.

PRIMARY FINDINGS

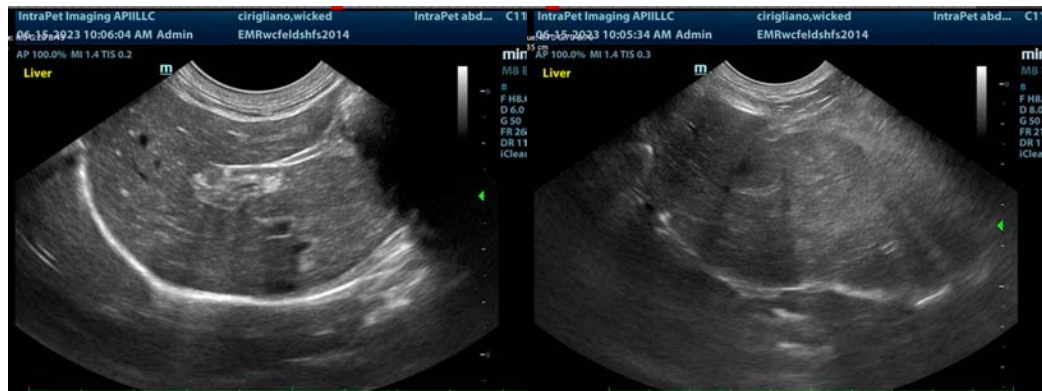
- **Scalloped spleen** – can be associated with benign or malignant infiltrative disease. Common causes include a reactive spleen secondary to immune stimulus or early infiltrative round cell neoplasia such as lymphoma or mast cell tumor.
- **Hypoechoic hepatomegaly** – This appearance is consistent with an acute hepatopathy or acute cholangiohepatitis. Infiltrative neoplasia (round cell neoplasia) should also be considered.

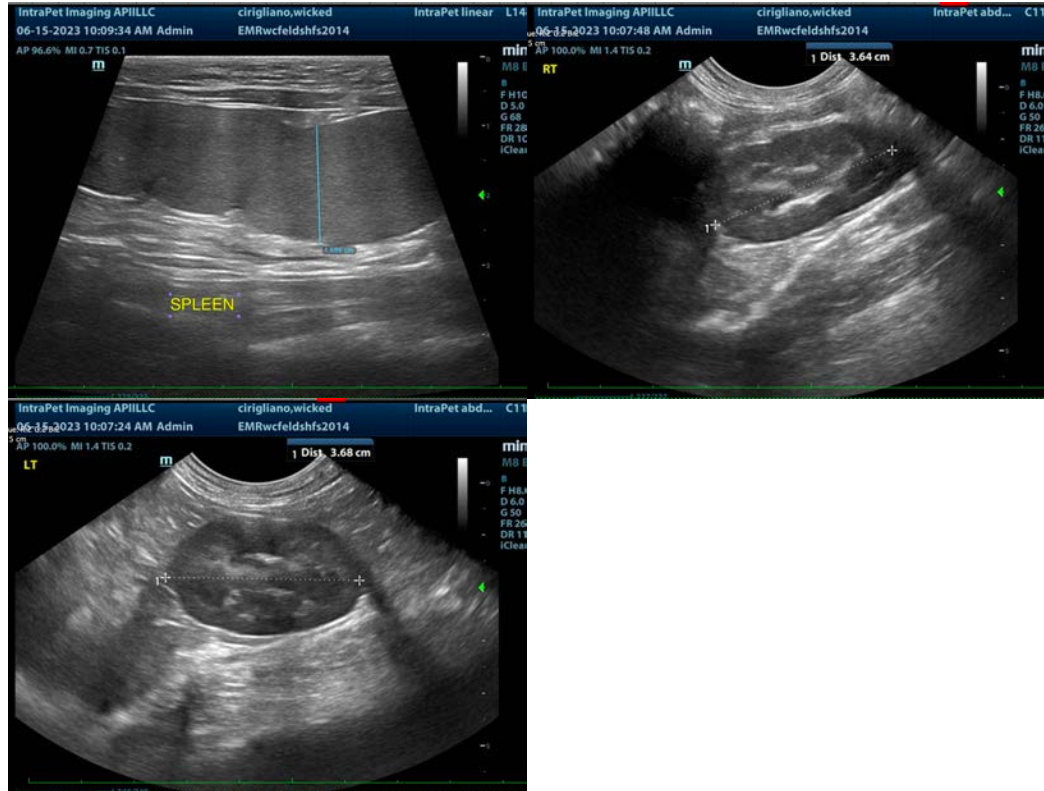
SECONDARY FINDINGS

- **Mild gallbladder debris** - Cholecystic debris is of unknown clinical significance. It can be seen with biliary stasis from fasting or illness, however, it can also be associated with hepatobiliary disease in cats and should be interpreted in combination with clinical signs such as nausea, inappetence, cranial abdominal discomfort and/or laboratory changes such as increased ALP and/or increased Tbil.
- Age related kidney changes

INTERPRETATION OF THE FINDINGS & FURTHER RECOMMENDATIONS

Given the combination of spleen and liver changes as well the hyperglobulinemia, top differential is infiltrative neoplastic disease such as lymphoma versus a benign infectious or inflammatory disease, even FIP. Therefore, next step recommendations include fine needle aspirates of the spleen and liver if patient's coagulation status is appropriate.





The information and recommendations provided are based on the images presented by the referring veterinarian/sonographer. No evaluation can be communicated regarding pathology that was not visible in the image/video clips provided.

Thank you for this referral. If the clinical or image interpretation does not parallel your findings or if I can be of any further assistance please contact me.

Beth Johnson, DVM, DACVIM
info@sonopath.com