



**PATIENT PRESENTING CLINICAL SIGNS**

**Niko Lesko** PUPD with normal bloodwork, UTI possible on UA from 4/23 and course of Amoxi/clav done. Recheck UA with less blood and no obvious UTI signs but PUPD persists. No stones seen on rads from 4/23, hx proteinuria. P on benazepril 20mg BID

**SPECIES**

Canine

**BREED**

Golden Retriever

**SEX**

Neutered Male

**AGE**

12 Years 1 Month

**WEIGHT**

80

**INTERPRETED BY**

Beth Johnson, DVM  
DACVIM

**IMAGING PERFORMED BY**

Jessica Green

**HOSPITAL NAME**

Stanglein Vet Clinic

**REFERRING VET**

Dr. Nathaniel Stanglein

**INVOICE**

43160

**DATE**

6/14/23

**ULTRASONOGRAPHIC EXAMINATION OF THE ABDOMEN**

**Urinary System**

Urinary bladder is adequately distended. It has a normal uniform wall thickness. Contents include primarily anechoic fluid with occasional echogenic non-shadowing debris, most consistent with exfoliated cells, mucous and/or small blood clots. Additionally, there appears to be mineral/sand debris along the dependent wall. Small shadowing cystoliths can't be definitively ruled out. Both sterile inflammation as well as urinary tract infection can also present with echogenic debris. No masses are observed. The trigone and visible pelvic urethra are normal in thickness with a smooth mucosal surface.

The right kidney is normal in size (7.24 cm), shape and echogenicity. It has smooth peripheral margination. There is a normal 1:3 cortex to medulla ratio with appropriate corticomedullary distinction. There is no evidence of pyelectasia, mineral or infarcts observed.

The left kidney is normal in size (7.5 cm), shape and echogenicity. It has smooth peripheral margination. There is a normal 1:3 cortex to medulla ratio with appropriate corticomedullary distinction. There is no evidence of pyelectasia, mineral or infarcts observed.

**Adrenal Glands**

The right adrenal gland is small (flattened contour) measuring 1.5 cm long x 0.85 cm at the cranial pole and 0.52 cm at the caudal pole. Corticomedullary structure is unremarkable. Visible surrounding vasculature appears normal.

The left adrenal gland is enlarged (4.23 cm long x 1.5 cm at the cranial pole and 2.55 cm at the caudal pole) with mild heterogenous parenchymal changes. Swollen capsular expansion is noted without evident capsular escape or vascular invasion.

**Spleen**

The spleen is subjectively normal in size with a normal smooth capsular contour. Parenchyma is appropriately finely textured and homogenous with normal echogenicity relative to surrounding tissue (hyperechoic to liver). No focal nodules or masses are observed. Splenic vasculature appears normal.

**Liver**

The liver is subjectively normal in size with normal smooth curvilinear peripheral contour. Parenchyma is appropriately hypoechoic to the spleen in echogenicity and appropriately mildly coarse and homogenous in echotexture. No focal lesions are observed. Visible vasculature and biliary tree appear normal without distension or congestion.

Gallbladder is moderately distended with anechoic bile as well as suspended and gravity dependent echogenic debris. The wall is smooth without visible thickening. There is no evidence of cystic or CBD dilation. There is no evidence of effusion or inflammation.



**PATIENT**

***Gastrointestinal***

Niko Lesko

The stomach wall is normal in thickness (canine < 0.5 cm and feline < 0.4 cm) and layering. The lumen of the stomach is empty with no evidence of obstruction, foreign material or infiltrative disease. Pyloric outflow tract appears patent.

**SPECIES**

Canine

The visible small intestines are normal in wall thickness and layering (canine duodenum < 0.5 cm and feline duodenum < 0.4 cm; other < 0.3 cm). Small intestinal motility appears adequate (1-3 contractions per min). The lumen of the small intestine is empty with no evidence of obstruction, foreign material or infiltrative disease.

**BREED**

Golden Retriever

The visible colon is normal in wall thickness (< 0.2 cm) and layering. Contents are consistent with normal formed feces and gas.

**SEX**

Neutered Male

***Pancreas***

The pancreatic parenchyma is appropriately isoechoic to surrounding tissue. Visible capsule is smooth and normal in contour. There is no visible pancreatic duct dilation. There is no evidence of active peripancreatic inflammation.

**AGE**

12 Years 1 Month

***Free Abdomen***

**WEIGHT**

80

There is no evidence of free peritoneal effusion noted in these images.

There is no apparent lymphadenopathy noted in these images.

**INTERPRETED BY**

Beth Johnson, DVM  
DACVIM

**ULTRASONOGRAPHIC FINDINGS**

- Left adrenal mass with concurrently flat right adrenal gland – The mass is suggestive of a functional adrenal cortical tumor such as an adenoma or less likely, given the lack of criteria of malignancy but unable to be definitively ruled out, an adenocarcinoma. A pheochromocytoma is possible but considered less likely with a contralaterally flat gland.
- Moderate gallbladder debris - Cholecystic debris is of unknown clinical significance. It can be seen with biliary stasis from fasting or illness. Cholecystic debris is not necessarily related to hepatobiliary disease. Echogenic bile is most commonly an incidental finding in dogs and should be interpreted in combination with clinical signs such as nausea, inappetence, cranial abdominal discomfort and/or laboratory changes such as increased ALP and/or increased Tbili.
- Urinary bladder mineral/sand debris.

**IMAGING PERFORMED BY**

Jessica Green

**HOSPITAL NAME**

Stanglein Vet Clinic

**REFERRING VET**

Dr. Nathaniel Stanglein

**INTERPRETATION OF THE FINDINGS & FURTHER RECOMMENDATIONS**

The described adrenal gland and gallbladder changes can be seen with hyperadrenocorticism (in this case likely adrenal dependent). Given the reported clinical signs also suggestive of hyperadrenocorticism, further testing is recommended:

**INVOICE**

43160

A LDDS test is warranted.

**DATE**

6/14/23

If a LDDS test has been evaluated with a normal result, investigation of possible atypical hyperadrenocorticism with a full ACTH stimulation adrenal panel to the University of Tennessee could be considered.

If not recently evaluated, blood pressure is recommended.



**PATIENT**

Niko Lesko

Additionally, if not recently evaluated, a urinalysis and, if indicated based on urinalysis results, urine culture is also recommended. If protein is present in an otherwise quiet sediment, protein quantification with a urine protein to creatinine ratio is recommended.

**SPECIES**

Canine

**BREED**

Golden Retriever

**SEX**

Neutered Male

**AGE**

12 Years 1 Month

**WEIGHT**

80

**INTERPRETED BY**

Beth Johnson, DVM  
DACVIM

**IMAGING PERFORMED BY**

Jessica Green

**HOSPITAL NAME**

Stanglein Vet Clinic

**REFERRING VET**

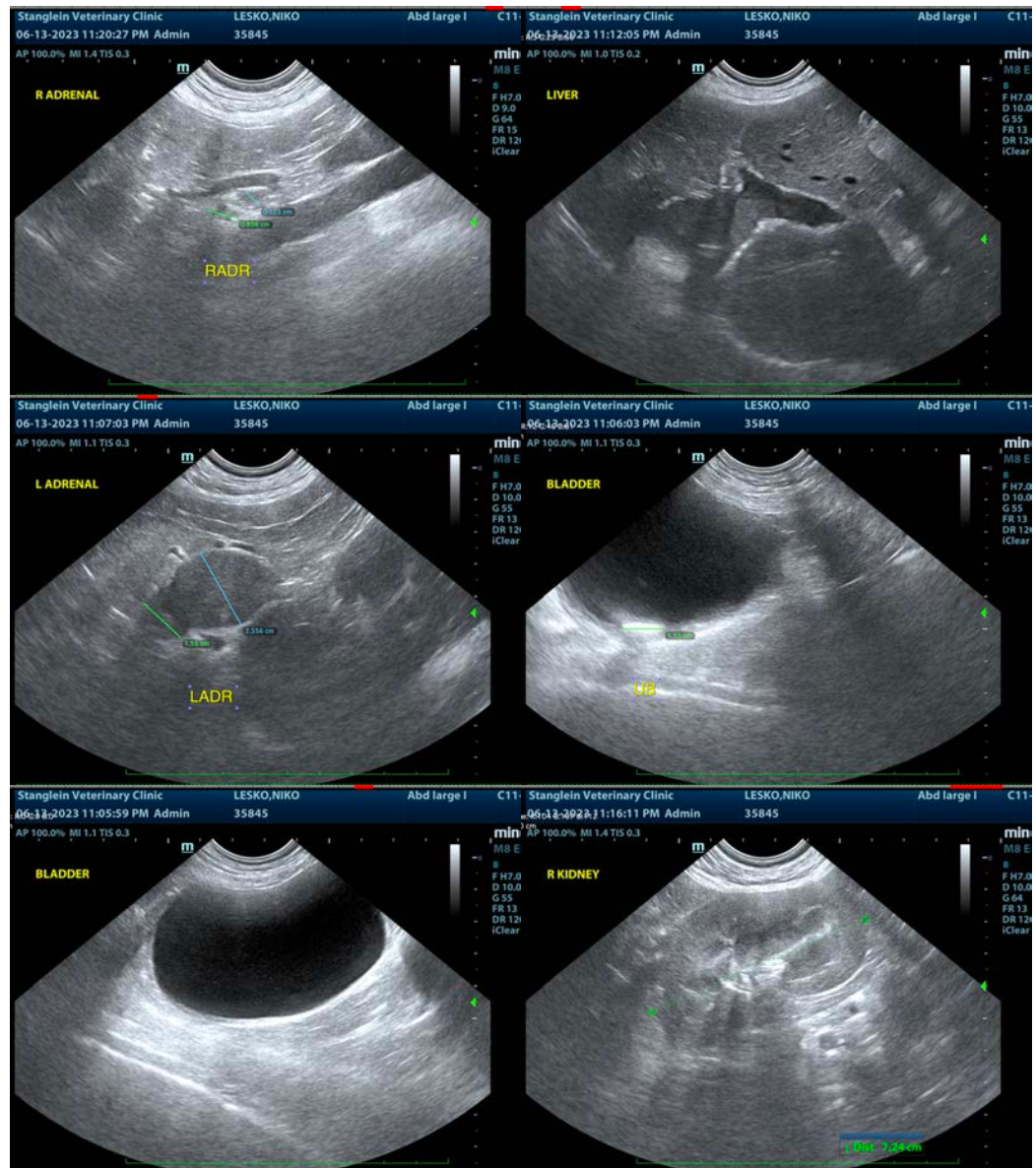
Dr. Nathaniel Stanglein

**INVOICE**

43160

**DATE**

6/14/23





**PATIENT**

Niko Lesko

**SPECIES**

Canine

**BREED**

Golden Retriever

**SEX**

Neutered Male

**AGE**

12 Years 1 Month

**WEIGHT**

80

**INTERPRETED BY**

Beth Johnson, DVM  
DACVIM

**IMAGING PERFORMED BY**

Jessica Green

**HOSPITAL NAME**

Stanglein Vet Clinic

**REFERRING VET**

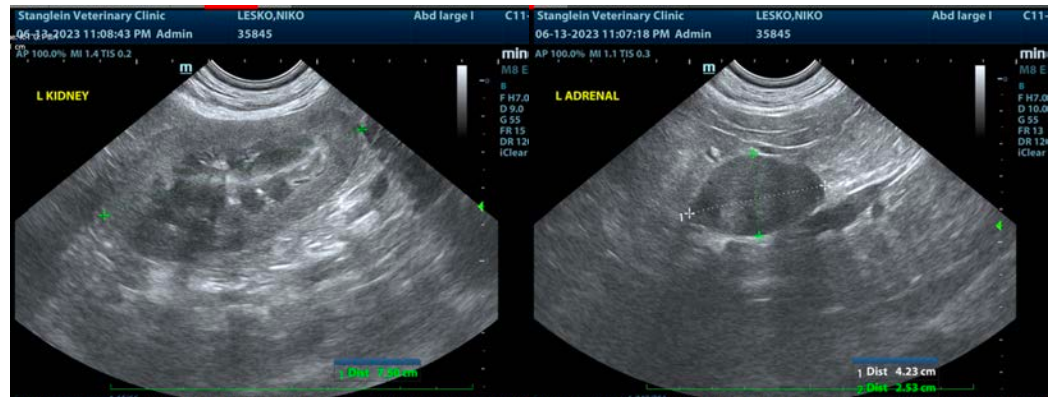
Dr. Nathaniel Stanglein

**INVOICE**

43160

**DATE**

6/14/23



The information and recommendations provided are based on the images presented by the referring veterinarian/sonographer. No evaluation can be communicated regarding pathology that was not visible in the image/video clips provided.

Thank you for this referral. If the clinical or image interpretation does not parallel your findings or if I can be of any further assistance please contact me.

**Beth Johnson, DVM, DACVIM**  
info@sonopath.com