



PATIENT PRESENTING CLINICAL SIGNS

Kyha Brill Grade 3 murmur elevated renal enzymes Current Medications Gabapentin, Spectra

SPECIES ULTRASONOGRAPHIC EXAMINATION OF THE ABDOMEN

Canine

Urinary System

BREED

The urinary bladder is moderately distended with anechoic contents. No masses, inflammatory changes, echogenic sediment or cystoliths are observed. The urinary bladder, trigone and visible pelvic urethra are normal in thickness with a smooth mucosal surface.

Maltese

SEX

The right kidney is normal in size (4.58 cm), shape and echogenicity. It has smooth peripheral margination. There is a normal 1:3 cortex to medulla ratio with appropriate corticomedullary distinction. There is no evidence of pyelectasia, mineral or infarcts observed. A hyperechoic band parallel to the corticomedullary border is present.

Intact Female

AGE

The left kidney is normal in size (4.51 cm), shape and echogenicity. It has smooth peripheral margination. There is a normal 1:3 cortex to medulla ratio with appropriate corticomedullary distinction. There is no evidence of pyelectasia, mineral or infarcts observed. A hyperechoic band parallel to the corticomedullary border is present.

11 Years

WEIGHT

7.1 kg

Adrenal Glands

INTERPRETED BY

Adrenal glands are largely normal in size, shape and contour. Some parenchymal heterogeneity is present without concerning capsular distortion. These changes are likely normal for this age but should be monitored if there is any suspicion of adrenal disease. The right adrenal gland measures 2.1 cm long x 1.35 cm at the cranial pole and 0.71 cm at the caudal pole. The left adrenal gland measures 1.74 cm long x 0.57 cm at the cranial pole and 0.55 cm at the caudal pole.

Beth Johnson, DVM
DACVIM

IMAGING PERFORMED BY

Spleen

The spleen is subjectively normal in size with a normal smooth capsular contour. Parenchyma is appropriately finely textured and homogenous with normal echogenicity relative to surrounding tissue (hyperechoic to liver). No focal nodules or masses are observed. Splenic vasculature appears normal.

Kelly Reschny

HOSPITAL NAME

Liver

Liver is subjectively enlarged with mildly irregular margins. Parenchyma is heterogenous characterized by multiple poorly defined hypoechoic nodules within otherwise hyperechoic liver parenchyma. Visible vasculature and biliary tree appear normal without distension or congestion.

Briarwood AH

REFERRING VET

The gallbladder is non-distended in size. The wall is smooth without visible thickening. Luminal contents are primarily anechoic. There is no evidence of cystic or common bile duct dilation.

Dr. Anderson

INVOICE

Gastrointestinal

43161

The stomach wall is normal in thickness (canine < 0.5 cm and feline < 0.4 cm) and layering. The lumen of the stomach is empty with no evidence of obstruction, foreign material or infiltrative disease. Pyloric outflow tract appears patent.

DATE

6/14/23

The visible small intestines are normal in wall thickness and layering (canine duodenum < 0.5 cm and feline duodenum < 0.4 cm; other < 0.3 cm). Small intestinal motility appears adequate (1-3 contractions per min). The lumen of the small intestine is empty with no evidence of obstruction, foreign material or infiltrative disease.



PATIENT The visible colon is normal in wall thickness (< 0.2 cm) and layering. Contents are consistent with normal formed feces and gas.

Kyha Brill

Pancreas

SPECIES

Canine

The pancreatic parenchyma is appropriately isoechoic to surrounding tissue. Visible capsule is smooth and normal in contour. There is no visible pancreatic duct dilation. There is no evidence of active peripancreatic inflammation.

BREED

Maltese

Free Abdomen

There is no evidence of free peritoneal effusion noted in these images.

SEX

There is no apparent lymphadenopathy noted in these images.

Intact Female

ULTRASONOGRAPHIC FINDINGS

AGE

11 Years

- **Bilateral medullary rim sign** - This finding is of unknown clinical significance and can be a normal variant, often idiopathic. Medullary rim sign can be present with renal disease including FIP, lymphoma, hypercalcemic nephropathy, Leptospirosis, tubular disease, other and should be interpreted in combination with other more specific indications of kidney disease such as isosthenuria, proteinuria, azotemia, etc. This is a common incidental finding in patients with diabetes mellitus.

WEIGHT

7.1 kg

- **Heterogenous Liver** - These changes are most consistent with benign processes such as nodular hyperplasia, steroid (vacuolar) hepatopathy, extramedullary hematopoiesis or possibly chronic inflammatory disease and less commonly infiltrative round cell or metastatic neoplasia.

INTERPRETED BY

Beth Johnson, DVM
DACVIM

- Age related adrenal gland changes

INTERPRETATION OF THE FINDINGS & FURTHER RECOMMENDATIONS

IMAGING PERFORMED BY

Kelly Reschny

Given this patient's reported azotemia as well as the subtle change in the appearance of the kidneys, further evaluation of pre-renal versus renal azotemia and further assessment of proteinuria, etc. is recommended with urinalysis and, if indicated based on urinalysis results, urine culture. If protein is present in an otherwise quiet sediment, protein quantification with a urine protein to creatinine ration is recommended.

HOSPITAL NAME

Briarwood AH

Additionally, if not recently evaluated, a blood pressure is recommended.

REFERRING VET

Dr. Anderson

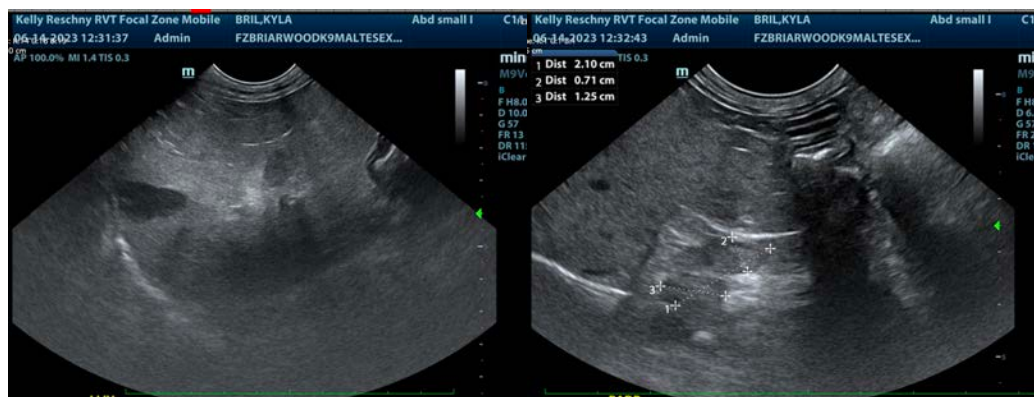Testing for Leptospirosis could be considered, especially if the azotemia is determined to be renal.

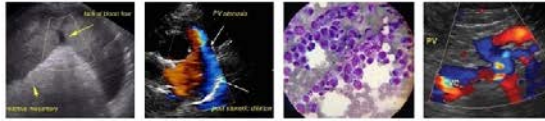
INVOICE

43161

DATE

6/14/23





PATIENT

Kyha Brill

SPECIES

Canine

BREED

Maltese

SEX

Intact Female

AGE

11 Years

WEIGHT

7.1 kg

INTERPRETED BY

Beth Johnson, DVM
DACVIM

IMAGING PERFORMED BY

Kelly Reschny

HOSPITAL NAME

Briarwood AH

REFERRING VET

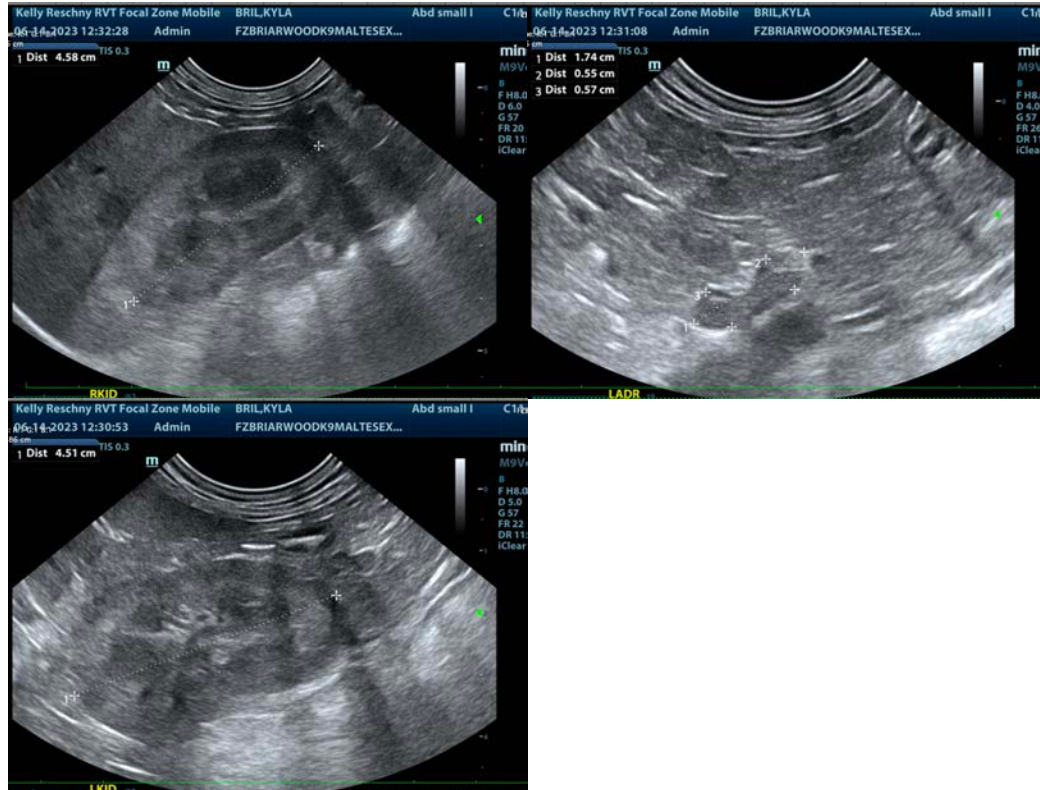
Dr. Anderson

INVOICE

43161

DATE

6/14/23



The information and recommendations provided are based on the images presented by the referring veterinarian/sonographer. No evaluation can be communicated regarding pathology that was not visible in the image/video clips provided.

Thank you for this referral. If the clinical or image interpretation does not parallel your findings or if I can be of any further assistance please contact me.

Beth Johnson, DVM, DACVIM
info@sonopath.com