



**PATIENT PRESENTING CLINICAL SIGNS**

Will Gleason Weight loss with good appetite (used to be 14-16#) No current meds.

**SPECIES** Abnormal PE/Chem/CBC/UA Results: WNL, T4 2.5

Feline

**ULTRASONOGRAPHIC EXAMINATION OF THE ABDOMEN**

**BREED** *Urinary System*

DSH

The urinary bladder is moderately distended with anechoic contents. No masses, inflammatory changes, echogenic sediment or cystoliths are observed. The urinary bladder, trigone and visible pelvic urethra are normal in thickness with a smooth mucosal surface.

**SEX**

Neutered Male

Kidneys are overall normal in size and shape with smooth peripheral margination. A normal 1:3 cortex-to-medulla ratio is maintained. The medulla and cortices are uniform in texture with some mild increased cortical echogenicity and mild loss of corticomedullary distinction, expected in this age patient. There is no evidence of pyelectasia, or mineral observed. A chronic infarct in the right kidney is noted. The left kidney measures 3.78 cm and the right kidney measures 3.79 cm.

**AGE**

17y11m

**WEIGHT** *Adrenal Glands*

10.4#

The right adrenal gland is normal in size (0.2 cm), shape, and contour. Corticomedullary structure is unremarkable. Visible surrounding vasculature appears normal.

**INTERPRETED BY**

Beth Johnson, DVM  
DACVIM

The left adrenal gland is normal in size (0.23 cm), shape, and contour. Corticomedullary structure is unremarkable. Visible surrounding vasculature appears normal.

*Spleen*

**IMAGING PERFORMED BY**

Jessica Miller

The spleen is subjectively normal in size with a normal smooth capsular contour. Parenchyma is appropriately finely textured and homogenous with normal echogenicity relative to surrounding tissue (hyperechoic to liver). No focal nodules or masses are observed. Splenic vasculature appears normal.

**HOSPITAL NAME**

Summit Dog and Cat  
Hospital

*Liver*

The liver is subjectively normal in size with normal smooth curvilinear peripheral contour. Parenchyma is appropriately hypoechoic to the spleen in echogenicity and appropriately mildly coarse and homogenous in echotexture. No focal lesions are observed. Visible vasculature and biliary tree appear normal without distension or congestion.

**REFERRING VET**

Dr. Lepkowski

The gallbladder is non-distended in size. The wall is smooth without visible thickening. Luminal contents are primarily anechoic. There is no evidence of cystic or common bile duct dilation.

**INVOICE**

10253

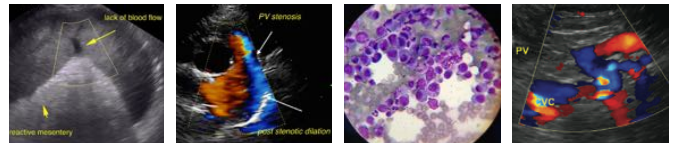
*Gastrointestinal*

**DATE**

6/13/2023

The stomach wall is normal in thickness (canine < 0.5 cm and feline < 0.4 cm) and layering. The lumen of the stomach is empty with no evidence of obstruction or foreign material. Pyloric outflow tract appears patent.

The visible small intestines are normal in wall thickness and layering (canine duodenum < 0.5 cm and feline duodenum < 0.4 cm; other < 0.3 cm). Small intestinal motility appears adequate (1-3 contractions per min). The lumen of the small intestine is empty with no evidence of obstruction or foreign material.



**PATIENT**

Will Gleason

The visible colon is normal in wall thickness (< 0.2 cm) and layering. Contents are consistent with normal formed feces and gas.

**SPECIES**

Feline

**Pancreas**

The pancreatic parenchyma is appropriately isoechoic to surrounding tissue. Visible capsule is smooth and normal in contour. There is no visible pancreatic duct dilation. There is no evidence of active peripancreatic inflammation.

**BREED**

DSH

**Free Abdomen**

There is no evidence of free peritoneal effusion noted in these images.

**SEX**

Neutered Male

There is no apparent lymphadenopathy noted in these images.

**AGE**

17y11m

**ULTRASONOGRAPHIC FINDINGS**

- Age-related kidney changes. Otherwise, this is a relatively unremarkable/normal senior cat abdomen.

**WEIGHT**

10.4#

**INTERPRETATION OF THE FINDINGS & FURTHER RECOMMENDATIONS**

Given this patient reported total T4 at the upper end of normal reference ranges, a Free T4 is recommended for further evaluation of possible hyperthyroidism, as a contributing factor to the weight loss with a normal appetite.

**INTERPRETED BY**

Beth Johnson, DVM  
DACVIM

Additionally, further evaluation of the digestion and absorption is recommended beginning with a gastrointestinal malabsorption panel (including cobalamin, folate, TLI, and PLI) to Texas A&M GI Laboratory is recommended for further evaluation of GI and pancreatic function. While awaiting diagnostic results confirmation of appropriate daily caloric intake is recommended to rule out inadvertent decrease in calories as a result of a diet change, or competitive eating environment in the house etc.

**IMAGING PERFORMED BY**

Jessica Miller

Ultimately, however, pending results further evaluation of the GI tract via biopsies may be necessary as emerging infiltrative gastrointestinal disease can cause clinical signs without overt ultrasound changes.

**HOSPITAL NAME**

Summit Dog and Cat  
Hospital

**REFERRING VET**

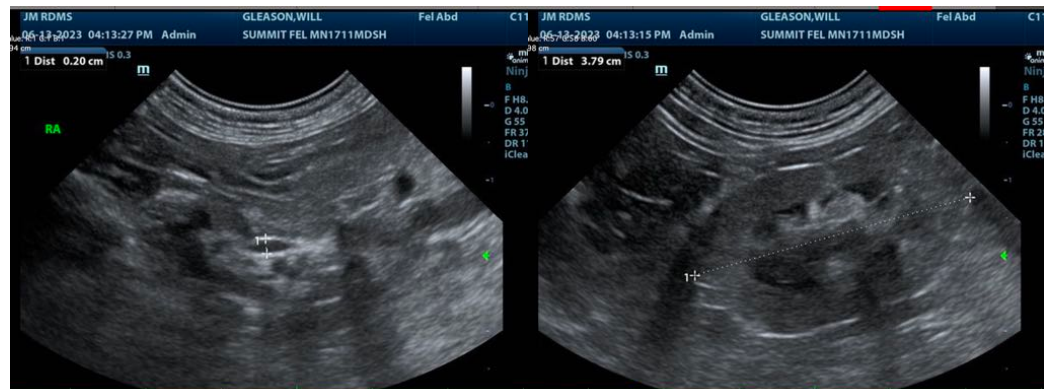
Dr. Lepkowski

**INVOICE**

10253

**DATE**

6/13/2023





**PATIENT**

Will Gleason

**SPECIES**

Feline

**BREED**

DSH

**SEX**

Neutered Male

**AGE**

17y11m

**WEIGHT**

10.4#

**INTERPRETED BY**

Beth Johnson, DVM  
DACVIM

**IMAGING PERFORMED BY**

Jessica Miller

**HOSPITAL NAME**

Summit Dog and Cat  
Hospital

**REFERRING VET**

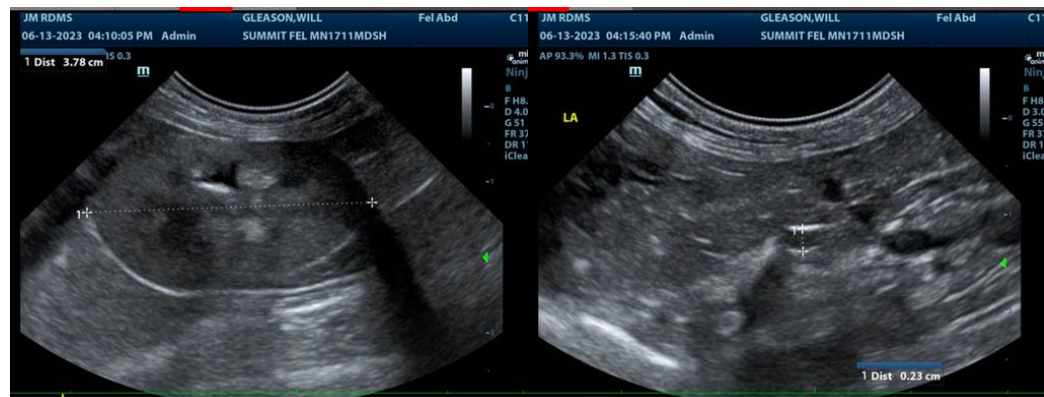
Dr. Lepkowski

**INVOICE**

10253

**DATE**

6/13/2023



The information and recommendations provided are based on the images presented by the referring veterinarian/sonographer. No evaluation can be communicated regarding pathology that was not visible in the image/video clips provided.

Thank you for this referral. If the clinical or image interpretation does not parallel your findings or if I can be of any further assistance, please contact me.

Beth Johnson, DVM, DACVIM  
Info@sonopath.com