

**DATE PRESENTING CLINICAL SIGNS**

6/13/23

Madison came in for vomiting and lethargy on 6/5/23. She has had renal disease since 2014. Her PE revealed weight loss of almost 2# since 8/2022. Her abd was tense so difficult to palpate. An x-ray shows a possibly plump kidney. Her bloodwork revealed a 59% hct. Her renal values weren't significantly elevated. She was treated symptomatically with fluids and anti-nausea meds and is back to normal except a repeat hct (in-house) was 67%. She does appear to have true polycythemia. We are looking to see if she has evidence of a tumor on the kidney (or elsewhere) that might be causing the polythemia.

PATIENT

Madison Violante

SPECIES

Feline

Current Medications: 100ml LRS sq daily, amlodipine 0.625g sid, cerenia 4mg sid, Renal K and AIOH powders
Lab Results: 6/5/23 hct=59%, bun=39, creat=2.2. 6/8/23 hct =67% (in-house) - was not sent out

BREED

DSH

Radiographs: See attached.
Date of Previous IntraPet Ultrasound: No previous.
Sedation: Not required to complete full diagnostic ultrasound.
Stat Report: Not requested.

SEX

Spayed Female

Imaging Performed By: Rachel Brillhart, RDMS.

ULTRASONOGRAPHIC EXAMINATION OF THE ABDOMEN**AGE**

6/8/12

Urinary System

The urinary bladder is moderately distended with anechoic contents. No masses, inflammatory changes, echogenic sediment or cystoliths are observed. The urinary bladder, trigone and visible pelvic urethra are normal in thickness with a smooth mucosal surface.

WEIGHT

11 Pounds

The kidneys are bilaterally enlarged. The left measures 5.07 cm. The right measures 5.03 cm. Overall increased cortical echogenicity noted in both kidneys and disruption of corticomedullary architecture in the cranial pole of the left kidney and the caudal pole of the right kidney as a result of heterogeneous, vascular, primarily hypoechoic nodules. The left cranial pole nodule measures 3.0 cm. The right caudal pole nodule measures 2.3 cm x 3.0 cm. No visible nephroliths noted.

INTERPRETED BYBeth Johnson, DVM
DACVIM**Adrenal Glands**

The right adrenal gland is normal in size (0.45 cm), shape and contour. Corticomedullary structure is unremarkable. Visible surrounding vasculature appears normal.

HOSPITAL NAMECat Sense Feline
Hospital

The left adrenal gland is normal in size (0.39 cm), shape and contour. Corticomedullary structure is unremarkable. Visible surrounding vasculature appears normal.

REFERRING VET

Dr. Sinclair

Spleen

The spleen is subjectively normal in size with a normal smooth capsular contour. Parenchyma is appropriately finely textured and homogenous with normal echogenicity relative to surrounding tissue (hyperechoic to liver). No focal nodules or masses are observed. Splenic vasculature appears normal.

INVOICE

43100

Liver

The liver is subjectively normal in size with normal smooth curvilinear peripheral contour. Parenchyma is appropriately hypoechoic to the spleen in echogenicity and appropriately mildly coarse and homogenous in echotexture. A nodule/mass of mixed echogenicity, primarily hyperechoic in echogenicity but containing multiple cysts of varying size is noted in the left caudal liver, measuring 2.5 cm x 3.2 cm. Visible vasculature and biliary tree appear normal without distension or congestion.

The gallbladder is non-distended in size. The wall is smooth without visible thickening. Luminal contents are primarily anechoic. There is no evidence of cystic or common bile duct dilation.

Gastrointestinal

The visible stomach wall is normal in thickness and layering. The lumen of the stomach is mildly distended with echogenic non-shadowing luminal contents and gas consistent with normal ingesta. There is no evidence of obstruction, foreign material or infiltrative disease. Pyloric outflow tract appears patent.

The visible small intestine demonstrates areas of mildly thick muscularis layer relative to mucosa (disruption of the normal 1:3 muscularis:mucosa ratio). Small intestinal submucosa is slightly irregular, thick and hyperechoic, without evident loss of layering appreciated. The lumen is empty with no evidence of obstruction or foreign material.

The visible colon is normal in wall thickness (< 0.2 cm) and layering. Contents are consistent with normal formed feces and gas.

Pancreas

The observed pancreas appears appropriately isoechoic to surrounding omental fat. The capsule is mildly irregular in shape. Parenchyma is mildly heterogenous and coarse. There is no visible pancreatic duct dilation. There is no evidence of active peripancreatic inflammation.

Free Abdomen

There is no evidence of free peritoneal effusion noted in these images.

There is no apparent lymphadenopathy noted in these images.

ULTRASONOGRAPHIC FINDINGS

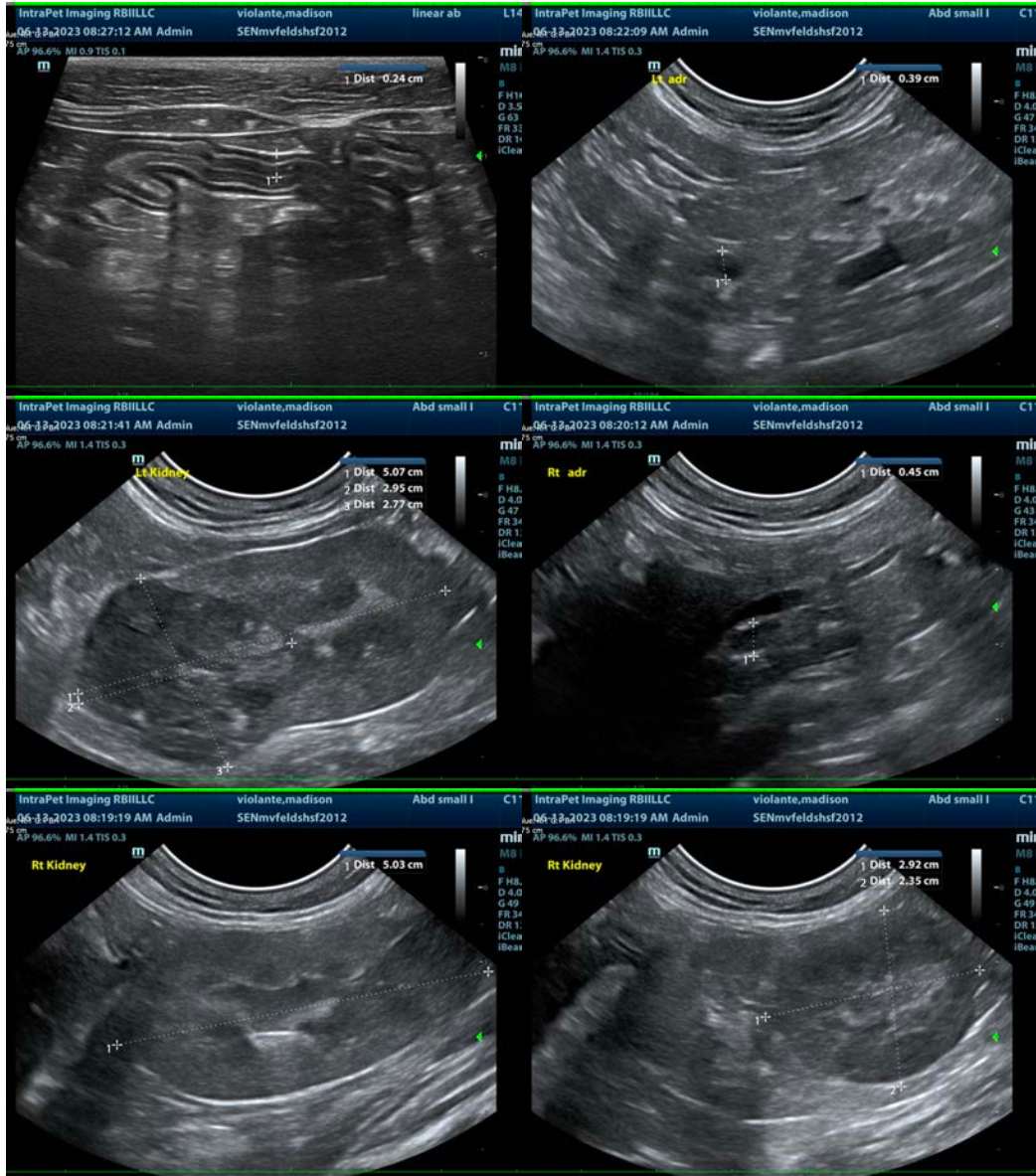
- Bilateral renomegaly with heterogeneous nodules in both kidneys – concerning for infiltrative neoplasia such as renal lymphoma. Other malignant neoplasia, feline infectious peritonitis, renal abscesses, etc. can at times mimic a nodular change, but is less common.
- Feline biliary cystadenoma – In a senior cat, this liver lesion is most consistent with a/multiple benign biliary cystadenoma(s). Malignancy cannot be ruled out but is considered less likely given lack of clinical signs and/or laboratory changes.
- Mild/subtle inflammatory bowel disease (IBD) pattern – Thick muscularis has been reported with infiltrative bowel disease including both benign inflammatory disease as well as infiltrative neoplasia such as lymphoma. No aggressive lymphadenopathy, loss of layering, etc. is noted to make lymphoma more probable, but lymphoma cannot be definitively ruled out without tissue sampling.
- Pancreatic age-related remodeling – Mild irregularities are consistent with benign age-related change. Low-grade smoldering chronic pancreatitis cannot be ruled out and should be suspected in the face of appropriate clinical signs.

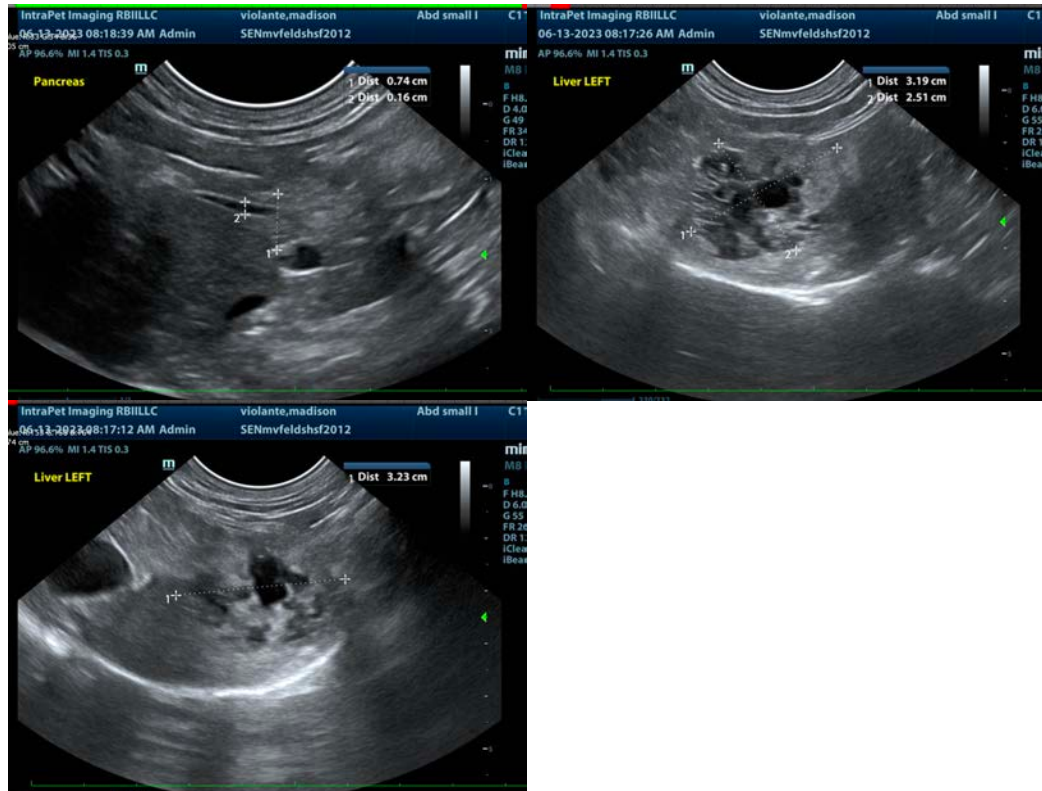
INTERPRETATION OF THE FINDINGS & FURTHER RECOMMENDATIONS

Three view thoracic radiographs are recommended for further assessment of cardio-pulmonary status as well as to further evaluate for any evidence of metastatic disease, if not recently evaluated.

Fine needle aspirates of the bilateral renal nodules are recommended if patient's coagulation status is appropriate. Additionally, given the concurrent weight loss and mild bowel changes:

A gastrointestinal malabsorption panel (including cobalamin, folate, TLI and PLI) to Texas A&M GI Laboratory is recommended for further evaluation of GI and pancreatic function.





The information and recommendations provided are based on the images presented by the referring veterinarian/sonographer. No evaluation can be communicated regarding pathology that was not visible in the image/video clips provided.

Thank you for this referral. If the clinical or image interpretation does not parallel your findings or if I can be of any further assistance please contact me.

Beth Johnson, DVM, DACVIM
info@sonopath.com