



PATIENT PRESENTING CLINICAL SIGNS

Jaxsyn Shepard Presented for decreased appetite. BCS 9/9

SPECIES Abnormal PE/Chem/CBC/UA Results: ABNORMAL Laboratory Findings PCV 26.8%, non regenerative. Globulin 4.4 Rest unremarkable. Current Medications Carafate 0.5g TID, iron/B Vit supplement
Canine Radiographic Findings None

BREED ULTRASONOGRAPHIC EXAMINATION OF THE ABDOMEN

Dachshund X

Urinary System

SEX

The urinary bladder is moderately distended with anechoic contents. No masses, inflammatory changes, echogenic sediment or cystoliths are observed. The urinary bladder, trigone and visible pelvic urethra are normal in thickness with a smooth mucosal surface.

Neutered Male

Prostate is normal in size, echotexture and echogenicity for a neutered male.

AGE

12 Years

Kidneys are overall normal in size and shape with smooth peripheral margination. A normal 1:3 cortex to medulla ratio is maintained. The medulla and cortices are uniform in texture with some mild increased cortical echogenicity and mild loss of corticomedullary distinction, expected in this age patient. Multiple small cortical cysts are noted bilaterally. There is no evidence of pyelectasia, mineral or infarcts observed. The right kidney measures 4.16 cm. The left kidney measured 4.42 cm.

WEIGHT

19.18 Pounds

Adrenal Glands

INTERPRETED BY

Beth Johnson, DVM
DACVIM

The right adrenal gland is primarily normal in size (2.71 cm long x 1.39 cm at the cranial pole and 0.41 cm at the caudal pole) with a slightly rounded/swollen cranial pole. Otherwise, shape and architecture are normal. Echogenicity and echotexture are normal. Visible surrounding vasculature appears normal.

The left adrenal gland is normal in size (1.93 cm long x 0.47 cm at the cranial pole and 0.48 cm at the caudal pole), shape and contour. Corticomedullary structure is unremarkable. Visible surrounding vasculature appears normal.

IMAGING PERFORMED BY

Sara Hansen

Spleen

The spleen is subjectively normal in size with a normal smooth capsular contour. Parenchyma is appropriately finely textured and homogenous with normal echogenicity relative to surrounding tissue (hyperechoic to liver). A 0.50 cm x 0.70 cm hypo- to anechoic non-capsule disrupting nodule is noted near the caudal aspect of the spleen. Splenic vasculature appears normal.

HOSPITAL NAME

Cottage Grove Vet
Hospital

Liver

REFERRING VET

Dr. Damewood

The liver is subjectively normal in size with normal smooth curvilinear peripheral contour. Parenchyma is appropriately hypoechoic to the spleen in echogenicity and appropriately mildly coarse and homogenous in echotexture. No focal lesions are observed. Visible vasculature and biliary tree appear normal without distension or congestion.

INVOICE

43106

The gallbladder is non-distended in size. The wall is smooth without visible thickening. Luminal contents are primarily anechoic. There is no evidence of cystic or common bile duct dilation.

DATE

6/13/23



PATIENT *Gastrointestinal*

Jaxsyn Shepard The visible stomach wall is normal in thickness and layering. The lumen of the stomach is mildly distended with echogenic non-shadowing luminal contents and gas consistent with normal ingesta. There is no evidence of obstruction, foreign material or infiltrative disease. Pyloric outflow tract appears patent.

SPECIES

Canine

BREED

Dachshund X

SEX

Neutered Male

AGE

12 Years

WEIGHT

19.18 Pounds

The visible small intestines are normal in wall thickness and layering. Subtle hyperechoic mucosal fogging or speckling is noted. Small intestinal motility appears adequate (1-3 contractions per min). The lumen is empty with no evidence of obstruction or foreign material.

The visible colon is normal in wall thickness (< 0.2 cm) and layering. Contents are consistent with normal formed feces and gas.

Pancreas

The pancreatic parenchyma is appropriately isoechoic to surrounding tissue. Visible capsule is smooth and normal in contour. There is no visible pancreatic duct dilation. There is no evidence of active peripancreatic inflammation.

Free Abdomen

There is no evidence of free peritoneal effusion noted in these images.

There is no apparent lymphadenopathy noted in these images.

INTERPRETED BY

Beth Johnson, DVM
DACVIM

PRIMARY FINDINGS

- **Subtle/mild mucosal speckling** – Mucosal speckling is often present with inflammatory bowel disease (IBD). It is not specific for type or severity of disease. Mild speckling change can occur as a normal patient variant in the post-prandial state.
- **Hypo to anechoic splenic nodule** – likely represents a benign lesion such as a cyst, hematoma, nodular hyperplasia, extramedullary hematopoiesis, etc., however while considered less likely, infiltrative neoplasia can mimic benign lesions, and cannot be ruled out.
- The mild right adrenomegaly is of unknown clinical significance and may be normal patient variant or an incidental finding. However, early or emerging hyperadrenocorticism cannot be definitively ruled out. This finding/hyperadrenocorticism should only be pursued if clinical signs of hyperadrenocorticism are present in an otherwise clinically healthy animal.

IMAGING PERFORMED BY

Sara Hansen

SECONDARY FINDINGS

- Age related kidney changes with bilateral cortical cysts

HOSPITAL NAME

Cottage Grove Vet
Hospital

REFERRING VET

Dr. Damewood

INTERPRETATION OF THE FINDINGS & FURTHER RECOMMENDATIONS

INVOICE

43106

DATE

6/13/23

Differentials for this patient's non-regenerative anemia include either early hemorrhage or hemolysis, neither of which can be definitively ruled out via this ultrasound, slow, chronic gastrointestinal blood loss, chronic kidney disease, bone marrow disease, or anemia of other chronic disease, etc. Close inspection of this patient's stool should be performed to look for evidence of a slow or chronic GI bleed, in which case further diagnostic recommendations would include a fecal exam, as well as:



PATIENT

Jaxsyn Shepard

A baseline cortisol is recommended. If baseline cortisol is less than 2, a full ACTH stimulation test is recommended to rule out hypoadrenocorticism.

SPECIES

Canine

A gastrointestinal malabsorption panel (including cobalamin, folate, TLI and PLI) to Texas A&M GI Laboratory is recommended for further evaluation of GI and pancreatic function.

BREED

Dachshund X

Without a GI bleed, next diagnostic recommendations include further workup for possible autoimmune disease, especially if the anemia is new and could be in the early stages of regeneration up to and including possible bone marrow cytology if the anemia remains non-regenerative.

SEX

Neutered Male

Three view thoracic radiographs are recommended for further assessment of cardio-pulmonary status as well as to further evaluate for any evidence of metastatic disease, if not recently evaluated.

AGE

12 Years

Finally, while the appearance of the spleen trends towards benign in appearance, a fine needle aspirate could be considered if patient's coagulation status is appropriate, especially if a diagnosis/underlying cause, etc. is not determined via the above recommended workup.

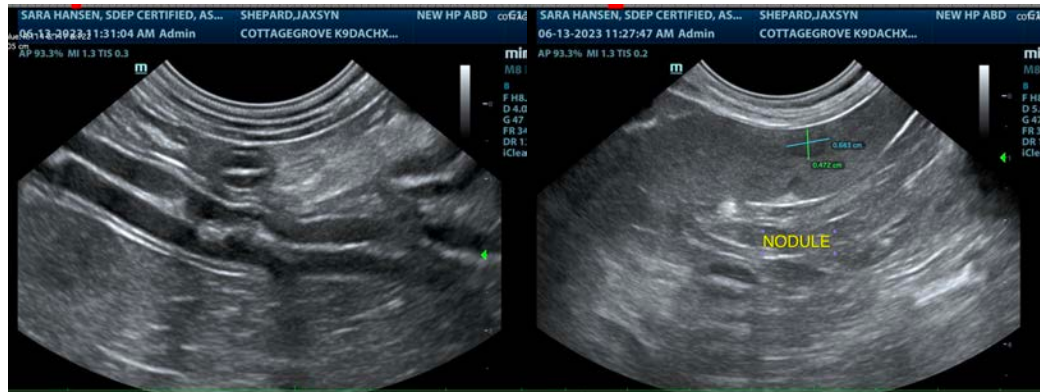
WEIGHT

19.18 Pounds

In the meantime, empirical deworming with 5-day course of Panacur should be considered.

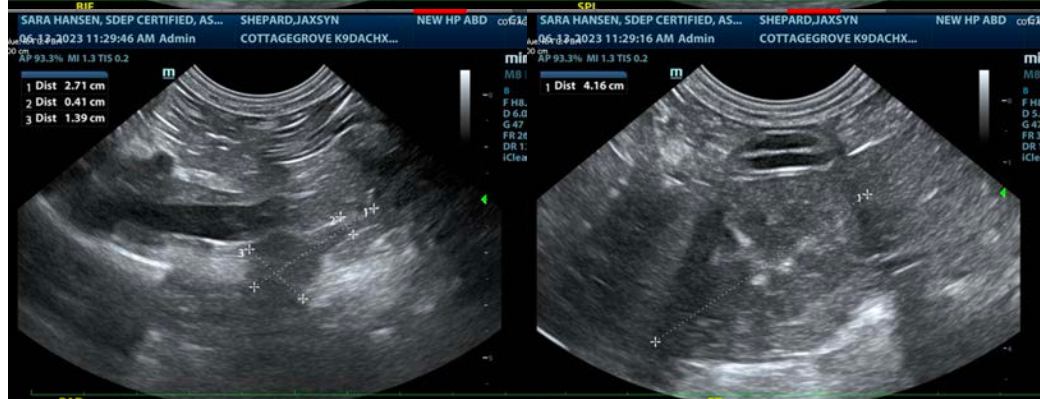
INTERPRETED BY

Beth Johnson, DVM
DACVIM



IMAGING PERFORMED BY

Sara Hansen



HOSPITAL NAME

Cottage Grove Vet
Hospital

REFERRING VET

Dr. Damewood

INVOICE

43106

DATE

6/13/23



PATIENT

Jaxsyn Shepard

SPECIES

Canine

BREED

Dachshund X

SEX

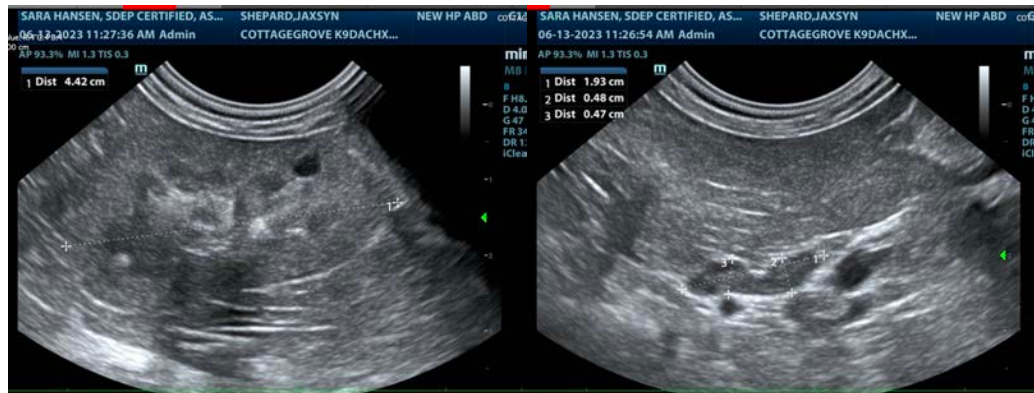
Neutered Male

AGE

12 Years

WEIGHT

19.18 Pounds



The information and recommendations provided are based on the images presented by the referring veterinarian/sonographer. No evaluation can be communicated regarding pathology that was not visible in the image/video clips provided.

Thank you for this referral. If the clinical or image interpretation does not parallel your findings or if I can be of any further assistance please contact me.

Beth Johnson, DVM, DACVIM
info@sonopath.com

INTERPRETED BY

Beth Johnson, DVM
DACVIM

IMAGING PERFORMED BY

Sara Hansen

HOSPITAL NAME

Cottage Grove Vet
Hospital

REFERRING VET

Dr. Damewood

INVOICE

43106

DATE

6/13/23