

**DATE**

6/13/22

PRESENTING CLINICAL SIGNS

Two episodes of dripping blood-tinged urine from penis - no UTI signs (mid April and mid May 2022) Resolves with Enrofloxacin 136mg 2 PO BID. NSF PE - In good condition, testicles palpate WNL, cannot palpate prostate rectally, penis NSF, Mass in abd

PATIENT

Sky Kammer

Current Medications: Enrofloxacin 136mg 2 PO BID.

Lab Results: 5/27/22 CBC/Chem WNL except plate 135K (148-484). 5/20/22 USG 1.050, ph 7.0, increased WBC + RBC

SPECIES

Canine

Radiographs: No radioopaque uroliths in bladder or urethra. R cranial to mid abd mass displacing intestines. Date of Previous IntraPet Ultrasound: No previous.

Sedation: Not required to complete full diagnostic ultrasound.

Stat Report: Not requested.

Imaging Performed By: Rachel Brillhart, RDMS.

BREED

German Shepherd

ULTRASONOGRAPHIC EXAMINATION OF THE ABDOMEN**Urinary System****SEX**

Intact male

Urinary bladder is moderately distended with anechoic contents. It has normal uniform wall thickness (< 0.2 cm). No masses or cystoliths are observed.

AGE

2/1/17

Prostate is symmetrically enlarged with smooth margins that are well differentiated from surrounding tissue. Normal bilobed shape is maintained. Parenchyma is diffusely hyperechoic. Several small anechoic cysts are noted. No mineral is noted. The prostate measures 5.0 cm wide.

WEIGHT

97 lbs

Left kidney is normal in size (7.38 cm), shape and echogenicity. It has smooth peripheral margination and appropriate corticomedullary distinction. There is no pyelectasia noted. No mineral is observed.

Right kidney is normal in size (7.09 cm), shape and echogenicity. It has smooth peripheral margination and appropriate corticomedullary distinction. There is no pyelectasia noted. No mineral is observed.

INTERPRETED BYBeth Johnson, DVM
DACVIM**Adrenal Glands**

Left adrenal gland is normal in size (3.52 cm long, 0.69 cm at cranial pole and 0.67 cm at caudal pole), shape and contour. Corticomedullary structure is unremarkable.

HOSPITAL NAME

Jacksonville VH

Right adrenal gland is normal in size (3.6 cm long, 1.7 cm at cranial pole and 0.54 cm at caudal pole), shape and contour. Corticomedullary structure is unremarkable.

REFERRING VET

Dr. Thai

Spleen

Spleen is subjectively enlarged in size with rounded margins but intact capsule. Parenchyma is homogeneously coarse/mottled in echotexture and normal to hypoechoic in echogenicity. No focal nodules or masses are observed. Splenic vasculature appears normal.

INVOICE

30979

Liver

Liver is subjectively normal in size. Margins are sharp and smooth. It has normal homogenous echotexture and normal echogenicity. No focal lesions are observed. Visible vasculature appears normal. GB is moderately distended with anechoic bile and gravity dependent echogenic sediment. The wall is smooth without visible thickening. There is no evidence of cystic or CBD dilation. There is no evidence of effusion or inflammation.

Gastrointestinal

The visible gastric wall is normal in thickness (canine < 0.5 cm and feline < 0.4 cm). The lumen of the stomach is mildly distended with very echogenic reverberation artifact from intraluminal gas. There is no evidence of obstruction, foreign material or infiltrative disease; however, complete visualization of far wall is partially inhibited by gas. Pyloric outflow tract appears patent.

The small intestines are normal in wall thickness and layering. Small intestinal motility appears adequate (1-3 contractions per min). There are no luminal contents noted within small intestines.

Colon is normal in wall thickness (< 0.2 cm) and layering.

Pancreas

Pancreas has normal homogenous echotexture and is normal in echogenicity and smooth margination. There is no evidence of peripancreatic inflammation.

Free Abdomen

Mild reactive medial iliac lymphadenopathy versus normal size for a large dog (0.47 cm). No appreciable free fluid including pericardial effusion was noted.

The testicles and penis are unremarkable.

ULTRASONOGRAPHIC FINDINGS

PRIMARY FINDINGS:

- Benign Prostatic Hyperplasia with cysts – Prostatic findings are most consistent with Benign Prostatic Hyperplasia and concurrent benign prostatic cysts.
- Coarse splenomegaly – can be associated with congestion caused by sedation (if sedated) but can also be associated with diffuse infiltrative disease. Both benign conditions such as extramedullary hematopoiesis, lymphoid hyperplasia, amyloidosis (leave amyloidosis out if canine) as well as infiltrative neoplastic diseases such as round cell neoplasia should be considered.

SECONDARY FINDINGS:

- Gallbladder debris - Cholecystic debris is of unknown clinical significance. It can be seen with biliary stasis from fasting or illness. Cholecystic debris is not necessarily related to hepatobiliary disease. Echogenic bile is most commonly an incidental finding in dogs and should be interpreted in combination with clinical signs such as nausea, inappetence, cranial abdominal discomfort and/or laboratory changes such as increased ALP and/or increased Tbili.

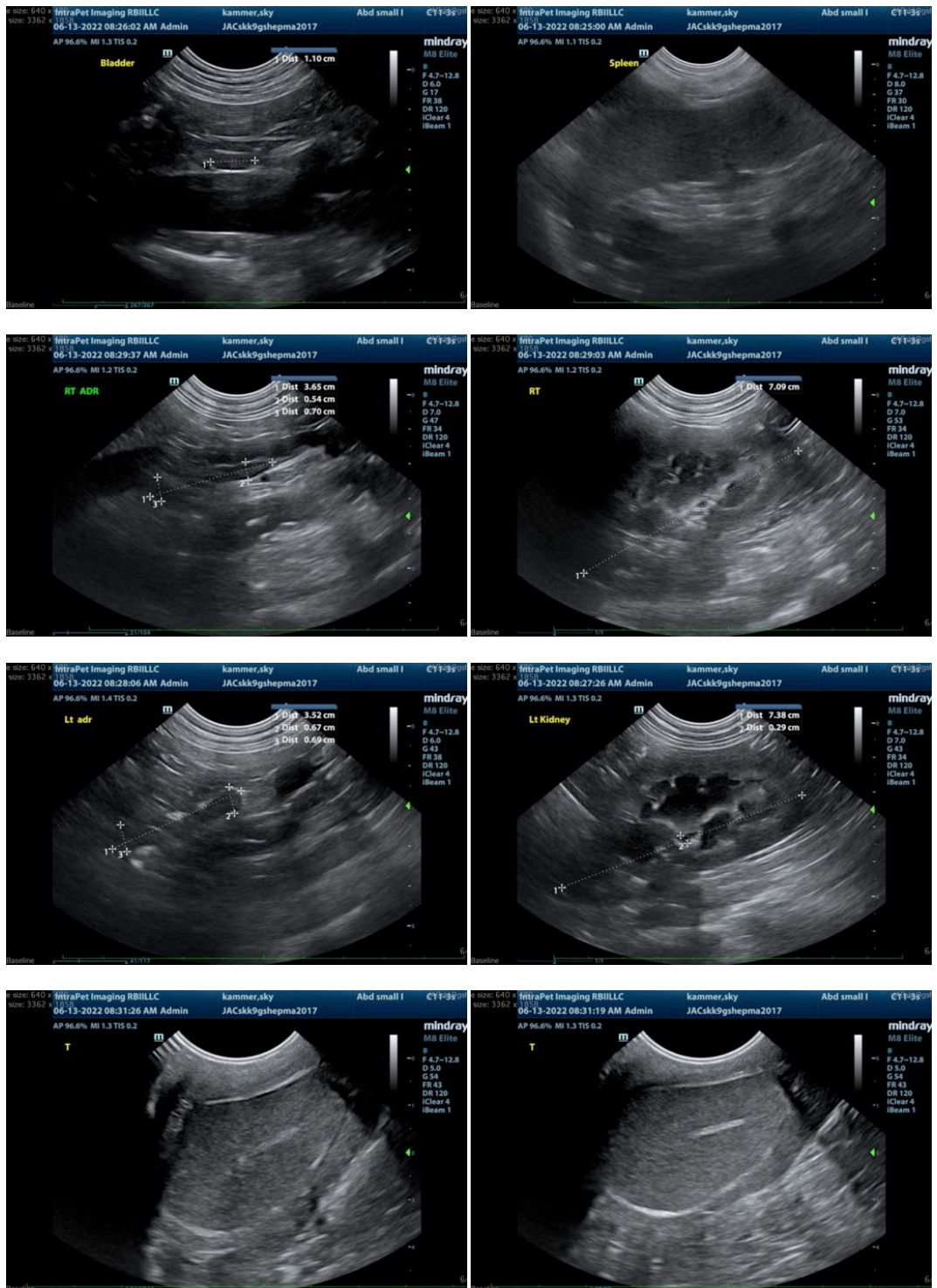
INTERPRETATION OF THE FINDINGS & FURTHER RECOMMENDATIONS

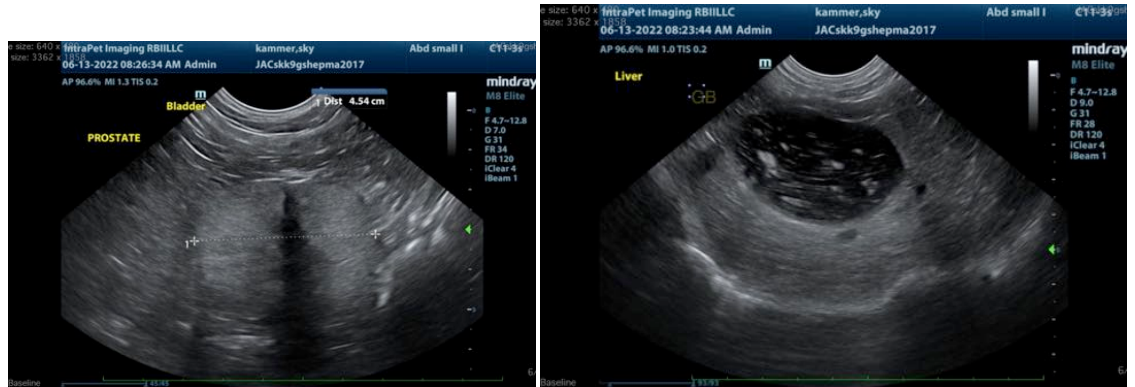
The mass reportedly visualized radiographically is not visible in these images. Splenomegaly is considered a normal breed variation combined with sedation if the patient was sedated for the radiographs or ultrasound.

Recommendations include:

1. Urine culture is recommended. Given the improvement with Baytril waiting at least 2 weeks off of Baytril before culturing the urine is recommended, if that has not already been done. Ideally this would be followed by neutering as the chronic intermittent hematuria if not attributable to a urinary tract infection is likely

secondary to benign prostatic hyperplasia.





The information and recommendations provided are based on the images presented by the referring veterinarian. No evaluation can be communicated regarding pathology that was not visible in the image/video clips provided.

Thank you for this referral. If the clinical or image interpretation does not parallel your findings or if I can be of any further assistance please contact me.

Beth Johnson, DVM DACVIM

Beth.Johnson@SonoPath.com