

PATIENT PRESENTING CLINICAL SIGNS

Lily Kaufman Not eating breakfast past few weeks and reluctantly eats dinner, lethargic. On Hills I/D low fat. Mild ALT elevation and proteinuria. O giving 5mg famotidine BID.
Abnormal PE/Chem/CBC/UA Results: 6/11/22 CBC: WNL CHEM: ALT 256, Chol 363, TG 325, PSL 202 T4: 3.8 H U/A: 1.048, 2+ protein, amorphous phosphate crystals 2/22/22 CBC: WNL CHEM: Chol 329, PSL 150 T4: WNL U/A: 1.051, 2+ protein, amorphous crystals 9/22/21 CBC: WNL CHEM: ALT 128, Chol 369, TG 295 T4: WNL U/A: 1.048, clear sediment 8/20/21 CBC: Eosinophilia 2128 CHEM: Alb 4.6, AST 170, ALT 172, Mg 2.7, Chol 340, TG 475, PSL 189, CPK 1257 T4: WNL U/A: PPD

BREED

Miniature Schnauzer

ULTRASONOGRAPHIC EXAMINATION OF THE ABDOMEN

Urinary System

SEX

Spayed Female

Urinary bladder is moderately distended with anechoic contents. It has normal uniform wall thickness (< 0.2 cm). No masses or cystoliths are observed.

AGE

10 years

Left kidney is normal in size and shape with smooth peripheral margination. A normal 1:3 cortex to medulla ratio is maintained. The medulla and cortices are uniform in texture with some mild increased echogenicity and mild loss of corticomedullary distinction. There is no evidence of pyelectasia, mineral or infarcts observed. The left kidney measured 4.57 cm.

WEIGHT

21 lbs

Right kidney is normal in size and shape with smooth peripheral margination. A normal 1:3 cortex to medulla ratio is maintained. The medulla and cortices are uniform in texture with some mild increased echogenicity and mild loss of corticomedullary distinction. There is no evidence of pyelectasia, mineral or infarcts observed. The right kidney measured 4.57 cm.

INTERPRETED BY

Beth Johnson, DVM
DACVIM

Adrenal Glands

Left adrenal gland is subjectively mildly small to normal in size (1.15 cm long, 0.38 cm at cranial pole and 0.4 cm at caudal pole), shape and contour. Corticomedullary structure is unremarkable.

IMAGING PERFORMED BY

Dr. Cassels-Conway

Right adrenal gland is normal in size (1.19 cm long, 0.48 cm at cranial pole and 0.38 cm at caudal pole), shape and contour. Corticomedullary structure is unremarkable.

HOSPITAL NAME

Central Broward AH

Spleen

Spleen is subjectively normal in size with normal smooth margins. Parenchyma is normal in echogenicity and echotexture. No focal nodules or masses are observed. Splenic vasculature appears normal.

REFERRING VET

Dr. Cassels Conway

Liver

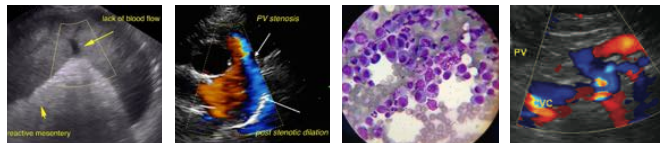
Liver is subjectively enlarged. Margins are smooth but round. It has a normal homogenous echotexture. Parenchyma is diffusely hyperechoic characterized by less prominent than normal portal vein walls and increased echogenicity relative to the spleen. No focal lesions are observed. Visible vasculature and biliary tree appear normal without distension or congestion. GB is moderately distended with anechoic bile and gravity dependent echogenic sediment. The wall is smooth without visible thickening. There is no evidence of cystic or CBD dilation. There is no evidence of effusion or inflammation.

INVOICE

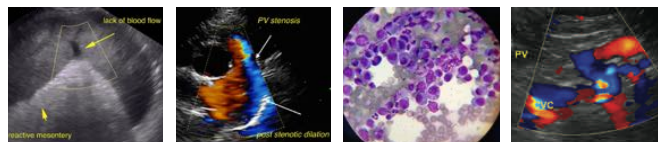
30986

DATE

6/13/22



PATIENT	Gastrointestinal
Lily Kaufman	The visible gastric wall is normal in thickness (canine < 0.5 cm and feline < 0.4 cm). The stomach lumen is mildly distended with echogenic non-shadowing luminal contents and gas consistent with normal ingesta. There is no evidence of obstruction, foreign material or infiltrative disease. Pyloric outflow tract appears patent.
SPECIES	
Canine	The small intestines are normal in wall thickness and layering. Small intestinal motility appears adequate (1-3 contractions per min). There are no luminal contents noted within small intestines.
BREED	Colon is normal in wall thickness (< 0.2 cm) and layering.
Miniature Schnauzer	
SEX	Pancreas
Spayed Female	Pancreas has normal homogenous echotexture and is normal in echogenicity and smooth margination. There is no evidence of peripancreatic inflammation.
AGE	Free Abdomen
10 years	Lymph nodes are normal with no observed enlargement. No free fluid is appreciated in these images.
WEIGHT	ULTRASONOGRAPHIC FINDINGS
21 lbs	PRIMARY FINDINGS:
INTERPRETED BY	Hyperechoic hepatomegaly– most consistent with benign steroid (endocrine) hepatopathy or reactive or idiopathic hepatopathy. Infiltrative neoplasia such as round cell neoplasia is also possible, but considered less likely.
Beth Johnson, DVM DACVIM	Gallbladder debris - Cholecystic debris is of unknown clinical significance. It can be seen with biliary stasis from fasting or illness. Cholecystic debris is not necessarily related to hepatobiliary disease. Echogenic bile is most commonly an incidental finding in dogs and should be interpreted in combination with clinical signs such as nausea, inappetence, cranial abdominal discomfort and/or laboratory changes such as increased ALP and/or increased Tbili.
IMAGING PERFORMED BY	SECONDARY FINDINGS:
Dr. Cassels-Conway	Age related kidney changes – This finding is expected/consistent with age-related mild degenerative disease and should be interpreted clinically in combination with laboratory changes.
HOSPITAL NAME	INTERPRETATION OF THE FINDINGS & FURTHER RECOMMENDATIONS
Central Broward AH	
REFERRING VET	
Dr. Cassels Conway	
INVOICE	Given the proteinuria and high ALT I recommend to test for Leptospirosis if not recently evaluated. A urine protein to creatinine ratio is recommended to further quantify the proteinuria is also recommended as well as a blood pressure if not recently evaluated.
30986	
DATE	Given the gastrointestinal signs combined with the historically high eosinophils a baseline cortisol is recommended to rule out hypoadrenocorticism. If the baseline cortisol is less than 2 a full follow-up ACTH stimulation test is recommended.
6/13/22	



PATIENT

Lily Kaufman

Gastrointestinal malabsorption panel including TLI, PLI, folate and cobalamin to Texas A&M GI laboratory is recommended for further assessment of gastrointestinal health.

SPECIES

Canine

In the meantime, empirical deworming with a 5 day course of Panacur as well as an empirical course of antibiotics could be tried with monitoring of the ALT for improvement.

BREED

Miniature Schnauzer

SEX

Spayed Female

AGE

10 years

WEIGHT

21 lbs

INTERPRETED BY

Beth Johnson, DVM
DACVIM

IMAGING PERFORMED BY

Dr. Cassels-Conway

HOSPITAL NAME

Central Broward AH

REFERRING VET

Dr. Cassels Conway

INVOICE

30986

DATE

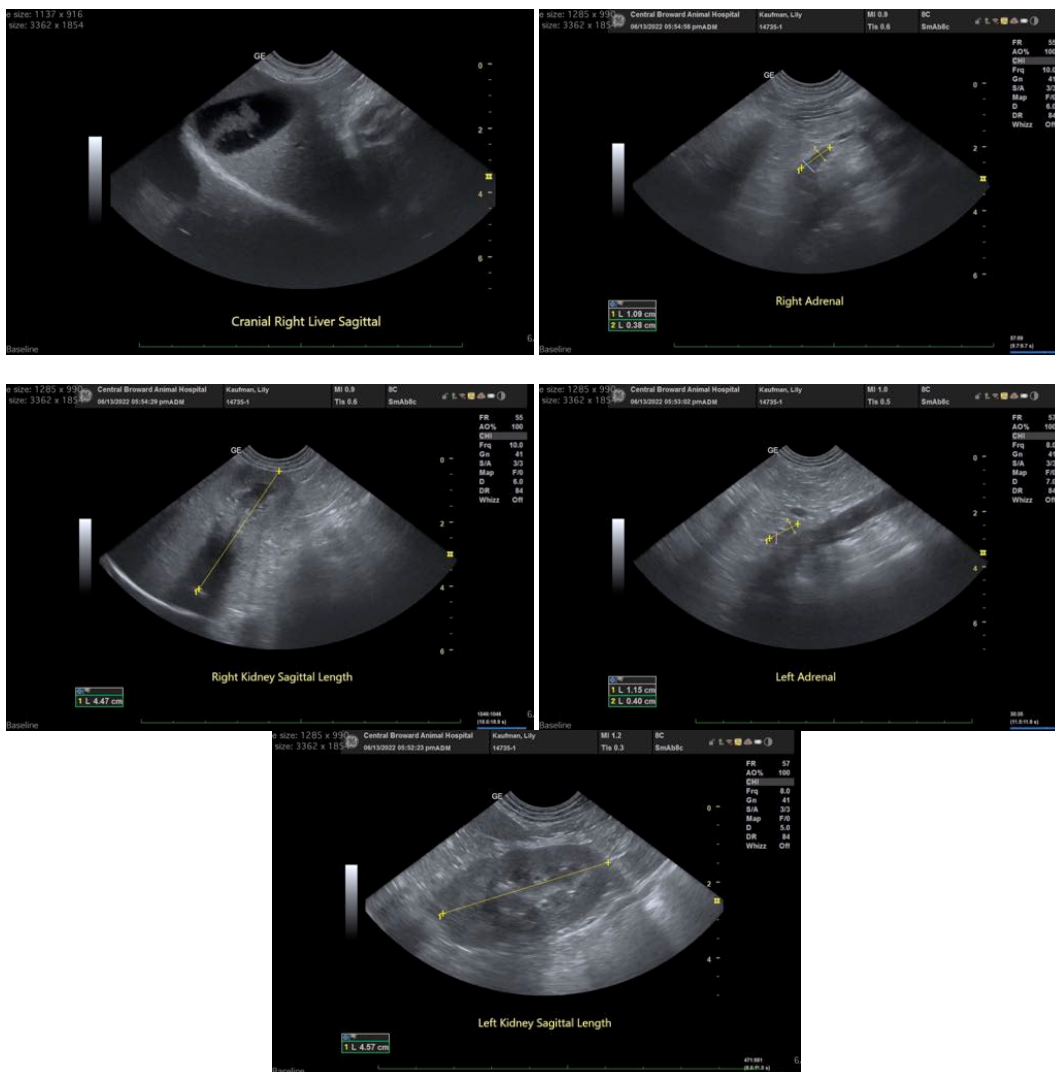
6/13/22

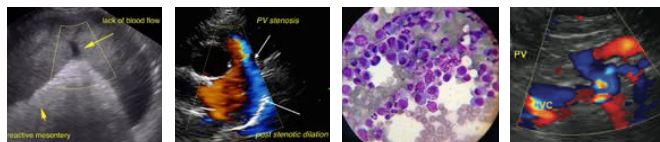
The information and recommendations provided are based on the images presented by the referring veterinarian/sonographer. No evaluation can be communicated regarding pathology that was not visible in the image/video clips provided.

Thank you for this referral. If the clinical or image interpretation does not parallel your findings or if I can be of any further assistance please contact me.

Beth Johnson, DVM DACVIM

Beth.Johnson@SonoPath.com





PATIENT

Lily Kaufman

SPECIES

Canine

BREED

Miniature Schnauzer

SEX

Spayed Female

AGE

10 years

WEIGHT

21 lbs

INTERPRETED BY

Beth Johnson, DVM
DACVIM

**IMAGING
PERFORMED BY**

Dr. Cassels-Conway

HOSPITAL NAME

Central Broward AH

REFERRING VET

Dr. Cassels Conway

INVOICE

30986

DATE

6/13/22