

**DATE PRESENTING CLINICAL SIGNS**

5/9/23 Recently identified abnormal alkaline phosphatase; Client ok'd proceeding directly to AUS. Heart murmur grade II/VI. No coughing or lethargy reported by client.

PATIENT

Jagar Merklinger

Current Medications: Minimal use of 20 mg Galliprant SID: 3/14/22 14#, 4/12/22 30#, 1/23/23 30#, 4/13/23 - 7#. Denamarin Advanced small dog started 2/6/23 and currently being administered

Lab Results: 3/9/22: ALT normal 78 U/L, ALKPPOS 177 U/L, Remainder wnl. 2/1/2023: ALT normal 66 U/L, ALKPPOS 555 U/L 5/1/23: ALT 124 U/L, ALKPPOS 742 U/L

SPECIES

Canine

Date of Previous IntraPet Ultrasound: No previous.

Sedation: Not required to complete full diagnostic ultrasound.

Stat Report: Not requested.

BREED

Shetland Sheepdog

Imaging Performed By: Rachel Brillhart, RDMS.

ULTRASONOGRAPHIC EXAMINATION OF THE ABDOMEN**SEX**

Spayed Female

Urinary System

The urinary bladder is moderately distended with anechoic contents. No masses, inflammatory changes, echogenic sediment or cystoliths are observed. The urinary bladder, trigone and visible pelvic urethra are normal in thickness with a smooth mucosal surface.

AGE

1/20/12

The right kidney is normal in size (4.85 cm), shape and echogenicity. It has smooth peripheral margination. There is a normal 1:3 cortex to medulla ratio with appropriate corticomedullary distinction. There is no evidence of pyelectasia, mineral or infarcts observed.

WEIGHT

26 Pounds

The left kidney is normal in size (5.10 cm), shape and echogenicity. It has smooth peripheral margination. There is a normal 1:3 cortex to medulla ratio with appropriate corticomedullary distinction. There is no evidence of pyelectasia, mineral or infarcts observed.

INTERPRETED BY

Beth Johnson, DVM
DACVIM

Adrenal Glands

The right adrenal gland is normal in size (2.23 cm long x 0.70 cm at the cranial pole and 0.67 cm at the caudal pole), shape and contour. Corticomedullary structure is unremarkable. Visible surrounding vasculature appears normal.

HOSPITAL NAME

Swan Creek VC

The left adrenal gland is enlarged, with mild heterogenous parenchymal changes and mineral foci, primarily affecting the caudal pole. The left adrenal gland measures 3.52 cm long x 1.26 cm at the cranial pole and 2.24 cm at the caudal pole. Swollen capsular expansion is noted without evident capsular escape or vascular invasion.

REFERRING VET

Dr. Holloway

Spleen

The spleen is subjectively normal in size with a normal smooth capsular contour. Parenchyma is appropriately finely textured and homogenous with normal echogenicity relative to surrounding tissue (hyperechoic to liver). No focal nodules or masses are observed. Splenic vasculature appears normal.

INVOICE

47248

Liver

The liver is subjectively normal in size with normal smooth curvilinear peripheral contour. Parenchyma is appropriately hypoechoic to the spleen in echogenicity and appropriately mildly coarse and homogenous in echotexture. No focal lesions are observed. Visible vasculature and biliary tree appear normal without distension or congestion.

Gallbladder is mildly overdistended with a moderate amount of non-dependent, mildly aggregated/inspissated sludge. Hypo to anechoic cystic areas are noted between the gallbladder sludge and

luminal wall. The wall is otherwise smooth without visible thickening. There is no evidence of cystic or CBD dilation. There is no evidence of effusion.

Gastrointestinal

The visible stomach wall is normal in thickness and layering. The lumen of the stomach is mildly distended with echogenic non-shadowing luminal contents and gas consistent with normal ingesta. There is no evidence of obstruction, foreign material or infiltrative disease. Pyloric outflow tract appears patent.

The visible small intestines are normal in wall thickness and layering (canine duodenum < 0.5 cm and feline duodenum < 0.4 cm; other < 0.3 cm). Small intestinal motility appears adequate (1-3 contractions per min). The lumen of the small intestine is empty with no evidence of obstruction, foreign material or infiltrative disease.

The visible colon is normal in wall thickness (< 0.2 cm) and layering. Contents are consistent with normal formed feces and gas.

Pancreas

The pancreatic parenchyma is appropriately isoechoic to surrounding tissue. Visible capsule is smooth and normal in contour. There is no visible pancreatic duct dilation. There is no evidence of active peripancreatic inflammation.

Free Abdomen

There is no evidence of free peritoneal effusion noted in these images.

There is no apparent lymphadenopathy noted in these images.

ULTRASONOGRAPHIC FINDINGS

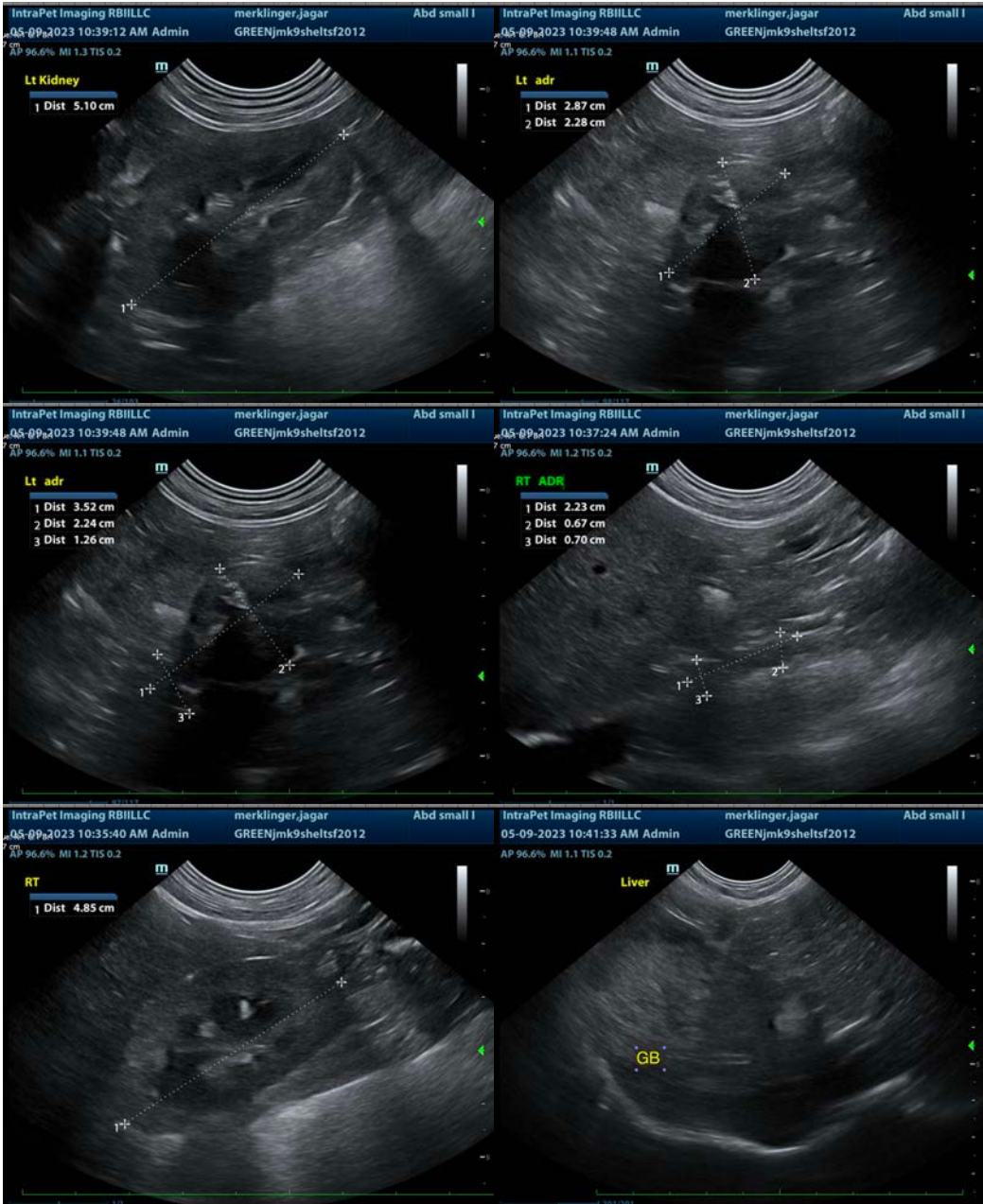
- **Emerging mucocele** – Cholecystic debris is of unknown clinical significance. It can be seen with biliary stasis from fasting or illness. Cholecystic debris is not necessarily related to hepatobiliary disease. The non-dependent nature of this sludge combined with the cystic areas are suggestive, however, of possible emerging cystic mucosal hyperplasia or early gallbladder mucocele.
- **Left adrenal mass with relatively normal sized but subjectively flat in appearance right adrenal gland** – This is concerning for a primary adrenal cortical tumor such as an adenoma or even adenocarcinoma. Adrenal hyperplasia secondary to pituitary dependent hyperadrenocorticism can't be ruled out but is considered slightly less likely. Additionally, while also considered less likely, a pheochromocytoma is possible.

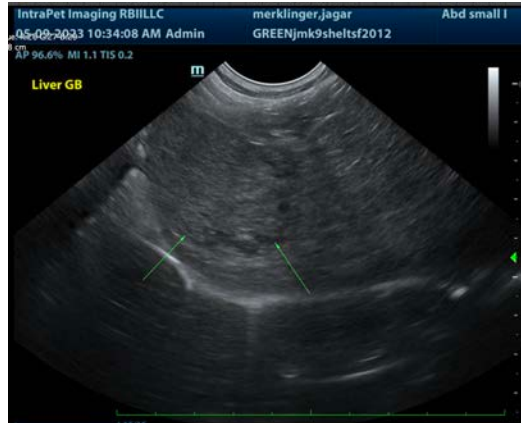INTERPRETATION OF THE FINDINGS & FURTHER RECOMMENDATIONS

Given the adrenal tumor, if not recently evaluated, a blood pressure is recommended. Additionally, quantification of the proteinuria is recommended via a urine protein to creatinine ratio to help guide treatment, if necessary, of the proteinuria. Adrenal cortical hormone testing is recommended, beginning with a low-dose Dexamethasone suppression test, followed potentially by endogenous ACTH to further differentiate, if the low dose Dexamethasone suppression test does not differentiate.

Additionally, pending results, urine catecholamine testing could be considered. Given this patient's breed and the gallbladder changes reported above, an emerging mucocele is also considered a significant finding and likely a concurrent contributor to the reported increases ALP. Ultimately, adrenalectomy is the treatment of choice for adrenal dependent hyperadrenocorticism, and if pursued, a cholecystectomy should be considered at the same time. If surgery is not pursued, empirical medical management with Ursodiol +/- broad-spectrum antibiotics and monitoring of ALP as well as ultrasounds of the gallbladder, etc. could be considered in the

meantime. This approach is a viable option if the patient is not clinical for the emerging mucocele, with clinical signs such as decreased appetite, nausea, cranial abdominal pain, etc. However, if clinical signs are present, a cholecystectomy should be considered, even if an adrenalectomy is not pursued.





The information and recommendations provided are based on the images presented by the referring veterinarian/sonographer. No evaluation can be communicated regarding pathology that was not visible in the image/video clips provided.

Thank you for this referral. If the clinical or image interpretation does not parallel your findings or if I can be of any further assistance please contact me.

Beth Johnson, DVM, DACVIM
Beth.Johnson@sonopath.com