

**DATE PRESENTING CLINICAL SIGNS**

5/9/23 Chronic intermittent UTIs for 2-3 years. No evidence of stones on xray.

**PATIENT**

Daisy Smith

Current Medications: Clavacillin 13.75 mg/kg starting on 5/5/23 - planning on 4-6 week course unless otherwise indicated, Rimadyl 50mg BID prn 4 days, Purina UR Diet, Fluoxetine and Trazodone for anxiety  
 Lab Results: UA 5/5/2023 - 1.046, pH 9.0, 100 leuk/uL, tntc rods, occasional cocci, Struvite 6-10/HPF, unclassified crystals 1-5/hpf. Urine culture 5/5/23 - pending. CBC/Chem 2/8/23 wnl

**SPECIES**

Canine

Urine culture 11/9/22 - proteus - good susceptibility  
 Date of Previous IntraPet Ultrasound: No previous.  
 Sedation: Not required to complete full diagnostic ultrasound.  
 Stat Report: Not requested.

**BREED**

Golden Retriever

Imaging Performed By: Rachel Brillhart, RDMS.

**ULTRASONOGRAPHIC EXAMINATION OF THE ABDOMEN****SEX**

Spayed Female

**Urinary System**

The urinary bladder is moderately distended with anechoic contents. No masses, inflammatory changes, echogenic sediment or cystoliths are observed. The urinary bladder and trigone are normal in thickness with a smooth mucosal surface. The proximal urethra is thick, measuring 0.40 cm thick with a slightly hyperechoic irregular mucosal surface.

**AGE**

1/18/19

The right kidney is normal in size (5.81 cm), shape and echogenicity. It has smooth peripheral margination. There is a normal 1:3 cortex to medulla ratio with appropriate corticomedullary distinction. There is no evidence of pyelectasia, mineral or infarcts observed.

**WEIGHT**

49.3 Pounds

The left kidney is normal in size (6.06 cm), shape and echogenicity. It has smooth peripheral margination. There is a normal 1:3 cortex to medulla ratio with appropriate corticomedullary distinction. There is no evidence of pyelectasia, mineral or infarcts observed.

**INTERPRETED BY**Beth Johnson, DVM  
DACVIM**Adrenal Glands**

The right adrenal gland is normal in size (2.83 cm long x 0.84 cm at the cranial pole and 0.86 cm at the caudal pole), shape and contour. Corticomedullary structure is unremarkable. Visible surrounding vasculature appears normal.

**HOSPITAL NAME**

Greenbrier Vet Clinic

The left adrenal gland is normal in size (2.59 cm long x 0.97 cm at the cranial pole and 0.79 cm at the caudal pole), shape and contour. Corticomedullary structure is unremarkable. Visible surrounding vasculature appears normal.

**REFERRING VET**

Dr. Whitfield

**Spleen**

The spleen is subjectively normal in size with a normal smooth capsular contour. Parenchyma is appropriately finely textured and homogenous with normal echogenicity relative to surrounding tissue (hyperechoic to liver). No focal nodules or masses are observed. Splenic vasculature appears normal.

**INVOICE**

47247

**Liver**

The liver is subjectively normal in size with normal smooth curvilinear peripheral contour. Parenchyma is appropriately hypoechoic to the spleen in echogenicity and appropriately mildly coarse and homogenous in echotexture. No focal lesions are observed. Visible vasculature and biliary tree appear normal without distension or congestion.

The gallbladder is non-distended in size. The wall is smooth without visible thickening. Luminal contents are primarily anechoic. There is no evidence of cystic or common bile duct dilation.

### ***Gastrointestinal***

The visible stomach wall is normal in thickness and layering. The lumen of the stomach is mildly distended with very echogenic reverberation artifact from intraluminal gas. There is no evidence of obstruction, foreign material or infiltrative disease; however, complete visualization of far wall is partially inhibited by gas. Pyloric outflow tract appears patent.

The visible small intestines are normal in wall thickness and layering (canine duodenum < 0.5 cm and feline duodenum < 0.4 cm; other < 0.3 cm). Small intestinal motility appears adequate (1-3 contractions per min). The lumen of the small intestine is empty with no evidence of obstruction, foreign material or infiltrative disease.

The visible colon is normal in wall thickness (< 0.2 cm) and layering. Contents are consistent with normal formed feces and gas.

### ***Pancreas***

The pancreatic parenchyma is appropriately isoechoic to surrounding tissue. Visible capsule is smooth and normal in contour. There is no visible pancreatic duct dilation. There is no evidence of active peripancreatic inflammation.

### ***Free Abdomen***

There is no evidence of free peritoneal effusion noted in these images.

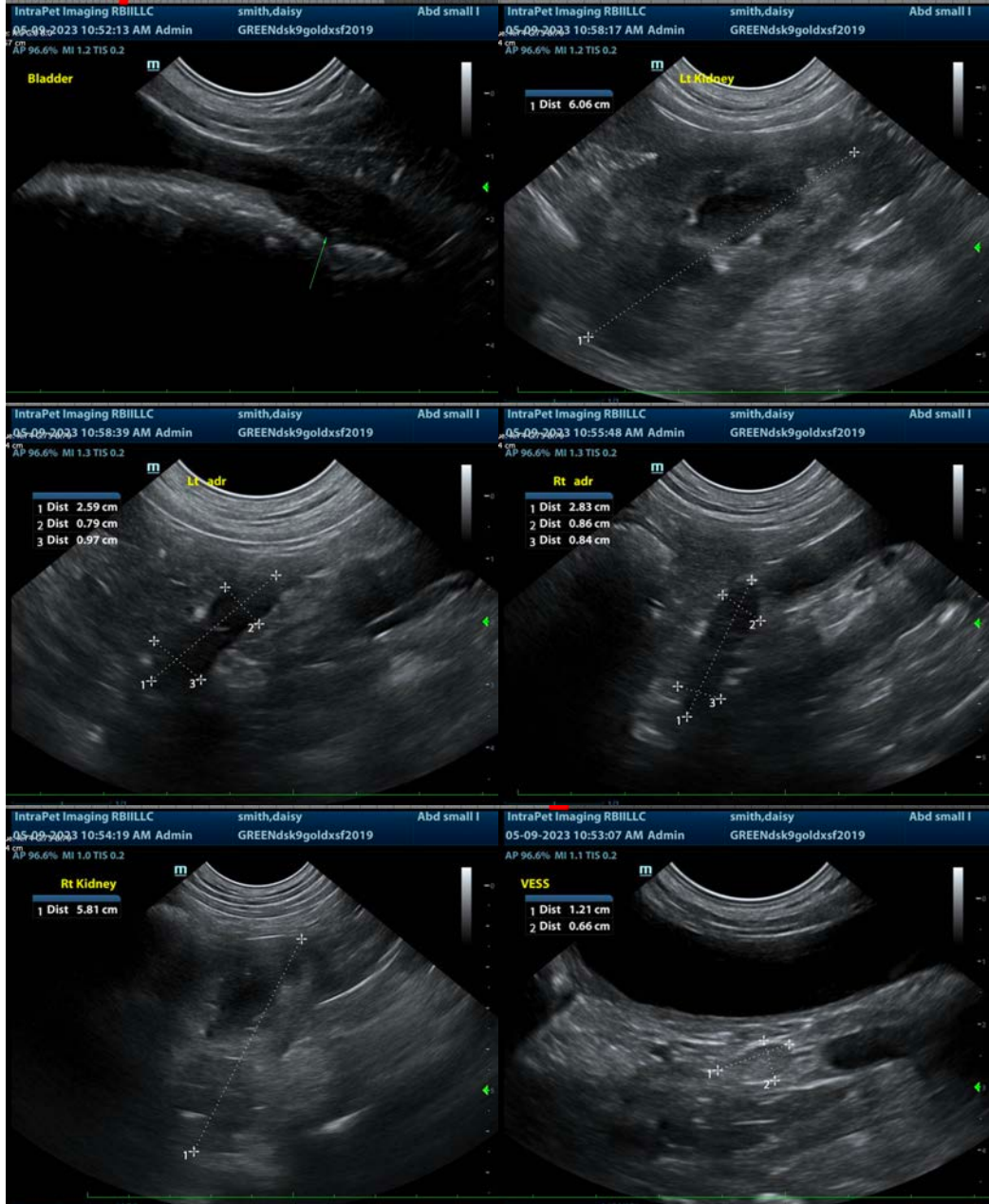
The sublumbar lymph nodes are prominent in size with swollen capsular contour. Normal elongated shape (length to width ratio) is maintained. There is no loss of parenchymal detail.

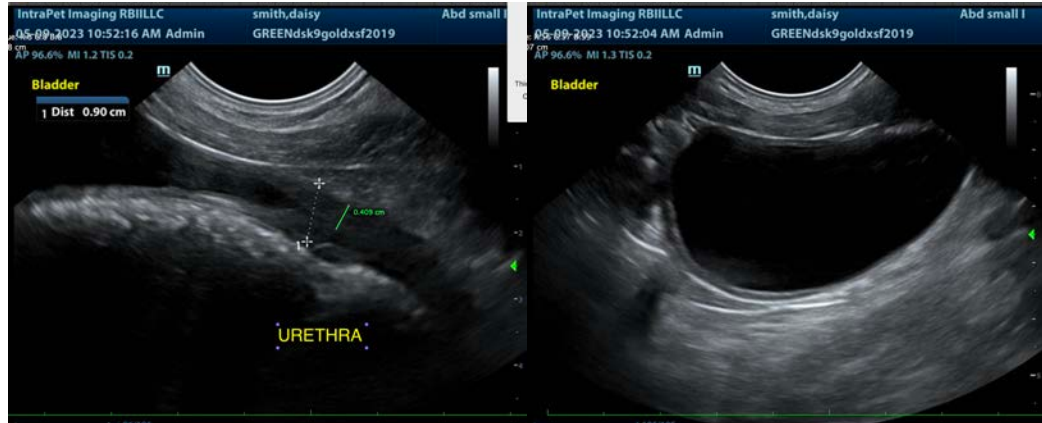
## **ULTRASONOGRAPHIC FINDINGS**

- **Mildly thick, irregular proximal urethra** – This trends in appearance towards benign as is seen with chronic inflammation. However, infiltrative neoplasia cannot be ruled out without additional information.
- **Reactive sublumbar lymph nodes** – infiltrative neoplastic disease cannot be ruled out but is considered less likely.

## **INTERPRETATION OF THE FINDINGS & FURTHER RECOMMENDATIONS**

As is reportedly already planned, recommendations are to treat the urinary tract infection (if patient is clinical) as a complicated urinary tract infection, meaning antibiotics based on culture and sensitivity results for 4-6 weeks with a follow up culture a week to 10 days after starting antibiotics to ensure full clearance, no secondary bugs, or resistance pattern change, etc., as well as a final culture a week to 10 days after finishing antibiotics to be sure the infection has fully cleared. If at that point clinical signs return and/or urethra thickness persists, submission of urine to look for BRAF gene mutation, which is associated with urinary bladder cancer, could be considered, versus other diagnostic options at that time, which could include traumatic catheterization or cystoscopy for further sampling. Probiotic therapy long-term may also be helpful





The information and recommendations provided are based on the images presented by the referring veterinarian/sonographer. No evaluation can be communicated regarding pathology that was not visible in the image/video clips provided.

Thank you for this referral. If the clinical or image interpretation does not parallel your findings or if I can be of any further assistance please contact me.

**Beth Johnson, DVM, DACVIM**  
Beth.Johnson@sonopath.com