



<b>DATE</b>	<b>PRESENTING CLINICAL SIGNS</b>
5/9/23	History of intermittent GI upset since a puppy with V/D and decreased appetite. Most recent physical exam was WNL. no weight loss. recent fecal negative, recent normal CBC/chem/CPL
<b>PATIENT</b>	
Cashew Bowman	Current Medications: None currently. Lab Results: See attached. Date of Previous IntraPet Ultrasound: No previous. Sedation: IV: Torb. Stat Report: Not requested. Imaging Performed By: Rachel Brillhart, RDMS.
<b>SPECIES</b>	
Canine	
<b>BREED</b>	<b>ULTRASONOGRAPHIC EXAMINATION OF THE ABDOMEN</b>
Unknown	<b>Urinary System</b> The urinary bladder is moderately distended with anechoic contents. No masses, inflammatory changes, echogenic sediment or cystoliths are observed. The urinary bladder, trigone and visible pelvic urethra are normal in thickness with a smooth mucosal surface.
<b>SEX</b>	
Spayed Female	The right kidney is normal in size (5.91 cm), shape and echogenicity. It has smooth peripheral margination. There is a normal 1:3 cortex to medulla ratio with appropriate corticomedullary distinction. There is no evidence of pyelectasia, mineral or infarcts observed.
<b>AGE</b>	
4/3/21	The left kidney is normal in size (5.82 cm), shape and echogenicity. It has smooth peripheral margination. There is a normal 1:3 cortex to medulla ratio with appropriate corticomedullary distinction. There is no evidence of pyelectasia, mineral or infarcts observed.
<b>WEIGHT</b>	
59 Pounds	<b>Adrenal Glands</b> The right adrenal gland is normal in size (3.06 cm long x 0.66 cm at the cranial pole and 0.57 cm), shape and contour. Corticomedullary structure is unremarkable. Visible surrounding vasculature appears normal.
<b>INTERPRETED BY</b>	
Beth Johnson, DVM DACVIM	The left adrenal gland is normal in size (2.78 cm long x 0.52 cm at the cranial pole and 0.66 cm at the caudal pole), shape and contour. Corticomedullary structure is unremarkable. Visible surrounding vasculature appears normal.
<b>HOSPITAL NAME</b>	
Greenbrier Vet Clinic	<b>Spleen</b> The spleen is subjectively normal in size with a normal smooth capsular contour. Parenchyma is appropriately finely textured and homogenous with normal echogenicity relative to surrounding tissue (hyperechoic to liver). No focal nodules or masses are observed. Splenic vasculature appears normal.
<b>REFERRING VET</b>	
Dr. Boccanfuso	<b>Liver</b> The liver is subjectively normal in size with normal smooth curvilinear peripheral contour. Parenchyma is appropriately hypoechoic to the spleen in echogenicity and appropriately mildly coarse and homogenous in echotexture. No focal lesions are observed. Visible vasculature and biliary tree appear normal without distension or congestion.
<b>INVOICE</b>	
47245	The gallbladder is non-distended in size. The wall is smooth without visible thickening. Luminal contents are primarily anechoic. There is no evidence of cystic or common bile duct dilation.
	<b>Gastrointestinal</b> The visible stomach wall is normal in thickness and layering. The lumen of the stomach is mildly distended with very echogenic reverberation artifact from intraluminal gas. There is no evidence of obstruction, foreign

material or infiltrative disease; however, complete visualization of far wall is partially inhibited by gas. Pyloric outflow tract appears patent.

The visible small intestine demonstrates areas of thick muscularis layer relative to mucosa (disruption of the normal 1:3 muscularis:mucosa ratio). Small intestinal submucosa is slightly irregular, thick and hyperechoic, without evident loss of layering appreciated.

The visible colon is normal in wall thickness (< 0.2 cm) and layering. Contents are consistent with normal formed feces and gas.

### ***Pancreas***

The pancreatic parenchyma is appropriately isoechoic to surrounding tissue. Visible capsule is smooth and normal in contour. There is no visible pancreatic duct dilation. There is no evidence of active peripancreatic inflammation.

### ***Free Abdomen***

There is no evidence of free peritoneal effusion noted in these images.

There is no apparent lymphadenopathy noted in these images.

## **ULTRASONOGRAPHIC FINDINGS**

- **Inflammatory bowel disease (IBD) pattern** – Thick muscularis has been reported with infiltrative bowel disease including both benign inflammatory disease as well as infiltrative neoplasia such as lymphoma. No aggressive lymphadenopathy, loss of layering, etc. is noted to make lymphoma more probable, but lymphoma cannot be definitively ruled out without tissue sampling.

## **INTERPRETATION OF THE FINDINGS & FURTHER RECOMMENDATIONS**

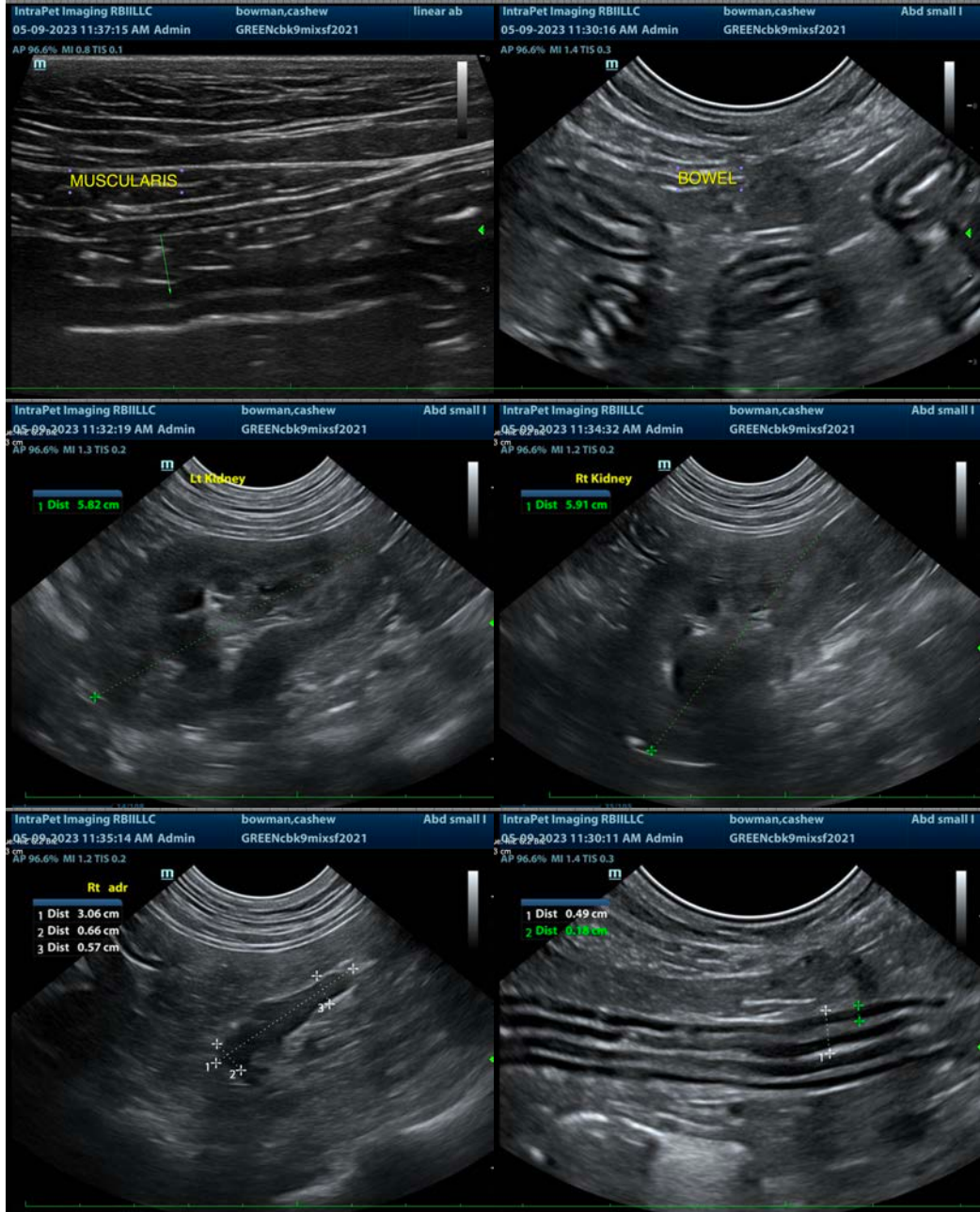
Next diagnostic recommendations include an overall general metabolic evaluation (CBC, chemistry panel with electrolytes, urinalysis, and fecal exam if not recently evaluated), followed by: A gastrointestinal malabsorption panel (including cobalamin, folate, TLI and PLI) to Texas A&M GI Laboratory is recommended for further evaluation of GI and pancreatic function.

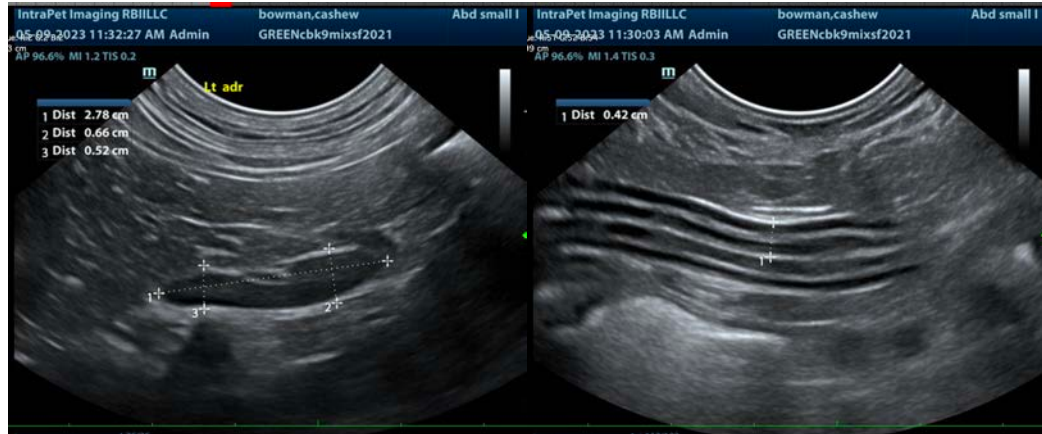
A baseline cortisol is recommended. If baseline cortisol is less than 2, a full ACTH stimulation test is recommended to rule out hypoadrenocorticism.

A fecal enteropathogen PCR panel to Texas A&M GI Laboratory could be considered for further evaluation of possible infectious disease.

In the meantime, supportive/symptomatic medical management of clinical signs is recommended, including a probiotic (such as visbiome or proviable), empirical deworming with a 5-day course of Panacur and, if tolerated, a transition in diet, based on trial-and-error response, beginning with a hydrolyzed protein diet. Some patients respond to one brand/version of a hydrolyzed protein diet better than another brand, so several attempts may be required.

Ultimately, if clinical signs persist, and a diagnosis is not reached, further evaluation of the GI tract via upper and lower endoscopy for visualization and biopsies may be warranted.





The information and recommendations provided are based on the images presented by the referring veterinarian/sonographer. No evaluation can be communicated regarding pathology that was not visible in the image/video clips provided.

Thank you for this referral. If the clinical or image interpretation does not parallel your findings or if I can be of any further assistance please contact me.

**Beth Johnson, DVM, DACVIM**  
Beth.Johnson@sonopath.com