


PATIENT

Dodge Schmidt

SPECIES

Feline

BREED

DSH

SEX

Spayed Female

AGE

10 years

WEIGHT

12.8 lbs

INTERPRETED BY

 Beth Johnson, DVM
 DACVIM

**IMAGING
 PERFORMED BY**

Crystal Hill

HOSPITAL NAME

 Dog & Cat
 Clinic Niagara

REFERRING VET

Nick

INVOICE

12975

DATE

5.8.23

PRESENTING CLINICAL SIGNS

History: Vomiting off and on for the past year and noticed lately a reduced appetite. Has been on Gabapentin.

Abnormal PE/Chem/CBC/UA Results: N/A

ULTRASONOGRAPHIC EXAMINATION OF THE ABDOMEN
Urinary System

Urinary bladder is adequately distended with anechoic contents. No masses, inflammatory changes, echogenic sediment or cystoliths are observed. The urinary bladder, trigone and visible pelvic urethra are normal in thickness with a smooth mucosal surface.

Left kidney is normal in size (3.91 cm), shape and echogenicity. It has smooth peripheral margination. There is a normal 1:3 cortex to medulla ratio with appropriate corticomedullary distinction. There is no evidence of pyelectasia, mineral or infarcts observed.

Right kidney is normal in size (3.99 cm), shape and echogenicity. It has smooth peripheral margination. There is a normal 1:3 cortex to medulla ratio with appropriate corticomedullary distinction. There is no evidence of pyelectasia, mineral or infarcts observed.

Adrenal Glands

Left adrenal gland is normal in size (0.45 cm), shape and overall architecture, echogenicity and echotexture. Visible surrounding vasculature appears normal.

Right adrenal gland is normal in size (0.58 cm), shape and overall architecture, echogenicity and echotexture. Visible surrounding vasculature appears normal.

Spleen

Spleen is subjectively normal in size with a normal smooth capsular contour. Parenchyma is appropriately finely textured and homogenous with normal echogenicity relative to surrounding tissue (hyperechoic to liver). No focal nodules or masses are observed. Splenic vasculature appears normal.

Liver

Liver is subjectively normal in size with normal smooth curvilinear peripheral contour. Parenchyma is appropriately hypoechoic to the spleen in echogenicity and appropriately mildly coarse and homogenous in echotexture. No focal lesions are observed. Visible vasculature and biliary tree appear normal without distension or congestion.

Gallbladder is non-distended in size. The wall is smooth without visible thickening. Luminal contents are primarily anechoic. There is no evidence of cystic or common bile duct dilation.

Gastrointestinal

The visible stomach wall is normal in thickness and layering. The lumen of the stomach is empty with no evidence of obstruction, foreign material or infiltrative disease. Pyloric outflow tract appears patent.

The visible small intestine demonstrates areas of thick muscularis layer relative to mucosa (disruption of the normal 1:3 muscularis:mucosa ratio). Small intestinal submucosa is slightly irregular, thick and hyperechoic, without evident loss of layering appreciated. The lumen of the small intestine is empty with no evidence of obstruction or foreign material.



PATIENT

The visible colon is normal in wall thickness and layering. Contents are consistent with normal formed feces and gas.

Dodge Schmidt

Pancreas

The observed pancreas appears appropriately isoechoic to surrounding omental fat. Visible capsule is smooth and normal in contour. Visible pancreatic parenchyma is homogenous and unremarkable. There is no visible pancreatic duct dilation. There is no evidence of active peripancreatic inflammation.

SPECIES

Feline

Free Abdomen

No free fluid is noted in these images. In the midabdomen, near the root of the mesentery, mild lymphadenopathy is appreciated as well as generally enhanced hyperechoic mesenteric fat.

BREED

DSH

ULTRASONOGRAPHIC FINDINGS

SEX

Findings

Spayed Female

- Inflammatory bowel disease (IBD) pattern – Thick muscularis has been reported with infiltrative bowel disease including both benign inflammatory disease as well as infiltrative neoplasia such as lymphoma. No aggressive lymphadenopathy, loss of layering, etc. is noted to make lymphoma more probable, but lymphoma cannot be definitively ruled out without tissue sampling.
- The lymphadenopathy and enhanced mesenteric fat is most likely secondary to inflammatory bowel disease. However, chronic, smoldering pancreatitis contributing to the enhanced fat cannot be definitively ruled out.

AGE

10 years

WEIGHT

12.8 lbs

INTERPRETATION OF THE FINDINGS & FURTHER RECOMMENDATIONS

A gastrointestinal malabsorption panel (including cobalamin, folate, TLI and PLI) to Texas A&M GI Laboratory is recommended for further evaluation of GI and pancreatic function.

INTERPRETED BY

Beth Johnson, DVM
DACVIM

Ideally, biopsies of the GI tract, being sure to include ileum if possible, are recommended to definitively diagnose and therefore manage the infiltrative bowel disease. Alternatively, a fine-needle aspirate of the enlarged lymph node can be considered (if the patient's coagulation status is appropriate), and biopsies only pursued if a cytologic diagnosis of lymphoma is not obtained.

IMAGING PERFORMED BY

Crystal Hill

If tissue sampling cannot be obtained, empirical therapies could include diet change, empirical deworming with a 5-day course of Panacur, cobalamin supplementation (unless cobalamin level is evaluated and supplementation is not warranted) and prednisolone (if not contraindicated based on patient contraindications, co-morbidities, etc.). Other supportive therapeutic considerations could include fiber supplementation, especially with large bowel diarrhea and/or a probiotic.

HOSPITAL NAME

Dog & Cat
Clinic Niagara

REFERRING VET

Nick

INVOICE

12975

DATE

5.8.23



PATIENT

Dodge Schmidt

SPECIES

Feline

BREED

DSH

SEX

Spayed Female

AGE

10 years

WEIGHT

12.8 lbs

INTERPRETED BY

Beth Johnson, DVM
DACVIM

IMAGING PERFORMED BY

Crystal Hill

HOSPITAL NAME

Dog & Cat
Clinic Niagara

REFERRING VET

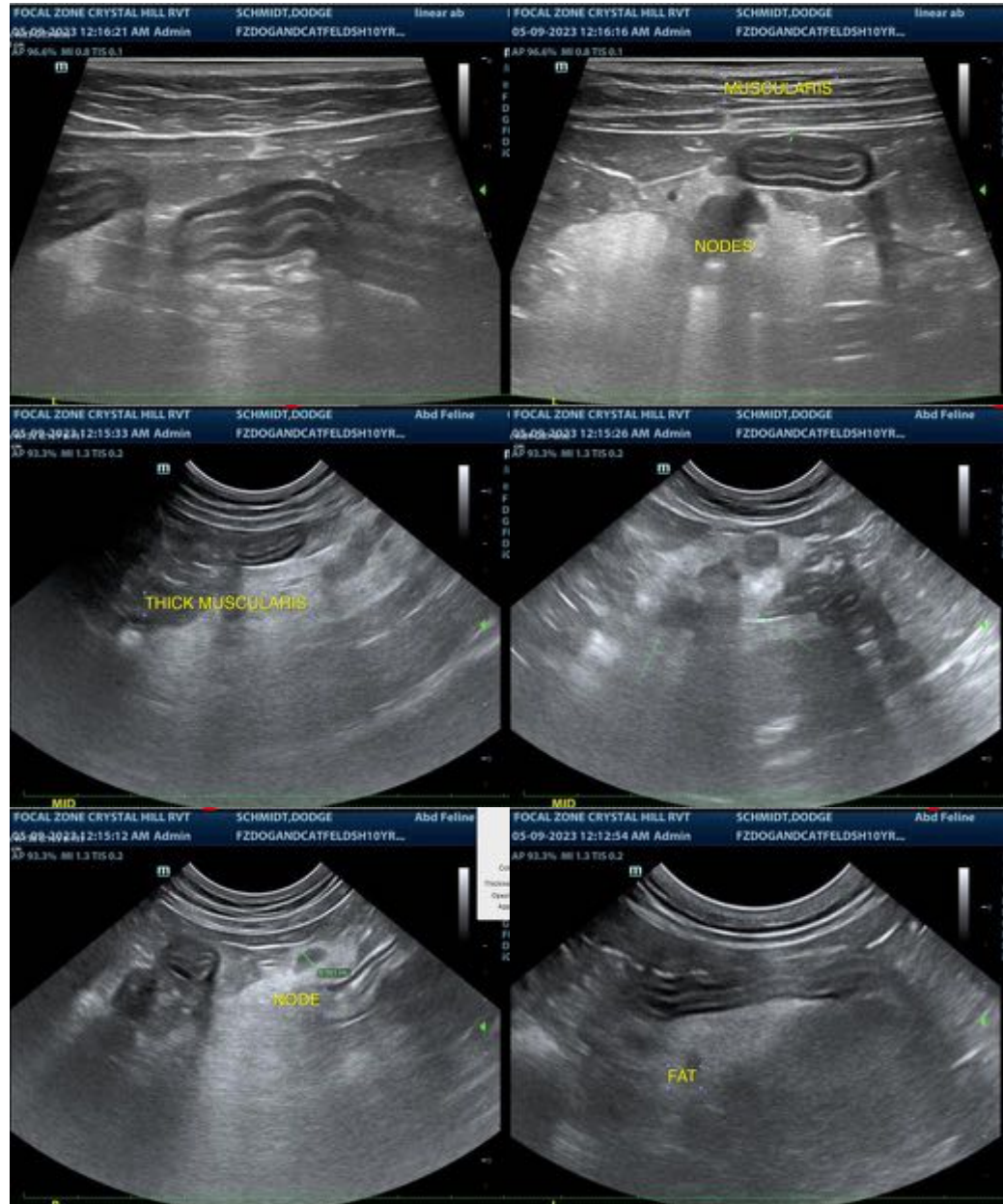
Nick

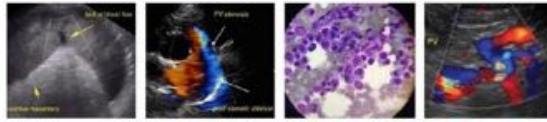
INVOICE

12975

DATE

5.8.23





PATIENT

Dodge Schmidt

SPECIES

Feline

BREED

DSH

SEX

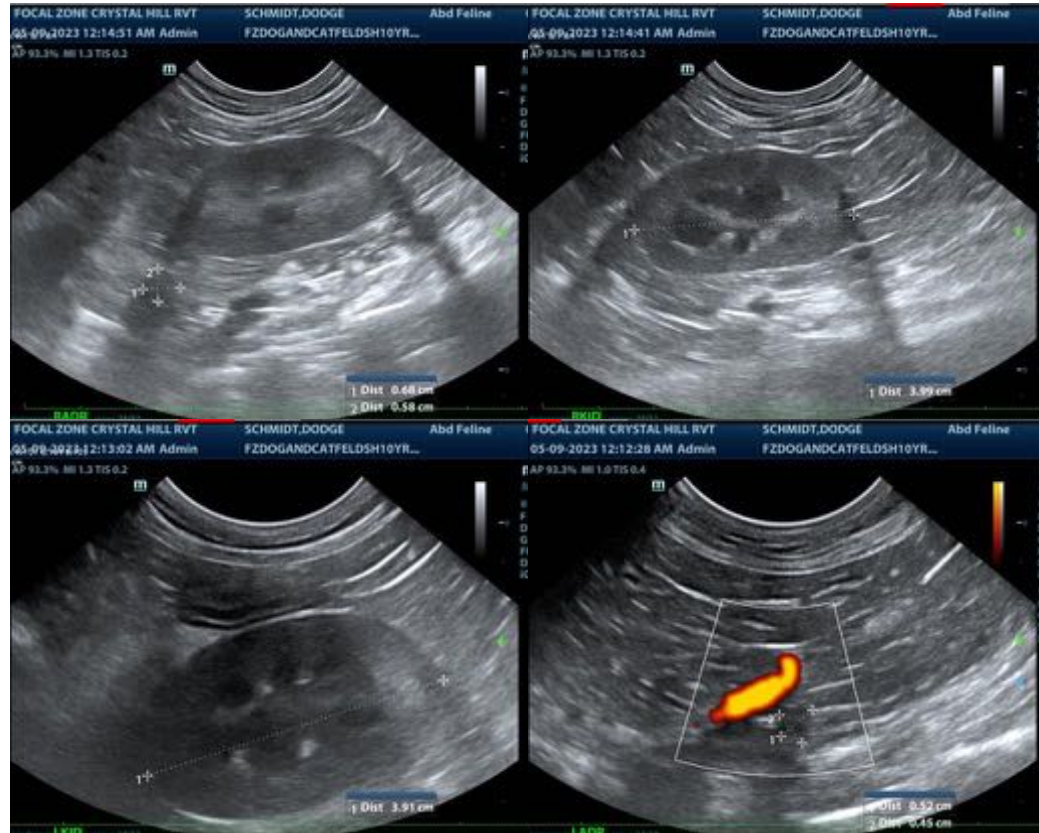
Spayed Female

AGE

10 years

WEIGHT

12.8 lbs



INTERPRETED BY

Beth Johnson, DVM
DACVIM

IMAGING PERFORMED BY

Crystal Hill

HOSPITAL NAME

Dog & Cat
Clinic Niagara

REFERRING VET

Nick

INVOICE

12975

DATE

5.8.23

The information and recommendations provided are based on the images presented by the referring veterinarian. No evaluation can be communicated regarding pathology that was not visible in the image/video clips provided.

Thank you for this referral. If the clinical or image interpretation does not parallel your findings or if I can be of any further assistance, please contact me.

Beth Johnson, DVM DACVIM
Beth.Johnson@SonoPath.com