



DATE PRESENTING CLINICAL SIGNS

5/7/26 **History:** Historic marked liver enzyme elevations, treated supportively at ER. P has been doing better overall but still picky and having chronic diarrhea. Liver enzymes have worsened at recheck.

PATIENT

Ziggy David

Current Medications: DENAMARIN ADV CHEW SM/MD 30CT BOTTLE 4/29/2026, PREDNISOLONE 5MG TABLET 4/29/2026, PRO-PECTALIN TABLETS 4/28/2026, METRONIDAZOLE 250MG TABLET 4/22/2026 MIRTAZAPINE 15 MG TABLET 4/22/2026

SPECIES

Canine

Labwork Results: Labwork attached, reported as: ALBUMIN 2.2 2.7-4.4 g/dL LOW, GLOBULIN 3.8 1.6-3.6 g/dL HIGH, A/G RATIO 0.6 0.8-2.0 LOW, AST (SGOT) 88 15-66 IU/L HIGH, ALT (SGPT) 834 12-118 IU/L HIGH, ALK PHOS 5201 5-131 IU/L HIGH, GGT 56 1-12 IU/L HIGH Result Verified, T. BILIRUBIN 2.0 0.1-0.3 mg/dL HIGH

BREED

Pit Bull x

Date of Previous IntraPet Ultrasound: No previous.
Sedation: IV Torb required to complete full diagnostic ultrasound.
Stat Report: Not requested.
Imaging Performed by: Rachel Brilhart, RDMS.

SEX

Neutered Male

ULTRASONOGRAPHIC EXAMINATION OF THE ABDOMEN

Urinary System

AGE

8/10/17

The urinary bladder is adequately distended with anechoic contents. No masses, inflammatory changes, echogenic sediment or cystoliths are observed. The urinary bladder, trigone and visible pelvic urethra are normal in thickness with a smooth mucosal surface.

WEIGHT

47.6 lbs

Prostate is normal in size, echotexture and echogenicity for a neutered male.

INTERPRETED BY

Beth Johnson, DVM
DACVIM

The right kidney is normal is size (6.68 cm), shape and echogenicity. It has smooth peripheral margination. There is a normal 1:3 cortex to medulla ratio with appropriate corticomedullary distinction. There is no evidence of pyelectasia, mineral or infarcts observed. One cortical cyst is present in the right kidney.

HOSPITAL NAME

Everhart Veterinary
Hospital

The left kidney is normal is size (7.02 cm), shape and echogenicity. It has smooth peripheral margination. There is a normal 1:3 cortex to medulla ratio with appropriate corticomedullary distinction. There is no evidence of pyelectasia, mineral or infarcts observed.

Adrenal Glands

REFERRING VET

Dr. Caplan

The right adrenal gland is normal in size (0.60 cm at cranial pole and 0.50 cm at caudal pole), shape and overall architecture, echogenicity and echotexture. Visible surrounding vasculature appears normal.

The left adrenal gland is normal in size (0.60 cm at cranial pole and 0.60 cm at caudal pole), shape and overall architecture, echogenicity and echotexture. Visible surrounding vasculature appears normal.

INVOICE

75038

Spleen

Spleen is subjectively large in size with a swollen and scalloped/undulating capsular contour. Multifocal coalescing nodules are noted throughout the parenchyma. Splenic vasculature appears normal. Enhanced hyperechoic surrounding fat is noted.

Liver

Liver is subjectively enlarged with mildly irregular margins. Parenchyma is mottled by multifocal discrete hypoechoic nodules of varying sizes "moth-eaten". Visible vasculature and biliary tree appear normal without distension or congestion.

Gallbladder is moderately distended with anechoic bile as well as suspended and gravity dependent echogenic debris. The wall is smooth without visible thickening. There is no evidence of cystic or CBD dilation. There is no evidence of effusion or inflammation.

Gastrointestinal

The visible gastric wall is normal in thickness and layering. The lumen, however, is mildly to moderately distended with intraluminal curvilinear echogenic interface with strong acoustic shadowing.

The visible small intestines are normal in wall thickness and layering. Small intestinal motility appears adequate (1-3 contractions per min). The lumen of the small intestine is empty with no evidence of obstruction, foreign material or infiltrative disease.

The visible colon is normal in wall thickness (< 0.2 cm) and layering. Contents are consistent with normal formed feces and gas.

Pancreas

The pancreas that is observed appears appropriately isoechoic to surrounding omental fat. Visible capsule is smooth and normal in contour. Visible pancreatic parenchyma is homogenous and unremarkable. There is no visible pancreatic duct dilation. There is no evidence of active peripancreatic inflammation.

Free Abdomen

There is a moderate amount of free fluid noted in these images.

There is no apparent pathologic lymphadenopathy noted in these images.

The visible heart base (RA) and pericardium are unremarkable without obvious pathology noted in these images at this time. If cardiac function evaluation is desired, a full echocardiogram is recommended.

ULTRASONOGRAPHIC FINDINGS

- Honeycomb Spleen – This finding is strongly suggestive of infiltrative disease such as round cell neoplasia. Benign disease cannot be ruled out but is considered less likely.
- Nodular Liver - This finding is concerning for infiltrative disease such as round cell neoplasia or metastatic neoplasia. Benign disease (nodular hyperplasia) cannot be ruled out but is considered less likely.
- The moderate amount of free fluid is of unknown origin. Differentials (unless already ruled out) could include increased hydrostatic pressure (cardiac disease and/or vascular or lymph blockage), decreased oncotic pressure (low albumin), vasculitis, paraneoplastic fluid, rupture/leakage of/from an organ (GI, GB, UB, other), blood (hemoabdomen), other.

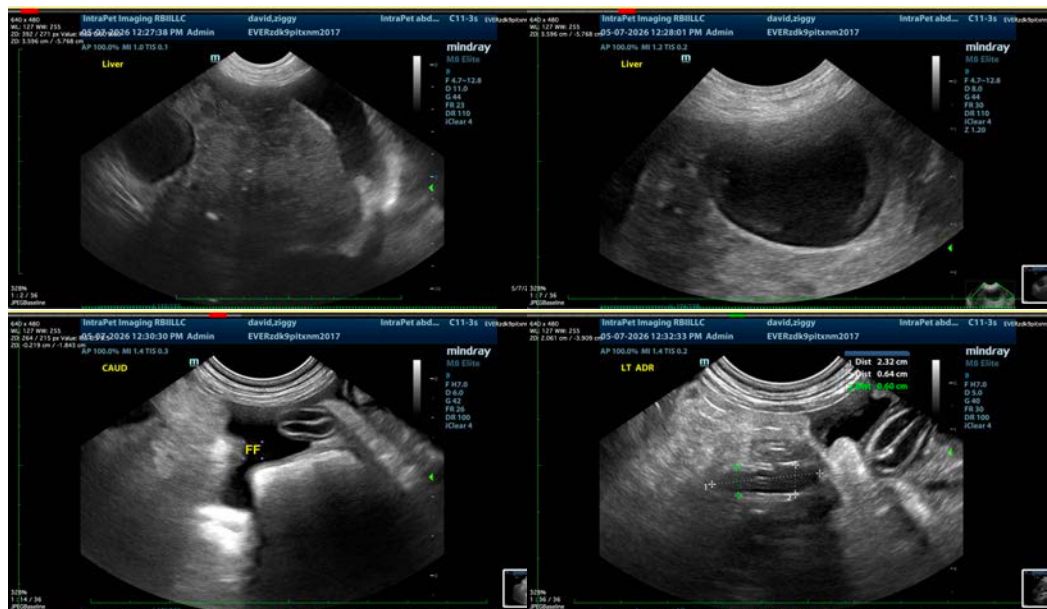
- Gastric foreign material, given the shadowing described above can't be ruled out. Similarly, however, normal ingesta and gas can result in that appearance and this finding should be interpreted in combination with when patient last ate, any clinical signs of foreign material, and potentially in combination with follow up imaging after an additional 12-24 hours of fasting.
- Mild gallbladder debris - Cholecystic debris is of unknown clinical significance. It can be seen with biliary stasis from fasting or illness. Cholecystic debris is not necessarily related to hepatobiliary disease. Echogenic bile is most commonly an incidental finding in dogs and should be interpreted in combination with clinical signs such as nausea, inappetence, cranial abdominal discomfort and/or laboratory changes such as increased ALP and/or increased Tbili.

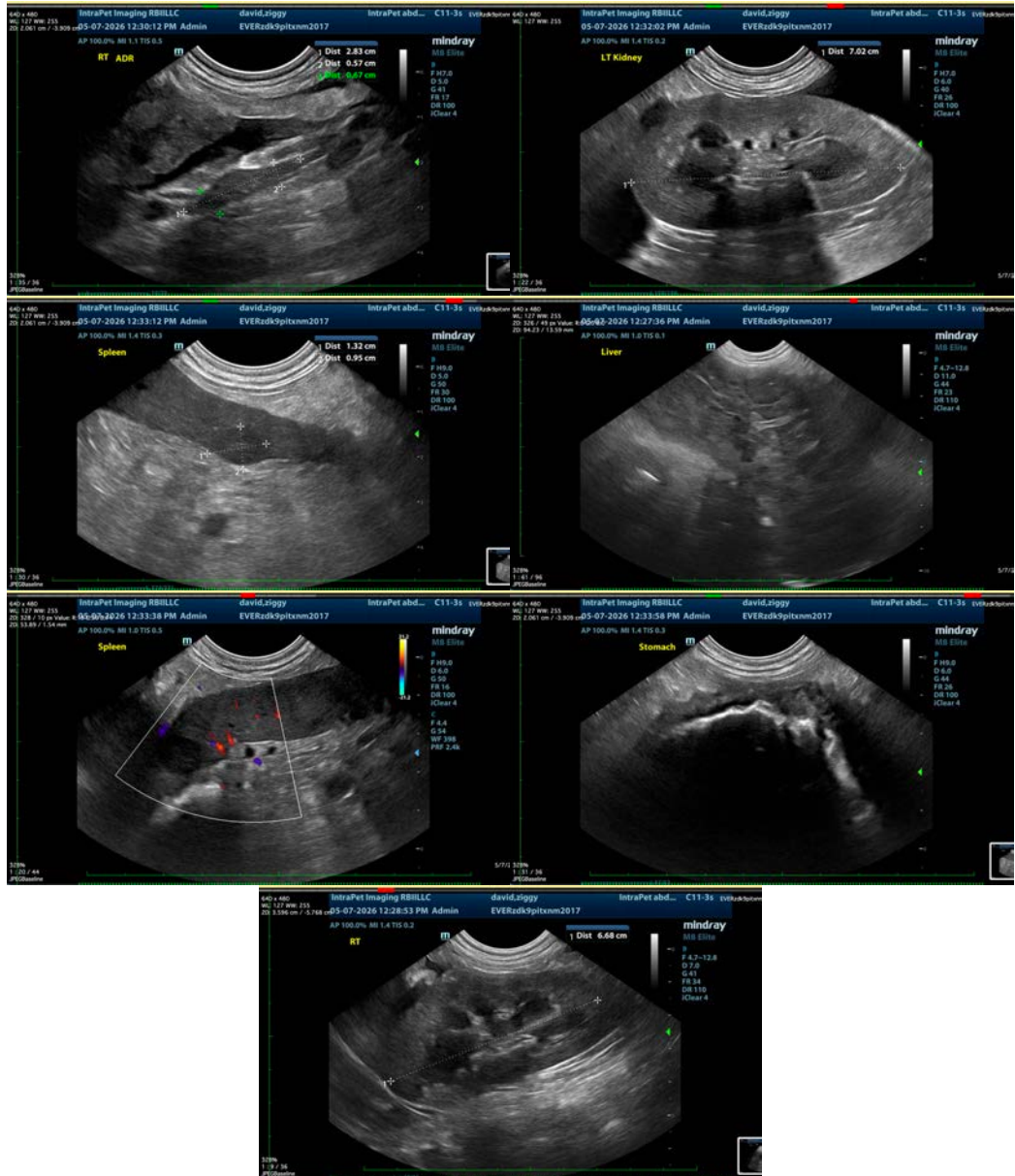
INTERPRETATION OF THE FINDINGS & FURTHER RECOMMENDATIONS

Three view thoracic radiographs are recommended for further assessment of cardio-pulmonary status as well as to further evaluate for any evidence of metastatic disease, if not recently evaluated.

Fine needle aspirates of the liver and spleen as well as sampling of the free abdominal fluid are recommended if patient's coagulation status is appropriate.

Other than supportive/symptomatic medical management of clinical signs, further treatment recommendations are largely dependent on results of the above.





The information and recommendations provided are based on the images presented by the referring veterinarian/sonographer. No evaluation can be communicated regarding pathology that was not visible in the image/video clips provided.

Thank you for this referral. If the clinical or image interpretation does not parallel your findings or if I can be of any further assistance please contact me.

Beth Johnson, DVM, DACVIM
 info@sonopath.com