



PATIENT

Cooper Urban

SPECIES

Canine

BREED

Lab Retriever x

SEX

Spayed Female

AGE

5 Years

WEIGHT

48 lbs

INTERPRETED BY

Beth Johnson, DVM
DACVIM

IMAGING PERFORMED BY

Dr. Sheldon

HOSPITAL NAME

Advanced PetCare of
Oakland

REFERRING VET

Dr. Sheldon

INVOICE

75029

DATE

5/7/26

PRESENTING CLINICAL SIGNS

Newly elevated ALT liver enzyme elevation not 2/27/26 ALT 143 recheck 4/10/26 ALT 175. Pet is otherwise normal.

ULTRASONOGRAPHIC EXAMINATION OF THE ABDOMEN

Urinary System

The urinary bladder is adequately distended with anechoic contents. No masses, inflammatory changes, echogenic sediment or cystoliths are observed. The urinary bladder, trigone and visible pelvic urethra are normal in thickness with a smooth mucosal surface.

The right kidney is normal is size (4.97 cm), shape and echogenicity. It has smooth peripheral margination. There is a normal 1:3 cortex to medulla ratio with appropriate corticomedullary distinction. There is no evidence of pyelectasia, mineral or infarcts observed.

The left kidney is normal is size (5.81 cm), shape and echogenicity. It has smooth peripheral margination. There is a normal 1:3 cortex to medulla ratio with appropriate corticomedullary distinction. There is no evidence of pyelectasia, mineral or infarcts observed.

Adrenal Glands

The right adrenal gland is normal in size (0.43 cm at cranial pole and 0.50 cm at caudal pole), shape and overall architecture, echogenicity and echotexture. Visible surrounding vasculature appears normal.

The left adrenal gland is normal in size (0.42 cm at cranial pole and 0.39 cm at caudal pole), shape and overall architecture, echogenicity and echotexture. Visible surrounding vasculature appears normal.

Spleen

The spleen is subjectively normal in size with a normal smooth capsular contour. Parenchyma is appropriately finely textured and homogenous with normal echogenicity relative to surrounding tissue (hyperechoic to liver). No focal nodules or masses are observed. Splenic vasculature appears normal.

Liver

Liver is subjectively enlarged with mildly irregular margins. Parenchyma is mildly heterogenous characterized by multiple poorly defined hypoechoic nodules within otherwise hyperechoic liver parenchyma. Visible vasculature and biliary tree appear normal without distension or congestion

The gallbladder is non-distended in size. The wall is smooth without visible thickening. Luminal contents are primarily anechoic. There is no evidence of cystic or common bile duct dilation.

Gastrointestinal

The visible stomach wall is normal in thickness and layering. The lumen of the stomach is empty with no evidence of obstruction, foreign material or infiltrative disease. Pyloric outflow tract appears patent.

The visible small intestines are normal in wall thickness and layering. Small intestinal motility appears adequate (1-3 contractions per min). The lumen of the small intestine is empty with no evidence of obstruction, foreign material or infiltrative disease.

The visible colon is normal in wall thickness (< 0.2 cm) and layering. Contents are consistent with normal formed feces and gas.



PATIENT

Cooper Urban

SPECIES

Canine

BREED

Lab Retriever x

SEX

Spayed Female

AGE

5 Years

WEIGHT

48 lbs

INTERPRETED BY

Beth Johnson, DVM
DACVIM

IMAGING PERFORMED BY

Dr. Sheldon

HOSPITAL NAME

Advanced PetCare of
Oakland

REFERRING VET

Dr. Sheldon

INVOICE

75029

DATE

5/7/26

Pancreas

The pancreas that is observed appears appropriately isoechoic to surrounding omental fat. Visible capsule is smooth and normal in contour. Visible pancreatic parenchyma is homogenous and unremarkable. There is no visible pancreatic duct dilation. There is no evidence of active peripancreatic inflammation.

Free Abdomen

There is no visible free peritoneal effusion noted in these images.

There is no apparent pathologic lymphadenopathy noted in these images.

ULTRASONOGRAPHIC FINDINGS

- An obvious cause for the subtle liver changes is not identified in these images. Microscopic disease such as Leptospirosis, bacterial cholangiohepatitis, chronic active hepatitis, copper-associated hepatotoxicity, other hepatotoxicity, other reactive hepatopathy, infiltrative neoplasia, etc. cannot be definitively ruled out.


INTERPRETATION OF THE FINDINGS & FURTHER RECOMMENDATIONS

Differentials for a primary hepatocellular injury liver enzyme pattern (increased ALT) depend partially on the level of increase. Mild increases (less than 2 times normal) are often a "reactive hepatopathy" or the liver's response to an insult elsewhere in the body including, but not limited to, pancreatitis, gastroenteritis, parasitic disease, dental disease, vacuolar or endocrine hepatopathy from diabetes mellitus or hyperadrenocorticism (steroid-induced), hypoadrenocorticism, certain drugs (e.g. phenobarbital, corticosteroids, azathioprine, etc.), and muscle ALT (more likely if AST and CK concurrently increased).

It is a good indicator of active liver damage (cell membrane disruption, cellular necrosis), however, if the value is increased by at least 3-4 times normal. Differentials include infectious disease, including Leptospirosis, inflammatory disease (ie. active hepatitis, copper, other), toxic insult as well as infiltrative neoplasia.

ALT levels vary in cases of vascular anomalies such as microvascular dysplasia and portosystemic shunts (PSS), but are often less significantly increased.

- Testing for Leptospirosis could be considered.
- Bile acids could be considered, if tбили is not increased.
- An empirical course of antibiotics and empirical hepatic nutraceuticals may be tried, with monitoring of ALT for improvement. If improvement is noted, antibiotics should be continued until liver enzymes either normalize or plateau (recheck every 2-3 weeks); however, if improvement is not noted and/or enzyme increase progresses, antibiotics should not be continued long term and liver tissue sampling is recommended.
- FNA of the liver can be performed to assess inflammatory cell type, rule in/out round cell neoplasia, etc. (if patient's coagulation status is appropriate).



PATIENT

Cooper Urban

SPECIES

Canine

BREED

Lab Retriever x

SEX

Spayed Female

AGE

5 Years

WEIGHT

48 lbs

INTERPRETED BY

Beth Johnson, DVM
DACVIM

IMAGING PERFORMED BY

Dr. Sheldon

HOSPITAL NAME

Advanced PetCare of
Oakland

REFERRING VET

Dr. Sheldon

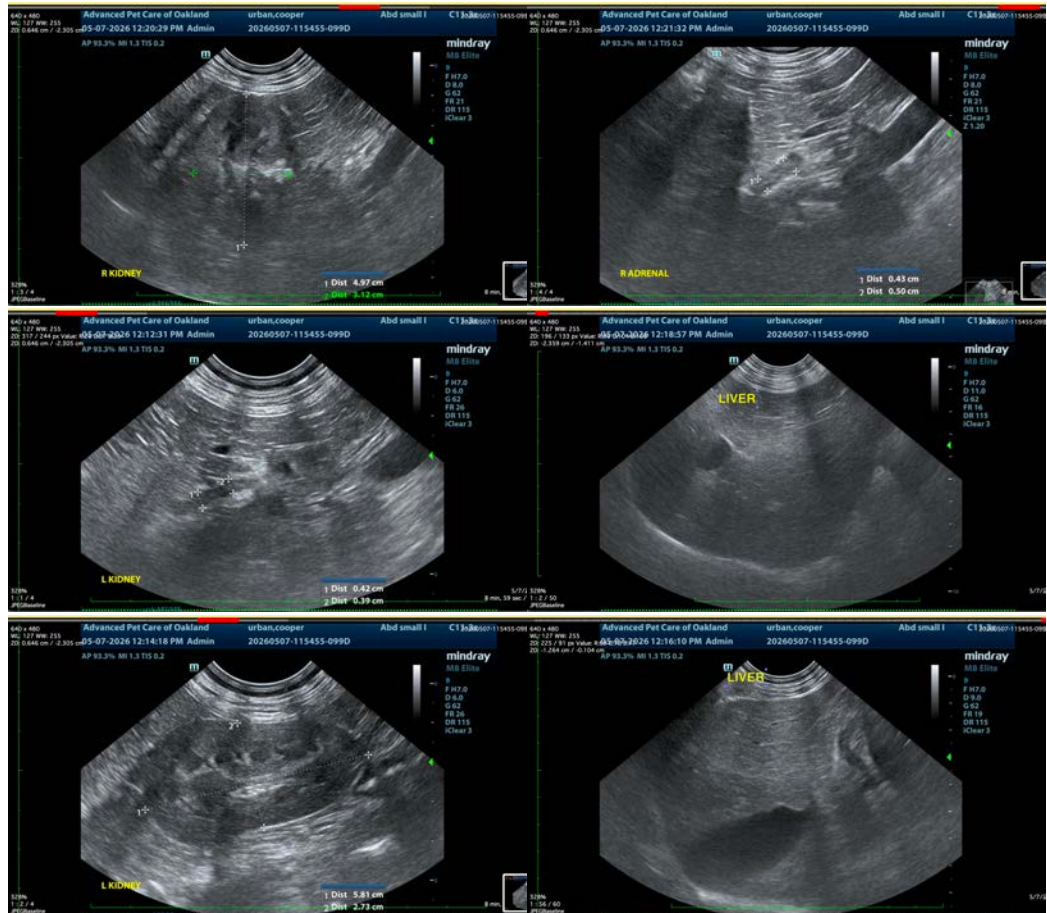
INVOICE

75029

DATE

5/7/26

- If round cell neoplasia is not diagnosed, a liver biopsy (including copper level assessment) may be required to definitively diagnose the underlying hepatopathy.



The information and recommendations provided are based on the images presented by the referring veterinarian/sonographer. No evaluation can be communicated regarding pathology that was not visible in the image/video clips provided.

Thank you for this referral. If the clinical or image interpretation does not parallel your findings or if I can be of any further assistance please contact me.

Beth Johnson, DVM, DACVIM
info@sonopath.com