



PATIENT

Abbie Sheldon

SPECIES

Canine

BREED

Golden Doodle

SEX

Spayed Female

AGE

7 Years

WEIGHT

68 lbs

INTERPRETED BY

Beth Johnson, DVM
DACVIM

IMAGING PERFORMED BY

Dr. Sheldon

HOSPITAL NAME

Advanced PetCare of
Oakland

REFERRING VET

Dr. Sheldon

INVOICE

75030

DATE

5/7/26

PRESENTING CLINICAL SIGNS

Pet presented with a right anal gland abscess. A firm nodule about 3 mm was noted in the right anal gland. Bloodwork including CA is pending.

ULTRASONOGRAPHIC EXAMINATION OF THE ABDOMEN

Urinary System

The urinary bladder is adequately distended with anechoic contents. No masses, inflammatory changes, echogenic sediment or cystoliths are observed. The urinary bladder, trigone and visible pelvic urethra are normal in thickness with a smooth mucosal surface.

The right kidney is normal in size (6.58 cm), shape and echogenicity. It has smooth peripheral margination. There is a normal 1:3 cortex to medulla ratio with appropriate corticomedullary distinction. There is no evidence of pyelectasia, mineral or infarcts observed.

The left kidney is normal in size (7.17 cm), shape and echogenicity. It has smooth peripheral margination. There is a normal 1:3 cortex to medulla ratio with appropriate corticomedullary distinction. There is no evidence of pyelectasia, mineral or infarcts observed.

Adrenal Glands

The right adrenal gland is normal in size (1.0 cm at cranial pole and 0.78 cm at caudal pole), shape and overall architecture, echogenicity and echotexture. Visible surrounding vasculature appears normal.

The left adrenal gland is normal in size (0.43 cm at cranial pole and 0.59 cm at caudal pole), shape and overall architecture, echogenicity and echotexture. Visible surrounding vasculature appears normal.

Spleen

The spleen is subjectively normal in size with a normal smooth capsular contour. Parenchyma is appropriately finely textured and homogenous with normal echogenicity relative to surrounding tissue (hyperechoic to liver). No focal nodules or masses are observed. Splenic vasculature appears normal.

Liver

The liver is subjectively normal in size with normal smooth curvilinear peripheral contour. Parenchyma is appropriately hypoechoic to the spleen in echogenicity and appropriately mildly coarse and homogenous in echotexture. No focal lesions are observed. Visible vasculature and biliary tree appear normal without distension or congestion.

Gallbladder is moderately distended with anechoic bile as well as suspended and gravity dependent echogenic debris. The wall is subjectively mildly thick, echogenic, and irregular. There is no evidence of cystic or CBD dilation. There is no evidence of effusion or inflammation.

Gastrointestinal

The visible stomach wall is normal in thickness and layering. The lumen of the stomach is mildly distended with a small to moderate amount of echogenic non-shadowing luminal contents and gas consistent with normal ingesta. There is no evidence of obstruction, foreign material or infiltrative disease. Pyloric outflow tract appears patent.



PATIENT

Abbie Sheldon

SPECIES

Canine

BREED

Golden Doodle

SEX

Spayed Female

AGE

7 Years

WEIGHT

68 lbs

INTERPRETED BY

Beth Johnson, DVM
DACVIM

IMAGING PERFORMED BY

Dr. Sheldon

HOSPITAL NAME

Advanced PetCare of
Oakland

REFERRING VET

Dr. Sheldon

INVOICE

75030

DATE

5/7/26

The visible small intestines are normal in wall thickness and layering. Small intestinal motility appears adequate (1-3 contractions per min). The lumen is mildly distended with echogenic non-shadowing luminal contents and gas consistent with normal ingesta/chyme. There is no evidence of obstruction, foreign material or infiltrative disease.

The visible colon is normal in wall thickness (< 0.2 cm) and layering. Contents are consistent with normal formed feces and gas.

Pancreas

The pancreas that is observed appears appropriately isoechoic to surrounding omental fat. Visible capsule is smooth and normal in contour. Visible pancreatic parenchyma is homogenous and unremarkable. There is no visible pancreatic duct dilation. There is no evidence of active peripancreatic inflammation.

Free Abdomen

There is no visible free peritoneal effusion noted in these images.

Medial iliac lymph nodes are prominent in size with swollen capsular contour. Normal elongated shape (length to width ratio) is maintained. There is no loss of parenchymal detail.

ULTRASONOGRAPHIC FINDINGS

- Moderately reactive medial iliac lymph nodes – infiltrative neoplastic disease cannot be ruled out but is considered less likely.
- Mild to moderate gallbladder debris - Cholecystic debris is of unknown clinical significance. It can be seen with biliary stasis from fasting or illness. Cholecystic debris is not necessarily related to hepatobiliary disease. Echogenic bile is most commonly an incidental finding in dogs and should be interpreted in combination with clinical signs such as nausea, inappetence, cranial abdominal discomfort and/or laboratory changes such as increased ALP and/or increased Tbili.

INTERPRETATION OF THE FINDINGS & FURTHER RECOMMENDATIONS

The lymphadenopathy described above could be a benign reactive change secondary to the reported anal gland infection, although given the reported adrenal gland nodule, infiltrative neoplasia and/or even a metastatic lymph node can't be ruled out. Therefore, recommendations include:

Three view thoracic radiographs are recommended for further assessment of cardio-pulmonary status as well as to further evaluate for any evidence of metastatic disease, if not recently evaluated.

If the anal gland nodule persists beyond full resolution of the reported infection, tissue sampling/biopsy of the nodule/anal gland as well as fine needle aspirates of the enlarged lymph node could all be considered if patient's coagulation status is appropriate.



PATIENT

Abbie Sheldon

SPECIES

Canine

BREED

Golden Doodle

SEX

Spayed Female

AGE

7 Years

WEIGHT

68 lbs

INTERPRETED BY

Beth Johnson, DVM
DACVIM

IMAGING PERFORMED BY

Dr. Sheldon

HOSPITAL NAME

Advanced PetCare of
Oakland

REFERRING VET

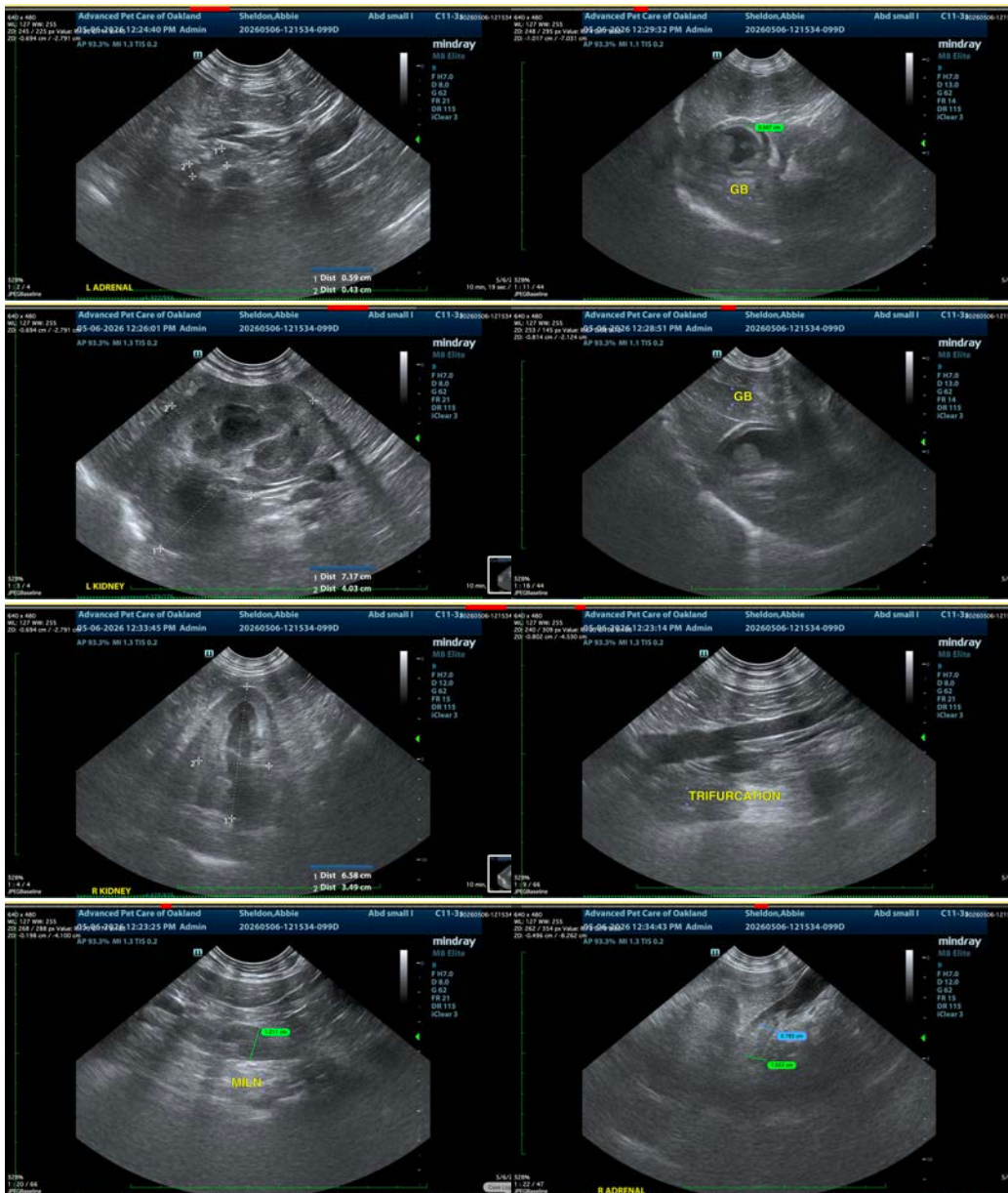
Dr. Sheldon

INVOICE

75030

DATE

5/7/26



The information and recommendations provided are based on the images presented by the referring veterinarian/sonographer. No evaluation can be communicated regarding pathology that was not visible in the image/video clips provided.

Thank you for this referral. If the clinical or image interpretation does not parallel your findings or if I can be of any further assistance please contact me.

Beth Johnson, DVM, DACVIM
info@sonopath.com