



PATIENT

Winston King

SPECIES

Canine

BREED

Golden Retriever

SEX

Neutered Male

AGE

8 Years

WEIGHT

37 kg

INTERPRETED BY

Beth Johnson, DVM
DACVIM

IMAGING PERFORMED BY

Dr. Sarah Barthelemy

HOSPITAL NAME

Signal Hill Animal Clinic

REFERRING VET

Dr. Devall

INVOICE

75002

DATE

5/6/26

PRESENTING CLINICAL SIGNS

Clinically normal. Recheck AUS to monitor small splenic nodule. Previous scan read by Sonopath May 20,2025

ULTRASONOGRAPHIC EXAMINATION OF THE ABDOMEN

Urinary System

The urinary bladder is adequately distended with anechoic contents. No masses, inflammatory changes, echogenic sediment or cystoliths are observed. The urinary bladder, trigone and visible pelvic urethra are normal in thickness with a smooth mucosal surface.

Prostate is normal in size, echotexture and echogenicity for a neutered male.

The right kidney is normal is size (6.75 cm), shape and echogenicity. It has smooth peripheral margination. There is a normal 1:3 cortex to medulla ratio with appropriate corticomedullary distinction. There is no evidence of pyelectasia, mineral or infarcts observed.

The left kidney is normal is size (6.87 cm), shape and echogenicity. It has smooth peripheral margination. There is a normal 1:3 cortex to medulla ratio with appropriate corticomedullary distinction. There is no evidence of pyelectasia, mineral or infarcts observed.

Adrenal Glands

The right adrenal gland is normal in size (0.65 cm at cranial pole and 0.55 cm at caudal pole), shape and overall architecture, echogenicity and echotexture. Visible surrounding vasculature appears normal.

The left adrenal gland is normal in size (0.51 cm at cranial pole and 0.57 cm at caudal pole), shape and overall architecture, echogenicity and echotexture. Visible surrounding vasculature appears normal.

Spleen

The spleen is subjectively normal in size with a normal smooth capsular contour. Parenchyma is appropriately finely textured and homogenous with normal echogenicity relative to surrounding tissue (hyperechoic to liver). There are I believe two subtle, mildly heterogeneous, primarily hypo- to anechoic non-capsule disrupting densities/nodules in the spleen, one measuring 0.70 cm x 1.1 cm in size and the other measuring 1.0 cm x 1.4 cm in size. I can't be certain that I'm not seeing the same nodule, however, in two different views. Splenic vasculature appears normal.

Liver

The liver is subjectively normal in size with normal smooth curvilinear peripheral contour. Parenchyma is appropriately hypoechoic to the spleen in echogenicity and appropriately mildly coarse and homogenous in echotexture. No focal lesions are observed. Visible vasculature and biliary tree appear normal without distension or congestion.

The gallbladder is unable to be well visualized in these images.

Gastrointestinal

The visible stomach wall is normal in thickness and layering. The lumen of the stomach is empty with no evidence of obstruction, foreign material or infiltrative disease. Pyloric outflow tract appears patent.



PATIENT

Winston King

SPECIES

Canine

BREED

Golden Retriever

SEX

Neutered Male

AGE

8 Years

WEIGHT

37 kg

INTERPRETED BY

Beth Johnson, DVM
DACVIM

IMAGING PERFORMED BY

Dr. Sarah Barthelmy

HOSPITAL NAME

Signal Hill Animal Clinic

REFERRING VET

Dr. Devall

INVOICE

75002

DATE

5/6/26

The visible small intestines are normal in wall thickness and layering. Small intestinal motility appears adequate (1-3 contractions per min). The lumen of the small intestine is empty with no evidence of obstruction, foreign material or infiltrative disease.

The visible colon is normal in wall thickness (< 0.2 cm) and layering. Contents are consistent with normal formed feces and gas.

Pancreas

The pancreas that is observed appears appropriately isoechoic to surrounding omental fat. Visible capsule is smooth and normal in contour. Visible pancreatic parenchyma is homogenous and unremarkable. There is no visible pancreatic duct dilation. There is no evidence of active peripancreatic inflammation.

Free Abdomen

There is no visible free peritoneal effusion noted in these images.

There is no apparent pathologic lymphadenopathy noted in these images.

ULTRASONOGRAPHIC FINDINGS

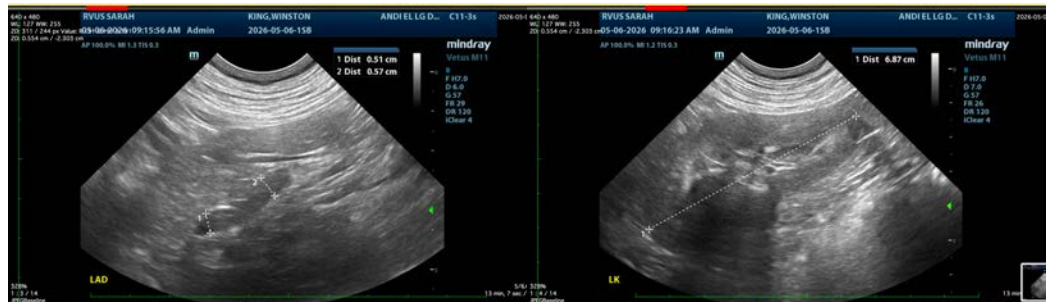- Hypo to anechoic splenic nodules – likely represents a benign lesion such as a cyst, hematoma, nodular hyperplasia, extramedullary hematopoiesis, etc., however while considered less likely, infiltrative neoplasia can mimic benign lesions and cannot be ruled out. *The nodule/nodules appear relatively static in size to previous studies, including the last one, which mentioned two separate nodules of similar size to the ones seen today.

INTERPRETATION OF THE FINDINGS & FURTHER RECOMMENDATIONS

Tissue sampling i.e., fine needle aspirates of the nodules could still be considered if patient's coagulation status is appropriate.

Three view thoracic radiographs are recommended for further assessment of cardio-pulmonary status as well as to further evaluate for any evidence of metastatic disease, if not recently evaluated.

Otherwise, continued monitoring is recommended.





PATIENT

Winston King

SPECIES

Canine

BREED

Golden Retriever

SEX

Neutered Male

AGE

8 Years

WEIGHT

37 kg

INTERPRETED BY

Beth Johnson, DVM
DACVIM

IMAGING PERFORMED BY

Dr. Sarah Barthelemy

HOSPITAL NAME

Signal Hill Animal Clinic

REFERRING VET

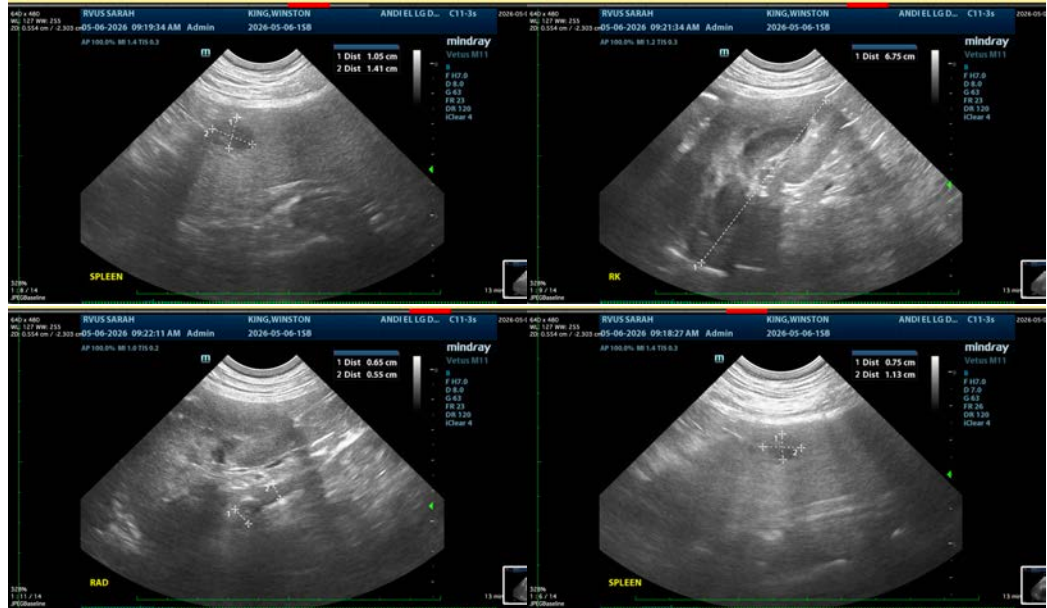
Dr. Devall

INVOICE

75002

DATE

5/6/26



The information and recommendations provided are based on the images presented by the referring veterinarian/sonographer. No evaluation can be communicated regarding pathology that was not visible in the image/video clips provided.

Thank you for this referral. If the clinical or image interpretation does not parallel your findings or if I can be of any further assistance please contact me.

Beth Johnson, DVM, DACVIM
info@sonopath.com