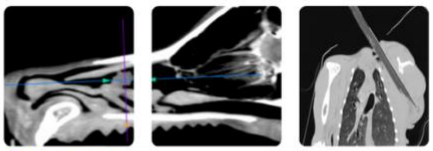

Teleradiology
Educational Teleconsultation Services™

PATIENT
Guiness Appel

SPECIES
Canine

BREED
Labrador

SEX
Neutered Male

AGE
8 Years

WEIGHT
42.1 kg

INTERPRETED BY
Beth Johnson, DVM, DACVIM (SAIM)

IMAGING PERFORMED BY
Amanda Stewart

HOSPITAL NAME
Buck AH

REFERRING VET
Dr. Sommers

INVOICE
35957

DATE
5/6/26

PRESENTING CLINICAL SIGNS

Findings: slower on walks, very slow, hunched, not wanting food or treats, very sudden change, noticed rapid heart rate, seems weak.

Current Medications: Omega 3

Abnormal PE/Chem/CBC/UA Results: Low eosinophils, low normal RBCs, K 3.3, TT4 7 Radiographic Findings NA Primary Question to Be Answered in This Exam mass vs other

ULTRASONOGRAPHIC EXAMINATION OF THE ABDOMEN

Urinary System

Urinary bladder is adequately distended with anechoic contents. No masses, inflammatory changes, echogenic sediment or cystoliths are observed. The urinary bladder, trigone and visible pelvic urethra are normal in thickness with a smooth mucosal surface.

Prostate is normal in size, echotexture and echogenicity for a neutered male.

Left kidney is normal in size (7.5 cm), shape and echogenicity. It has smooth peripheral margination. There is a normal 1:3 cortex to medulla ratio with appropriate corticomedullary distinction. There is no evidence of pyelectasia, mineral or infarcts observed.

Right kidney is normal in size (7.6 cm), shape and echogenicity. It has smooth peripheral margination. There is a normal 1:3 cortex to medulla ratio with appropriate corticomedullary distinction. There is no evidence of pyelectasia, mineral or infarcts observed.

Adrenal Glands

Left adrenal gland is normal in size (0.74 cm at cranial pole and 0.71 cm at caudal pole), shape and overall architecture, echogenicity and echotexture. Visible surrounding vasculature appears normal. A hyperechoic nodule is noted in the cranial pole of the left adrenal gland. Nodule does not disrupt normal shape and/or architecture.

Right adrenal gland is unable to be well visualized.

Spleen

Spleen is subjectively large in size with a normal smooth capsular contour. Parenchyma is appropriately finely textured and homogenous with normal echogenicity relative to surrounding tissue (hyperechoic to liver). No focal nodules or masses are observed. Splenic vasculature appears normal. The spleen is folded upon itself, which is a positional non-pathologic variant.

Liver

Liver is subjectively normal in size with normal smooth curvilinear peripheral contour. Parenchyma is appropriately hypoechoic to the spleen in echogenicity and appropriately mildly coarse and homogenous in echotexture. No focal lesions are observed. Visible vasculature and biliary tree appear normal without distension or congestion.

Gallbladder is non-distended in size. The wall is smooth without visible thickening. Luminal contents are primarily anechoic. There is no evidence of cystic or common bile duct dilation.

PATIENT
Guiness Appel

SPECIES
Canine

BREED
Labrador

SEX
Neutered Male

AGE
8 Years

WEIGHT
42.1 kg

INTERPRETED BY
Beth Johnson, DVM, DACVIM (SAIM)

IMAGING PERFORMED BY
Amanda Stewart

HOSPITAL NAME
Buck AH

REFERRING VET
Dr. Sommers

INVOICE
35957

DATE
5/6/26

Gastrointestinal

The visible stomach wall is normal in thickness and layering. The lumen of the stomach is empty with no evidence of obstruction, foreign material or infiltrative disease. Pyloric outflow tract appears patent.

The visible small intestines are normal in wall thickness and layering. Small intestinal motility appears adequate (1-3 contractions per min). The lumen of the small intestine is empty with no evidence of obstruction, foreign material or infiltrative disease.

The visible colon is normal in wall thickness (< 0.2 cm) and layering. Contents are consistent with normal formed feces and gas.

Pancreas

The observed pancreas is prominent (enlarged) in size, hypoechoic to surrounding tissue and irregular in shape with a swollen undulating contour. Enhanced hyperechoic ill-defined surrounding fat is noted.

Free Abdomen

There is no visible free peritoneal effusion noted in these images.

There is no apparent pathologic lymphadenopathy noted in these images.

In the cranial abdomen, there is an approximately 6.1 cm x 7.1 cm homogenous coarse hypoechoic mass, surrounded by free fluid and enhanced hyperechoic mesentery and fat. This mass is adjacent to, and in some views, appears to touch and potentially even originate from the spleen, although it lies in the area of the prominent pancreas and could represent a markedly prominent swollen inflamed pancreas, or even pancreatic mass.

ULTRASONOGRAPHIC FINDINGS

Primary Findings

- Suspect moderate to severe acute pancreatitis with a possible pancreatic mass- Both benign inflammatory differentials and infiltrative neoplastic differentials are possible if it's a pancreatic mass, although the mass, as described above, could be splenic in origin, with similarly both benign and/or neoplastic, even malignant differentials being possible. Free fluid and enhanced mesentery in the area are consistent with a focal peritonitis/inflammatory change.
- Marked/significant splenomegaly- can be associated with congestion caused by sedation (if sedated) but can also be associated with diffuse infiltrative disease. Both benign conditions such as extramedullary hematopoiesis, lymphoid hyperplasia, as well as infiltrative neoplastic diseases such as round cell neoplasia should be considered.

Secondary Findings

- Hyperechoic adrenal nodule in the cranial pole of the left adrenal gland- Differentials include primary adrenal cortical adenoma or adenocarcinoma, pheochromocytoma, myelolipoma, adrenal hyperplasia secondary to pituitary disease or metastatic disease. Ultrasound alone

PATIENT

Guiness Appel

SPECIES

Canine

BREED

Labrador

SEX

Neutered Male

AGE

8 Years

WEIGHT

42.1 kg

INTERPRETED BY

Beth Johnson, DVM, DACVIM (SAIM)

IMAGING PERFORMED BY

Amanda Stewart

HOSPITAL NAME

Buck AH

REFERRING VET

Dr. Sommers

INVOICE

35957

DATE

5/6/26

cannot differentiate between functional and non-functional nodules and/or between benign and malignant disease. Small nodules without other evidence of abdominal disease (to suggest metastatic disease) and/or clinical signs (to suggest adrenal disease) are most often incidental and should be monitored.

INTERPRETATION OF THE FINDINGS & FURTHER RECOMMENDATIONS

Three view thoracic radiographs are recommended for further assessment of cardio-pulmonary status as well as to further evaluate for any evidence of metastatic disease, if not recently evaluated.

A quantitative PLI is recommended if not already evaluated.

Fine needle aspirates of the spleen, as well as the cranial abdominal mass are recommended if patient's coagulation status is appropriate.

Pending results of above evaluation, advanced imaging, such as an abdominal contrast CT scan may be helpful in further staging/planning additional intervention up to, and including, potentially surgery if indicated.

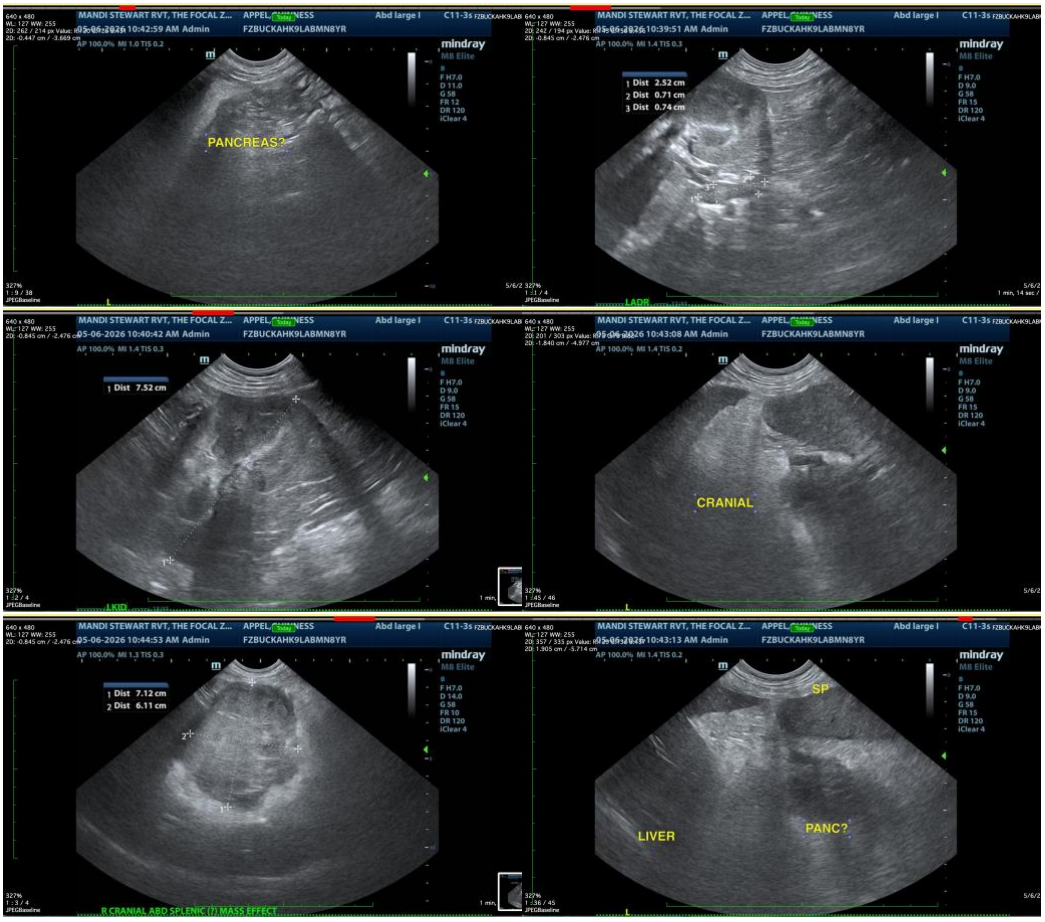

The Focal Zone
FUELED BY SONOPATH VETERINARY ULTRASOUND

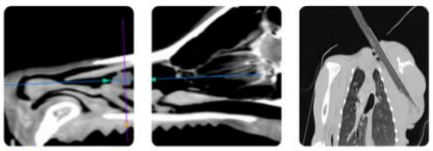

Teleradiology
Educational Teleconsultation Services™

SonoPath
FOSTERING THE ART OF VETERINARY MEDICINE™
www.thefocalzone.com
info@thefocalzone.com
289.808.2608

PATIENT

Guiness Appel

SPECIES

Canine

BREED

Labrador

SEX

Neutered Male

AGE

8 Years

WEIGHT

42.1 kg

INTERPRETED BY

Beth Johnson, DVM, DACVIM (SAIM)

IMAGING PERFORMED BY

Amanda Stewart

HOSPITAL NAME

Buck AH

REFERRING VET

Dr. Sommers

INVOICE

35957

DATE

5/6/26

The information and recommendations provided are based on the images presented by the referring veterinarian/sonographer. No evaluation can be communicated regarding pathology that was not visible in the image/video clips provided.

Thank you for this referral. If the clinical or image interpretation does not parallel your findings or if I can be of any further assistance please contact me.

Beth Johnson, DVM DACVIM

info@sonopath.com