

**PATIENT**

Dino Foss

SPECIES

Canine

BREED

Standard Poodle

SEX

Neutered Male

AGE

9 Years 3 Months

WEIGHT

65 lbs

INTERPRETED BYBeth Johnson, DVM
DACVIM**IMAGING
PERFORMED BY**

Amanda Crook

HOSPITAL NAMERivers Edge Pet
Medical Center**REFERRING VET**

Dr. Melody Williams

INVOICE

74998

DATE

5/6/26

PRESENTING CLINICAL SIGNS

Diagnosed by biopsy with immune-mediated hepatitis several years ago. Has been stable for a long time. Grade 3/6 systolic murmur on the left ausculted yesterday; has been present at a grade 1-2 for many years. Recent hx mid-back discomfort. Clinically doing well. Current Medications: Ursodiol, Denamarin, Prednisone 5 mg EOD. Doppler BP: 152, 148, 150

Abnormal PE/Chem/CBC/UA Results: Laboratory Abnormalities Labs this month show increase in neutrophils and WBCs, ALT very slightly elevated (139). Radiographic Findings: Chest radiographs taken 5/4/26 show no significant changes, VHS was 9.

ULTRASONOGRAPHIC EXAMINATION OF THE ABDOMEN**Urinary System**

The urinary bladder is adequately distended with anechoic contents. No masses, inflammatory changes, echogenic sediment or cystoliths are observed. The urinary bladder, trigone and visible pelvic urethra are normal in thickness with a smooth mucosal surface.

The area of the prostate is examined without evident prostatic pathology.

The right kidney is normal in size (6.83 cm), shape and echogenicity. It has smooth peripheral margination. There is a normal 1:3 cortex to medulla ratio with appropriate corticomedullary distinction. There is no evidence of pyelectasia, mineral or infarcts observed.

The left kidney is normal in size (6.56 cm), shape and echogenicity. It has smooth peripheral margination. There is a normal 1:3 cortex to medulla ratio with appropriate corticomedullary distinction. There is no evidence of pyelectasia, mineral or infarcts observed.

Adrenal Glands

The right adrenal gland is normal in size (0.86 cm at cranial pole and 0.55 cm at caudal pole), shape and overall architecture, echogenicity and echotexture. Visible surrounding vasculature appears normal.

The left adrenal gland is normal in size (0.57 cm at cranial pole and 0.54 cm at caudal pole), shape and overall architecture, echogenicity and echotexture. Visible surrounding vasculature appears normal.

Spleen

Spleen is subjectively large in size (2.0 cm thick at the hilus) with a mildly swollen but smooth capsule. Parenchyma is normal and homogenous in echogenicity and echotexture. No focal nodules or masses are observed. Splenic vasculature appears normal.

Liver

The liver is subjectively normal in size with normal smooth curvilinear peripheral contour. Parenchyma is appropriately hypoechoic to the spleen in echogenicity and appropriately mildly coarse and homogenous in echotexture. No focal lesions are observed. Visible vasculature and biliary tree appear normal without distension or congestion.

The gallbladder is non-distended in size. The wall is smooth without visible thickening. Luminal contents are primarily anechoic. There is no evidence of cystic or common bile duct dilation.



PATIENT

Dino Foss

SPECIES

Canine

BREED

Standard Poodle

SEX

Neutered Male

AGE

9 Years 3 Months

WEIGHT

65 lbs

INTERPRETED BY

Beth Johnson, DVM
DACVIM

IMAGING PERFORMED BY

Amanda Crook

HOSPITAL NAME

Rivers Edge Pet
Medical Center

REFERRING VET

Dr. Melody Williams

INVOICE

74998

DATE

5/6/26

Gastrointestinal

The visible stomach wall is normal in thickness and layering. The lumen is mildly distended with primarily fluid as well as some echogenic non-shadowing luminal contents and gas consistent with normal chyme. There is no evidence of obstruction, foreign material, or infiltrative disease. Pyloric outflow tract appears patent.

The visible small intestines are normal in wall thickness and layering. Small intestinal motility appears adequate (1-3 contractions per min). The lumen of the small intestine is empty with no evidence of obstruction, foreign material or infiltrative disease.

The visible colon is normal in wall thickness (< 0.2 cm) and layering. Contents are consistent with normal formed feces and gas.

Pancreas

The pancreas that is observed appears appropriately isoechoic to surrounding omental fat. Visible capsule is smooth and normal in contour. Visible pancreatic parenchyma is homogenous and unremarkable. There is no visible pancreatic duct dilation. There is no evidence of active peripancreatic inflammation.

Free Abdomen

There is no visible free peritoneal effusion noted in these images.

There is no apparent pathologic lymphadenopathy noted in these images.

ULTRASONOGRAPHIC FINDINGS

- Subjective mild splenomegaly– can be associated with congestion caused by sedation (if sedated) but can also be associated with diffuse infiltrative disease. Both benign conditions such as extramedullary hematopoiesis, lymphoid hyperplasia, as well as infiltrative neoplastic diseases such as round cell neoplasia should be considered.
- An obvious cause for the reported increased liver enzymes is not identified in these images. Microscopic disease such as Leptospirosis, bacterial cholangiohepatitis, chronic active hepatitis, copper-associated hepatotoxicity, other hepatotoxicity, other reactive hepatopathy, infiltrative neoplasia (considered unlikely), etc. cannot be definitively ruled out.

INTERPRETATION OF THE FINDINGS & FURTHER RECOMMENDATIONS

Fine needle aspirates of the spleen could be considered if patient's coagulation status is appropriate.

Bile acids could be considered if patient's total bilirubin is not increased.

Testing for Leptospirosis could be considered.

Having said all of that, given patient's history combined with reported laboratory changes, an early or emerging secondary infection involving the liver could be brewing, and in addition to supportive/symptomatic medical management of clinical signs, hepatic nutraceuticals, etc., empirical antibiotics could be considered while monitoring liver enzymes for improvement.



PATIENT

Dino Foss

SPECIES

Canine

BREED

Standard Poodle

SEX

Neutered Male

AGE

9 Years 3 Months

WEIGHT

65 lbs

INTERPRETED BY

Beth Johnson, DVM
DACVIM

IMAGING PERFORMED BY

Amanda Crook

HOSPITAL NAME

Rivers Edge Pet Medical Center

REFERRING VET

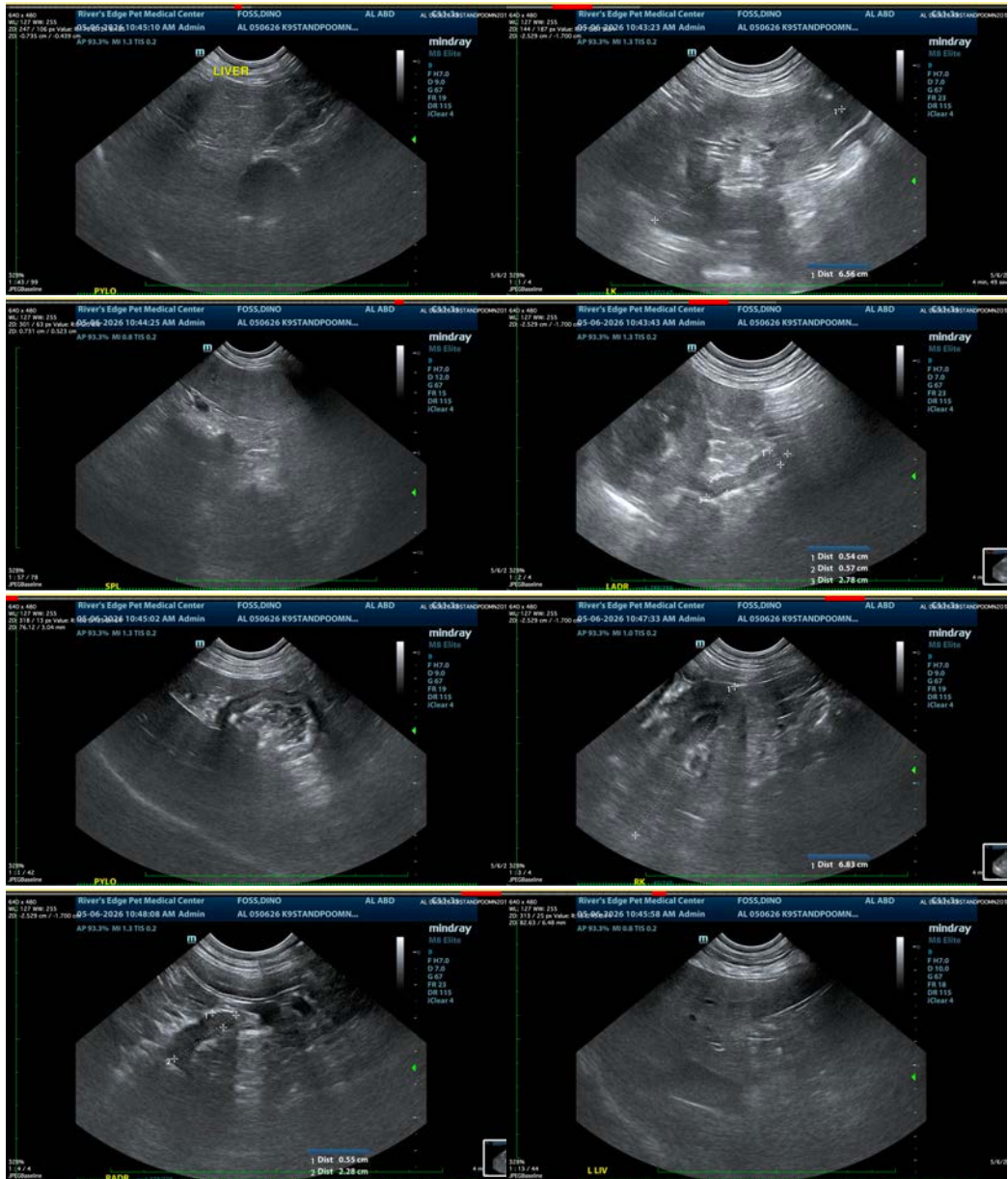
Dr. Melody Williams

INVOICE

74998

DATE

5/6/26



The information and recommendations provided are based on the images presented by the referring veterinarian/sonographer. No evaluation can be communicated regarding pathology that was not visible in the image/video clips provided.

Thank you for this referral. If the clinical or image interpretation does not parallel your findings or if I can be of any further assistance please contact me.

Beth Johnson, DVM, DACVIM
info@sonopath.com