



## PATIENT

Violet Bessette

## SPECIES

Feline

## BREED

Snowshoe

## SEX

Spayed Female

## AGE

10 Years 4 Months

## WEIGHT

7.5

## INTERPRETED BY

Beth Johnson, DVM  
DACVIM

## IMAGING PERFORMED BY

Dr. Miranda Fritz

## HOSPITAL NAME

Richmond Animal  
Hospital

## REFERRING VET

Dr. Miranda Fritz

## INVOICE

74951

## DATE

5/5/26

## PRESENTING CLINICAL SIGNS

P presented for NP/NC end of Dec 2025. P was a breeding cat prior and limited vet history prior to adoption last fall. O states that p does occasionally vomit especially if given dry food. P has marked periodontal disease and resorptive lesions. Full blood work done and wnl. P has now had multiple episodes of vomiting and decreased appetite. Most recent started last week. P vomiting mostly bile and did have diarrhea. Diarrhea resolved with GI biome but vomiting and decreased appetite persisted. P fasted today for recheck x-rays and AUS.

Abnormal PE/Chem/CBC/UA Results: PE: mild weight loss, periodontal disease and crown resorptive lesions CBC - wnl Chem - wnl proBNP - 24 (wnl) Fecal - NOS Three view full body x-rays- NSF

## ULTRASONOGRAPHIC EXAMINATION OF THE ABDOMEN

### Urinary System

The urinary bladder is adequately distended with anechoic contents. No masses, inflammatory changes, echogenic sediment or cystoliths are observed. The urinary bladder, trigone and visible pelvic urethra are normal in thickness with a smooth mucosal surface.

Kidneys are bilaterally small, irregular and diffusely echogenic with decreased corticomedullary distinction and poor visualization of internal architecture. There is no pyelectasia noted and no mineral is observed. Left kidney measures 3.3 cm. Right measures 3.1 cm.

### Adrenal Glands

The areas of the adrenal glands are examined without evident adrenal gland pathology.

### Spleen

The spleen is subjectively normal in size with a normal smooth capsular contour. Parenchyma is appropriately finely textured and homogenous with normal echogenicity relative to surrounding tissue (hyperechoic to liver). No focal nodules or masses are observed. Splenic vasculature appears normal.

### Liver

The liver is subjectively normal in size with normal smooth curvilinear peripheral contour. Parenchyma is appropriately hypoechoic to the spleen in echogenicity and appropriately mildly coarse and homogenous in echotexture. No focal lesions are observed. Visible vasculature and biliary tree appear normal without distension or congestion.

The gallbladder is non-distended in size. The wall is smooth without visible thickening. Luminal contents are primarily anechoic. There is no evidence of cystic or common bile duct dilation.

### Gastrointestinal

The visible stomach wall is normal in thickness and layering. The lumen of the stomach is empty with no evidence of obstruction, foreign material or infiltrative disease. Pyloric outflow tract appears patent.

The visible small intestine demonstrates areas of moderately thick muscularis layer relative to mucosa (disruption of the normal 1:3 muscularis:mucosa ratio). Small intestinal submucosa is slightly irregular, thick and hyperechoic, without evident loss of layering appreciated. The lumen of the small intestine is empty with no evidence of obstruction or foreign material.



## PATIENT

Violet Bessette

## SPECIES

Feline

## BREED

Snowshoe

## SEX

Spayed Female

## AGE

10 Years 4 Months

## WEIGHT

7.5

## INTERPRETED BY

Beth Johnson, DVM  
DACVIM

## IMAGING PERFORMED BY

Dr. Miranda Fritz

## HOSPITAL NAME

Richmond Animal  
Hospital

## REFERRING VET

Dr. Miranda Fritz

## INVOICE

74951

## DATE

5/5/26

The visible colon is normal in wall thickness (< 0.2 cm) and layering. Contents are consistent with normal formed feces and gas.

### **Pancreas**

Pancreas is prominent (enlarged) in size, hypoechoic to surrounding tissue and has a mildly irregular undulating contour. Parenchyma is coarse with mixed echogenic remodeling noted. No pancreatic duct dilation is noted.

### **Free Abdomen**

There is no visible free peritoneal effusion noted in these images.

Mesenteric lymph nodes are prominent in size with swollen capsular contour. Normal elongated shape (length to width ratio) is maintained. There is no loss of parenchymal detail.

### **ULTRASONOGRAPHIC FINDINGS**

- Moderate inflammatory bowel disease (IBD) pattern – Thick muscularis has been reported with infiltrative bowel disease including both benign inflammatory disease as well as infiltrative neoplasia such as lymphoma. No loss of layering or distinct characteristics of malignancy are present. Therefore, differentials cannot be further ranked without tissue sampling.
- Concurrent chronic low-grade smoldering pancreatitis can't be ruled out and should be suspected in the face of appropriate clinical signs.
- Mild reactive mesenteric lymph nodes – infiltrative neoplastic disease cannot be ruled out but is considered less likely.
- Moderate bilateral chronic kidney disease changes.

### **INTERPRETATION OF THE FINDINGS & FURTHER RECOMMENDATIONS**

If not recently evaluated, a urinalysis and, if indicated based on urinalysis results, urine culture is recommended. If protein is present in an otherwise quiet sediment, protein quantification with a urine protein to creatinine ratio is recommended.

A T4 +/- free T4 is recommended.

A gastrointestinal malabsorption panel (including cobalamin, folate, TLI and PLI) to Texas A&M GI Laboratory is recommended for further evaluation of GI and pancreatic function.

Ideally, biopsies of the GI tract, being sure to include ileum if possible, are recommended to definitively diagnose and therefore manage the infiltrative bowel disease.

If biopsies cannot be obtained, empirical therapies could include a probiotic (if diarrhea is present, such as visbiome or proviable), empirical deworming with a 5-day course of Panacur and, if tolerated, a transition in diet, based on trial-and-error response, beginning with a hydrolyzed protein diet. Some patients respond to one brand/version of a hydrolyzed protein diet better than another brand, so several trials may be required.



**PATIENT**

Violet Bessette

**SPECIES**

Feline

**BREED**

Snowshoe

**SEX**

Spayed Female

**AGE**

10 Years 4 Months

**WEIGHT**

7.5

**INTERPRETED BY**

Beth Johnson, DVM  
DACVIM

**IMAGING PERFORMED BY**

Dr. Miranda Fritz

**HOSPITAL NAME**

Richmond Animal  
Hospital

**REFERRING VET**

Dr. Miranda Fritz

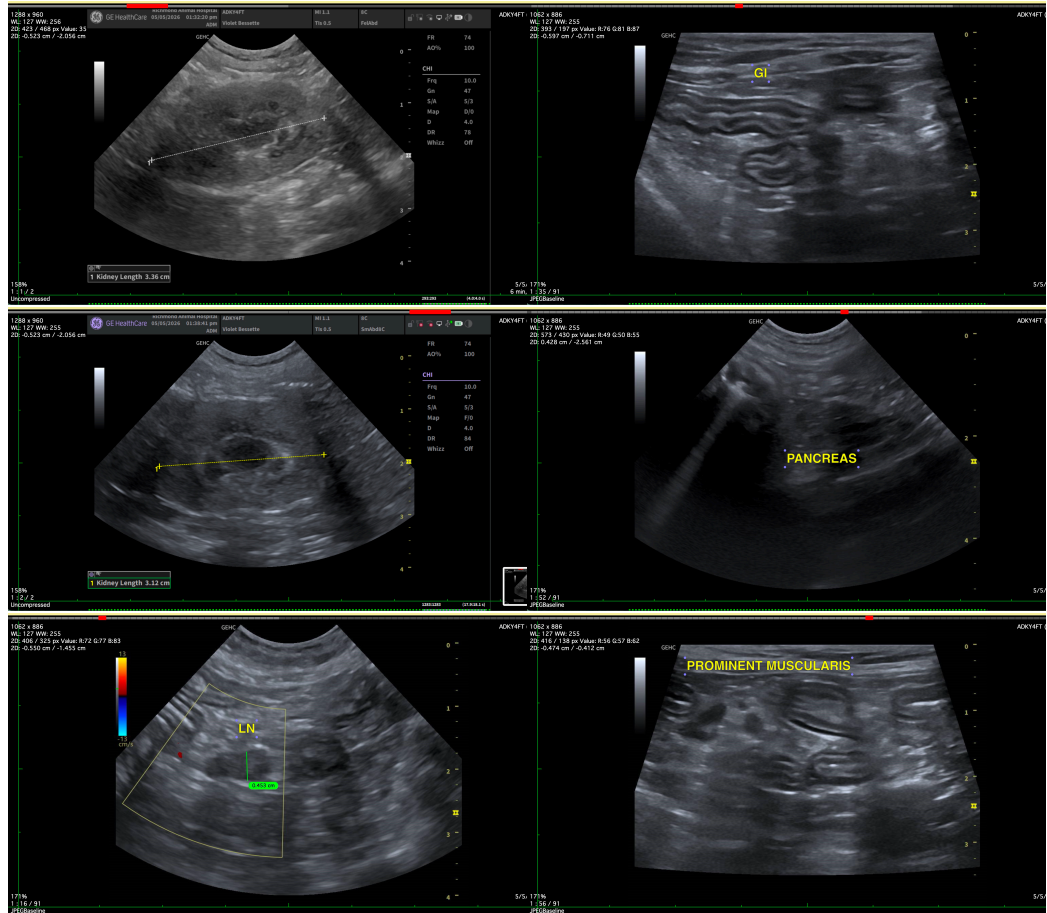
**INVOICE**

74951

**DATE**

5/5/26

Additional considerations could include cobalamin supplementation (unless cobalamin level is evaluated and supplementation is not warranted) and prednisolone (if not contraindicated based on patient contraindications, co-morbidities, etc.).



The information and recommendations provided are based on the images presented by the referring veterinarian/sonographer. No evaluation can be communicated regarding pathology that was not visible in the image/video clips provided.

Thank you for this referral. If the clinical or image interpretation does not parallel your findings or if I can be of any further assistance please contact me.

**Beth Johnson, DVM, DACVIM**  
info@sonopath.com