


DATE PRESENTING CLINICAL SIGNS

5/5/26

Patient History: Hiding, very skittish. Not going on walks. Not eating, lethargic, painful abdomen. Very gassy- some diarrhea. Hx of seizures- none for many years. Feeds hydrolyzed diet.

PATIENT

Jersey Davis

Current Medications: Gabapentin 100mg 1-2 BID, Phenobarb ½ gram 1 BID, Metronidazole 200mg BID.
Labwork Results: Attached, reported as elevated ALKP + low Phosphorus. CPK WNL. Urine- crustals, rest WNL.

SPECIES

Canine

Date of Previous IntraPet Ultrasound: No previous.
Sedation: Not required to complete full diagnostic ultrasound.
Stat Report: Not requested.
Imaging Performed by: Rachel Brillhart, RDMS.

BREED

Mixed

ULTRASONOGRAPHIC EXAMINATION OF THE ABDOMEN
Urinary System
SEX

Spayed Female

The urinary bladder is adequately distended with anechoic contents. No masses, inflammatory changes, echogenic sediment or cystoliths are observed. The urinary bladder, trigone and visible pelvic urethra are normal in thickness with a smooth mucosal surface.

AGE

3/16/16

Kidneys are overall normal in size and shape with smooth peripheral margination. A normal 1:3 cortex to medulla ratio is maintained. The medulla and cortices are uniform in texture with some mild increased cortical echogenicity and mild loss of corticomedullary distinction, expected in this age patient. There is no evidence of pyelectasia, mineral or infarcts observed. Left kidney measures 5.5 cm. Right kidney measures 5.6 cm. A small cortical cyst is noted in the right kidney.

WEIGHT

45 lbs

INTERPRETED BY
Beth Johnson, DVM
DACVIM
Adrenal Glands

The right adrenal gland is normal in size (0.98 cm at cranial pole and 0.76 cm at caudal pole), shape and overall architecture, echogenicity and echotexture. Visible surrounding vasculature appears normal.

HOSPITAL NAME
Greenbrier Veterinary
Clinic

The left adrenal gland is normal in size (0.59 cm at cranial pole and 0.72 cm at caudal pole), shape and overall architecture, echogenicity and echotexture. Visible surrounding vasculature appears normal.

Spleen
REFERRING VET

Dr. Hubbard

Spleen is subjectively large in size with normal smooth margins. Parenchyma is normal in echogenicity with a diffusely coarse/heterogenous echotexture. Several representative nodules measure approximately 1-2 cm in diameter. Splenic vasculature appears normal.

Liver
INVOICE

74962

The liver is subjectively normal in size with normal smooth curvilinear peripheral contour. Parenchyma is appropriately hypoechoic to the spleen in echogenicity and appropriately mildly coarse and homogenous in echotexture. No focal lesions are observed. Visible vasculature and biliary tree appear normal without distension or congestion.

Gallbladder is moderately distended with anechoic bile as well as suspended and gravity dependent echogenic debris. The wall is smooth without visible thickening. There is no evidence of cystic or CBD dilation. There is no evidence of effusion or inflammation.

Gastrointestinal

The visible stomach wall is normal in thickness and layering. The lumen of the stomach is mildly distended with very echogenic reverberation artifact from intraluminal gas. There is no evidence of obstruction, foreign material, or infiltrative disease; however, visualization is partially inhibited by gas.

The visible small intestines are normal in wall thickness and layering. Small intestinal motility appears adequate (1-3 contractions per min). The lumen of the small intestine is empty with no evidence of obstruction, foreign material or infiltrative disease.

The visible colon is normal in wall thickness (< 0.2 cm) and layering. Contents are consistent with normal formed feces and gas.

Pancreas

The pancreas that is observed appears appropriately isoechoic to surrounding omental fat. Visible capsule is smooth and normal in contour. Visible pancreatic parenchyma is homogenous and unremarkable. There is no visible pancreatic duct dilation. There is no evidence of active peripancreatic inflammation.

Free Abdomen

There is no visible free peritoneal effusion noted in these images.

There is no apparent pathologic lymphadenopathy noted in these images.

The visible heart base (RA) and pericardium are unremarkable without obvious pathology noted in these images at this time. If cardiac function evaluation is desired, a full echocardiogram is recommended.

PRIMARY FINDINGS

- Coarse splenomegaly – can be associated with congestion caused by sedation (if sedated) but can also be associated with diffuse infiltrative disease. Both benign conditions such as extramedullary hematopoiesis, lymphoid hyperplasia, as well as infiltrative neoplastic diseases such as round cell neoplasia should be considered.
- Moderate gallbladder debris - Cholecystic debris is of unknown clinical significance. It can be seen with biliary stasis from fasting or illness. Cholecystic debris is not necessarily related to hepatobiliary disease. Echogenic bile is most commonly an incidental finding in dogs and should be interpreted in combination with clinical signs such as nausea, inappetence, cranial abdominal discomfort and/or laboratory changes such as increased ALP and/or increased Tbili.

SECONDARY FINDINGS

- Mild age related kidney changes with a small cortical cyst in the right kidney.

INTERPRETATION OF THE FINDINGS & FURTHER RECOMMENDATIONS

The changes described above are non-specific and relatively subtle without a definitive ultrasonographically visible intraabdominal explanation for patient's reported clinical history. Having said that, fine needle aspirates of the spleen could be considered if patient's coagulation status is appropriate.

Three view thoracic radiographs are recommended for further assessment of cardio-pulmonary status as well as to further evaluate for any evidence of metastatic disease, if not recently evaluated.

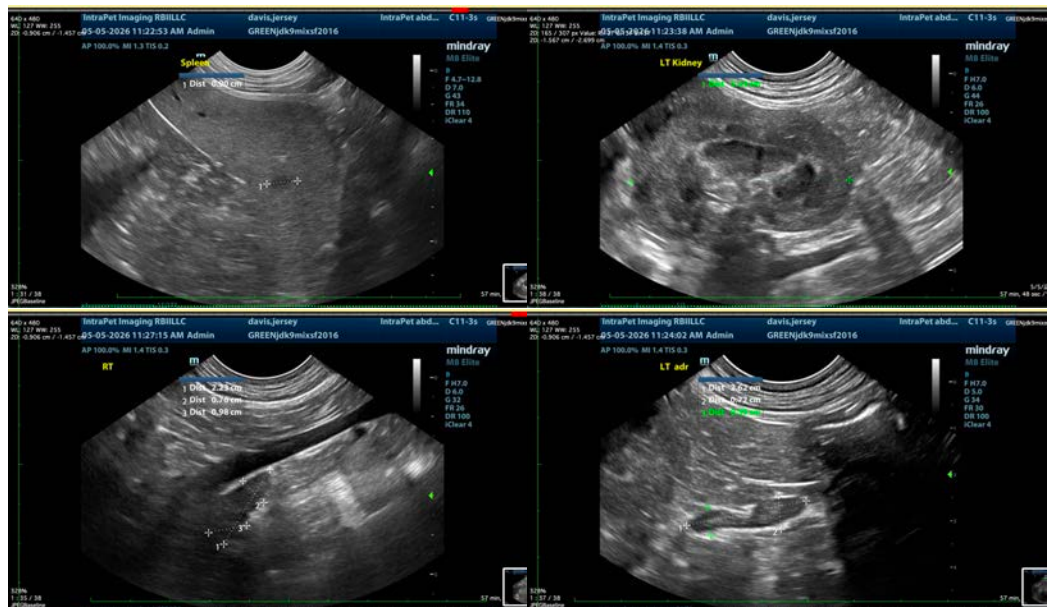
Pending results of the above workup, additional diagnostic considerations could include:

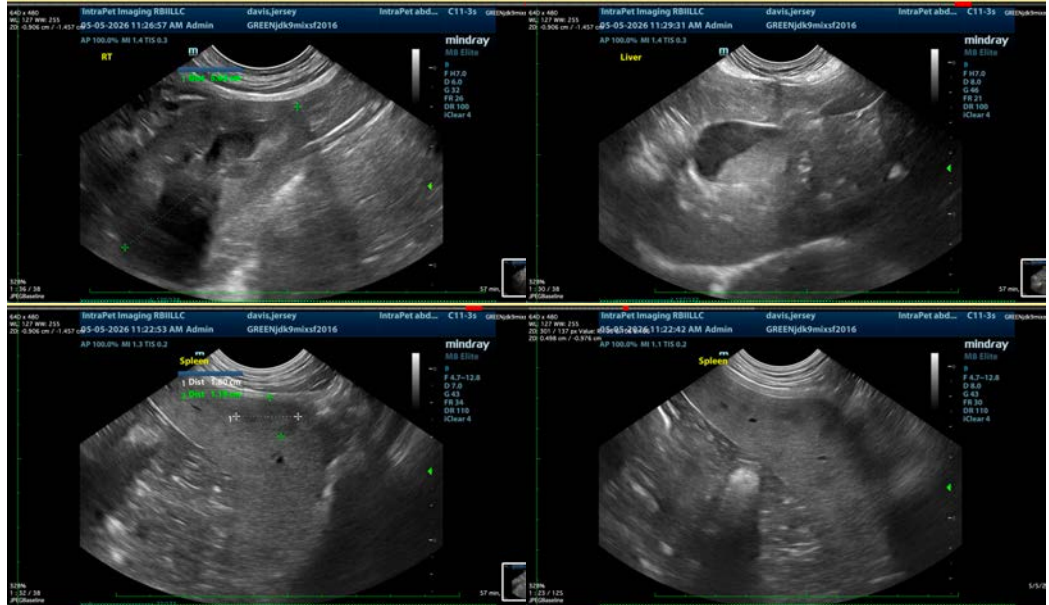
A gastrointestinal malabsorption panel (including cobalamin, folate, TLI and PLI) to Texas A&M GI Laboratory is recommended for further evaluation of GI and pancreatic function.

A baseline cortisol is recommended. If baseline cortisol is less than 2, a full ACTH stimulation test is recommended to rule out hypoadrenocorticism.

Additionally, if not recently evaluated, a thorough orthopedic/neuro/spinal pain evaluation could be considered to rule out pain or decreased mobility as a contributing factor.

Other than supportive/symptomatic medical management of clinical signs, further treatment recommendations are largely dependent on results of the above.





The information and recommendations provided are based on the images presented by the referring veterinarian/sonographer. No evaluation can be communicated regarding pathology that was not visible in the image/video clips provided.

Thank you for this referral. If the clinical or image interpretation does not parallel your findings or if I can be of any further assistance please contact me.

Beth Johnson, DVM, DACVIM
info@sonopath.com