



PATIENT

Hershey Lorencovitz

SPECIES

Canine

BREED

Labradoodle

SEX

Spayed Female

AGE

11 Years

WEIGHT

62.8 Pounds

INTERPRETED BY

Beth Johnson, DVM,
DACVIM (SAIM)

IMAGING PERFORMED BY

Vincent Ravancho,
CVT

HOSPITAL NAME

Whippany VH

REFERRING VET

Dr. Cordero

INVOICE

35950

DATE

5/5/26

PRESENTING CLINICAL SIGNS

History: Has lost >10 lbs since Jan. Decreased appetite and on/off diarrhea. Clinical findings - Did well on gastrobiome in April for a little bit but now back to decreased appetite and soft stool. Pt had MCT, tx w/ Stelfonta Jan 2023, tx w/ palladia 2025, tx w/ Vinblastine May 2024

Abnormal PE/Chem/CBC/UA Results: 4/4/26 - Chem TP 4.5, Alb 2.1, Alk P 229, U/A - pH 6.5, USG 1.042. 5/5/26 - Chem TP 4.7, Alb 2. CBC - WBC 22.62, Retic 6.4, Neuts 18.69, Mono 2.44

ULTRASONOGRAPHIC EXAMINATION OF THE ABDOMEN

Urinary System

Urinary bladder is adequately distended with anechoic contents. No masses, inflammatory changes, echogenic sediment or cystoliths are observed. The urinary bladder, trigone and visible pelvic urethra are normal in thickness with a smooth mucosal surface.

Left kidney is normal in size (5.5 cm), shape and echogenicity. It has smooth peripheral margination. There is a normal 1:3 cortex to medulla ratio with appropriate corticomedullary distinction. There is no evidence of pyelectasia, mineral or infarcts observed.

Right kidney is normal in size (6.2 cm), shape and echogenicity. It has smooth peripheral margination. There is a normal 1:3 cortex to medulla ratio with appropriate corticomedullary distinction. There is no evidence of pyelectasia, mineral or infarcts observed.

Adrenal Glands

Left adrenal gland is normal in size (0.8 cm at cranial pole and 0.6 cm at caudal pole), shape and overall architecture, echogenicity and echotexture. Visible surrounding vasculature appears normal.

Right adrenal gland is normal in size (1.3 cm at cranial pole and 0.6 cm at caudal pole), shape and overall architecture, echogenicity and echotexture. Visible surrounding vasculature appears normal.

Spleen

Spleen is subjectively normal in size with a normal smooth capsular contour. Parenchyma is appropriately finely textured and homogenous with normal echogenicity relative to surrounding tissue (hyperechoic to liver). No focal nodules or masses are observed. Splenic vasculature appears normal.

Liver

Liver is subjectively normal in size with normal smooth curvilinear peripheral contour. Parenchyma is appropriately hypoechoic to the spleen in echogenicity and appropriately mildly coarse and homogenous in echotexture. No focal lesions are observed. Visible vasculature and biliary tree appear normal without distension or congestion.

Gallbladder is non-distended in size. The wall is smooth without visible thickening. Luminal contents are primarily anechoic. There is no evidence of cystic or common bile duct dilation.

Gastrointestinal

The visible stomach wall is normal in thickness and layering. The lumen of the stomach is mildly distended with primarily fluid as well as some echogenic non-shadowing luminal contents and gas



PATIENT

Hershey Lorencovitz

SPECIES

Canine

BREED

Labradoodle

SEX

Spayed Female

AGE

11 Years

WEIGHT

62.8 Pounds

INTERPRETED BY

Beth Johnson, DVM,
DACVIM (SAIM)

IMAGING PERFORMED BY

Vincent Ravancho,
CVT

HOSPITAL NAME

Whippany VH

REFERRING VET

Dr. Cordero

INVOICE

35950

DATE

5/5/26

consistent with normal chyme. There is no evidence of obstruction, foreign material, or infiltrative disease. Pyloric outflow tract appears patent.

The visible small intestine demonstrates areas of mildly thick muscularis layer relative to mucosa (disruption of the normal 1:3 muscularis:mucosa ratio). Small intestinal submucosa is slightly irregular, thick and hyperechoic, without evident loss of layering appreciated. The lumen of the small intestine is diffusely mildly fluid distended without evidence of a definitive obstructive pattern or plication and/or visible foreign material, but small intestinal hyperperistalsis is noted in several areas.

The visible colon is normal in wall thickness (< 0.2 cm) and layering. Contents are consistent with normal formed feces and gas.

Pancreas

The pancreas that is observed appears appropriately isoechoic to surrounding omental fat. Visible capsule is smooth and normal in contour. Visible pancreatic parenchyma is homogenous and unremarkable. There is no visible pancreatic duct dilation. There is no evidence of active peripancreatic inflammation.

Free Abdomen

There is no visible free peritoneal effusion noted in these images.

There is no apparent pathologic lymphadenopathy noted in these images.

ULTRASONOGRAPHIC FINDINGS

- Mild inflammatory bowel disease pattern- Thick muscularis has been reported with infiltrative bowel disease including both benign inflammatory disease as well as infiltrative neoplasia such as lymphoma. No loss of layering or distinct characteristics of malignancy are present. Therefore, differentials cannot be further ranked without tissue sampling.
- Changes consistent with gastroenteritis- Consistent with irritation secondary to dietary indiscretion or intolerance, infection (bacterial, viral, other), parasitic or protozoal disease, toxin, other metabolic disease such as pancreatitis, other.

INTERPRETATION OF THE FINDINGS & FURTHER RECOMMENDATIONS

- Given patients reported hypoalbuminemia, if not recently evaluated, urinalysis, and if indicated based on urinalysis results, urine culture is recommended. If protein is present in an otherwise quiet sediment, protein quantification with a urine protein to creatinine ration is recommended.
- A baseline cortisol is recommended. If baseline cortisol is less than 2, a full ACTH stimulation test is recommended to rule out hypoadrenocorticism.
- A routine fecal/Giardia exam is recommended.
- A gastrointestinal malabsorption panel (including cobalamin, folate, TLI and PLI) to Texas A&M GI Laboratory is recommended for further evaluation of GI and pancreatic function.
- A fecal enteropathogen PCR panel to Texas A&M GI Laboratory could be considered for



PATIENT

Hershey Lorencovitz

SPECIES

Canine

BREED

Labradoodle

SEX

Spayed Female

AGE

11 Years

WEIGHT

62.8 Pounds

INTERPRETED BY

Beth Johnson, DVM,
DACVIM (SAIM)

IMAGING PERFORMED BY

Vincent Ravancho, CVT

HOSPITAL NAME

Whippany VH

REFERRING VET

Dr. Cordero

INVOICE

35950

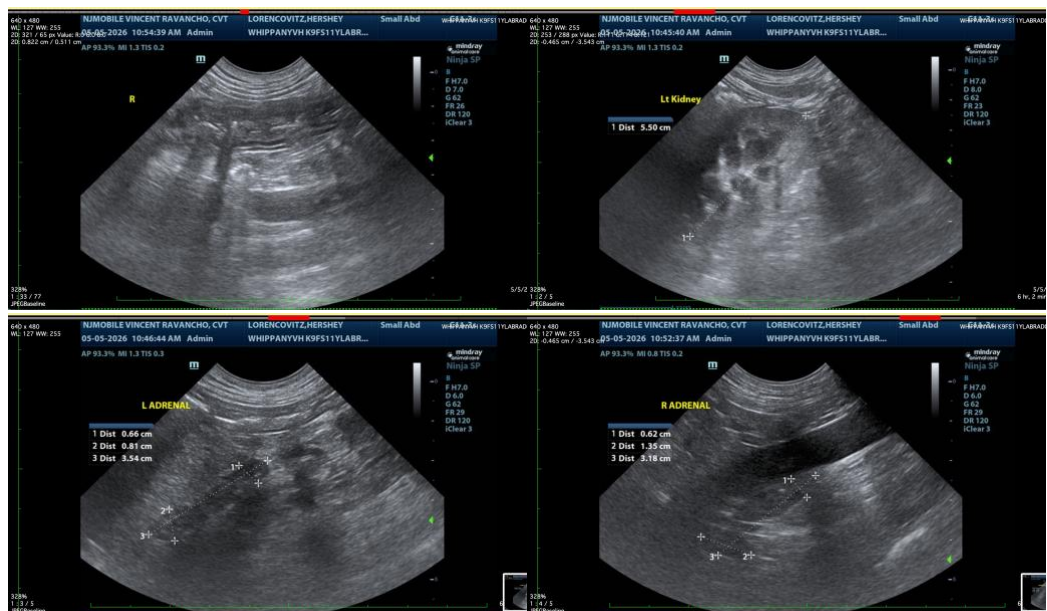
DATE

5/5/26

further evaluation of possible infectious disease. Contact lab for recommendations on how long to discontinue antibiotics (if indicated) prior to obtaining a stool sample for submission.

In the meantime:

- Supportive/symptomatic medical management of clinical signs is recommended, including anti-emetics, gastroprotectants (+/- sucralfate, especially with any history of hematemesis), an appetite stimulant and fluid therapy if indicated, etc.
- Additionally, empirical deworming with a 5-day course of Panacur is recommended.
- A full course of empirical Helicobacter triple therapy could be considered.
- A probiotic, such as visbiome or proviable, may be helpful.
- Finally, if tolerated, a transition in diet could be considered, based on trial-and-error response with some options to consider including a gastrointestinal biome diet vs a hydrolyzed protein diet (sometimes several trials with different brands are necessary) vs an easy to digest, bland or low-fat diet vs other.
- Ultimately, pending results of above workup and treatments, etc., biopsies of the GI tract, being sure to include ileum, if possible, may be necessary for a definitive diagnosis and therefore to further guide medical management of presumed protein losing enteropathy secondary to underlying gastrointestinal disease.





PATIENT

Hershey Lorencovitz

SPECIES

Canine

BREED

Labradoodle

SEX

Spayed Female

AGE

11 Years

WEIGHT

62.8 Pounds

INTERPRETED BY

Beth Johnson, DVM,
 DACVIM (SAIM)

IMAGING PERFORMED BY

Vincent Ravancho,
 CVT

HOSPITAL NAME

Whippany VH

REFERRING VET

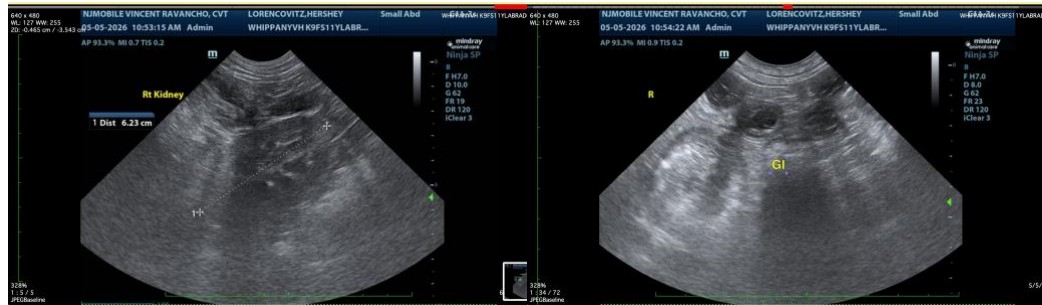
Dr. Cordero

INVOICE

35950

DATE

5/5/26



The information and recommendations provided are based on the images presented by the referring veterinarian/sonographer. No evaluation can be communicated regarding pathology that was not visible in the image/video clips provided.

Thank you for this referral. If the clinical or image interpretation does not parallel your findings or if I can be of any further assistance please contact me.

Beth Johnson, DVM DACVIM

info@sonopath.com