



PATIENT

Grey Beers

SPECIES

Feline

BREED

DSH

SEX

Neutered Male

AGE

13 Years 3 Months

WEIGHT

9.0

INTERPRETED BY

Beth Johnson, DVM
DACVIM

IMAGING PERFORMED BY

Jessica Green

HOSPITAL NAME

Stanglein Veterinary
Clinic

REFERRING VET

Dr. Nathaniel Stanglein

INVOICE

74945

DATE

5/5/26

PRESENTING CLINICAL SIGNS

Hx of weight loss and hyperthyroidism, weight loss has continued despite normal thyroid values. Mild-mod dental disease noted but seems unlikely to be causing significant pain leading to weight loss/reduced appetite. Concern for GI disease/neoplasia vs other

ULTRASONOGRAPHIC EXAMINATION OF THE ABDOMEN

Urinary System

Urinary bladder is adequately distended. It has a normal uniform wall thickness. Contents include primarily anechoic fluid with occasional echogenic non-shadowing debris, most consistent with incidental suspended lipid in a cat, possibly combined with exfoliated cells, mucous and/or small blood clots. Both sterile inflammation as well as urinary tract infection can also present with echogenic debris. No masses or definitive cystoliths are observed. The trigone and visible pelvic urethra are normal in thickness with a smooth mucosal surface.

Kidneys are normal in size but bilaterally irregular and diffusely echogenic with decreased corticomedullary distinction and poor visualization of internal architecture. There is no pyelectasia noted. Left measures 3.98 cm. Right measures 4.2 cm. Non-obstructive linear multifocal hyperechoic diverticular foci with acoustic shadowing are noted.

Adrenal Glands

The right adrenal gland is normal in size (0.34 cm), shape and overall architecture, echogenicity and echotexture. Visible surrounding vasculature appears normal.

The left adrenal gland is normal in size (0.43 cm), shape and overall architecture, echogenicity and echotexture. Visible surrounding vasculature appears normal.

Spleen

The spleen is subjectively normal in size with a normal smooth capsular contour. Parenchyma is appropriately finely textured and homogenous with normal echogenicity relative to surrounding tissue (hyperechoic to liver). No focal nodules or masses are observed. Splenic vasculature appears normal.

Liver

Liver is subjectively enlarged (swollen contour) without disruption of architecture. It has a normal homogenous echotexture. Parenchyma is diffusely hyperechoic characterized by less prominent than normal portal vein walls and increased echogenicity relative to the spleen and falciform fat. No focal lesions are observed. Visible vasculature and biliary tree appear normal without distension or congestion.

The gallbladder is non-distended in size. The wall is smooth without visible thickening. Luminal contents are primarily anechoic. There is no evidence of cystic or common bile duct dilation.

Gastrointestinal

The visible stomach wall is normal in thickness and layering. The lumen of the stomach is empty with no evidence of obstruction, foreign material or infiltrative disease. Pyloric outflow tract appears patent.

The visible small intestine demonstrates areas of moderately thick muscularis layer relative to mucosa (disruption of the normal 1:3 muscularis:mucosa ratio). Small intestinal submucosa is slightly irregular,



PATIENT

Grey Beers

SPECIES

Feline

BREED

DSH

SEX

Neutered Male

AGE

13 Years 3 Months

WEIGHT

9.0

INTERPRETED BY

Beth Johnson, DVM
DACVIM

IMAGING PERFORMED BY

Jessica Green

HOSPITAL NAME

Stanglein Veterinary
Clinic

REFERRING VET

Dr. Nathaniel Stanglein

INVOICE

74945

DATE

5/5/26

thick and hyperechoic, without evident loss of layering appreciated. The lumen of the small intestine is empty with no evidence of obstruction or foreign material.

The visible colon is normal in wall thickness (< 0.2 cm) and layering. Contents are consistent with normal formed feces and gas.

Pancreas

The pancreas that is observed appears appropriately isoechoic to surrounding omental fat. Visible capsule is smooth and normal in contour. Visible pancreatic parenchyma is homogenous and unremarkable. There is no visible pancreatic duct dilation. There is no evidence of active peripancreatic inflammation.

Free Abdomen

There is no visible free peritoneal effusion noted in these images.

There is no apparent pathologic lymphadenopathy noted in these images.

ULTRASONOGRAPHIC FINDINGS

- Moderate inflammatory bowel disease (IBD) pattern – Thick muscularis has been reported with infiltrative bowel disease including both benign inflammatory disease as well as infiltrative neoplasia such as lymphoma. No loss of layering or distinct characteristics of malignancy are present. Therefore, differentials cannot be further ranked without tissue sampling.
- Hyperechoic hepatomegaly – This appearance is most consistent with benign hepatic lipidosis or endocrine/DM hepatopathy. Infiltrative disease such as amyloidosis or round cell neoplasia, such as mast cell tumor or less likely, lymphoma, is also possible.
- Mild to moderate bilateral chronic kidney disease changes with non-obstructive dystrophic mineralization noted bilaterally.
- Moderate amount of echogenic urinary bladder debris.

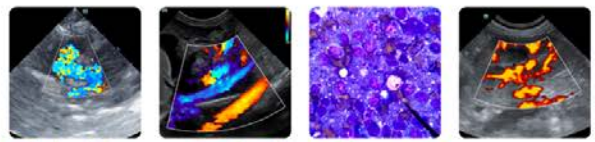
INTERPRETATION OF THE FINDINGS & FURTHER RECOMMENDATIONS

Further recommendations for patient's weight loss depend in large part on appetite.

If not already evaluated, a thorough evaluation of daily caloric intake is recommended to assure an adequate daily caloric intake is occurring vs an inadvertent reduction in calories due to change in diet and/or feeding schedule, competitive eating environment, etc.

Given the bowel changes noted above, especially if patient's daily caloric intake is normal or even increased:

- A gastrointestinal malabsorption panel (including cobalamin, folate, TLI and PLI) to Texas A&M GI Laboratory is recommended for further evaluation of GI and pancreatic function.
- Ideally, biopsies of the GI tract, being sure to include ileum if possible, are recommended to definitively diagnose and therefore manage the infiltrative bowel disease.



PATIENT

Grey Beers

SPECIES

Feline

BREED

DSH

SEX

Neutered Male

AGE

13 Years 3 Months

WEIGHT

9.0

INTERPRETED BY

Beth Johnson, DVM
DACVIM

IMAGING PERFORMED BY

Jessica Green

HOSPITAL NAME

Stanglein Veterinary
Clinic

REFERRING VET

Dr. Nathaniel Stanglein

INVOICE

74945

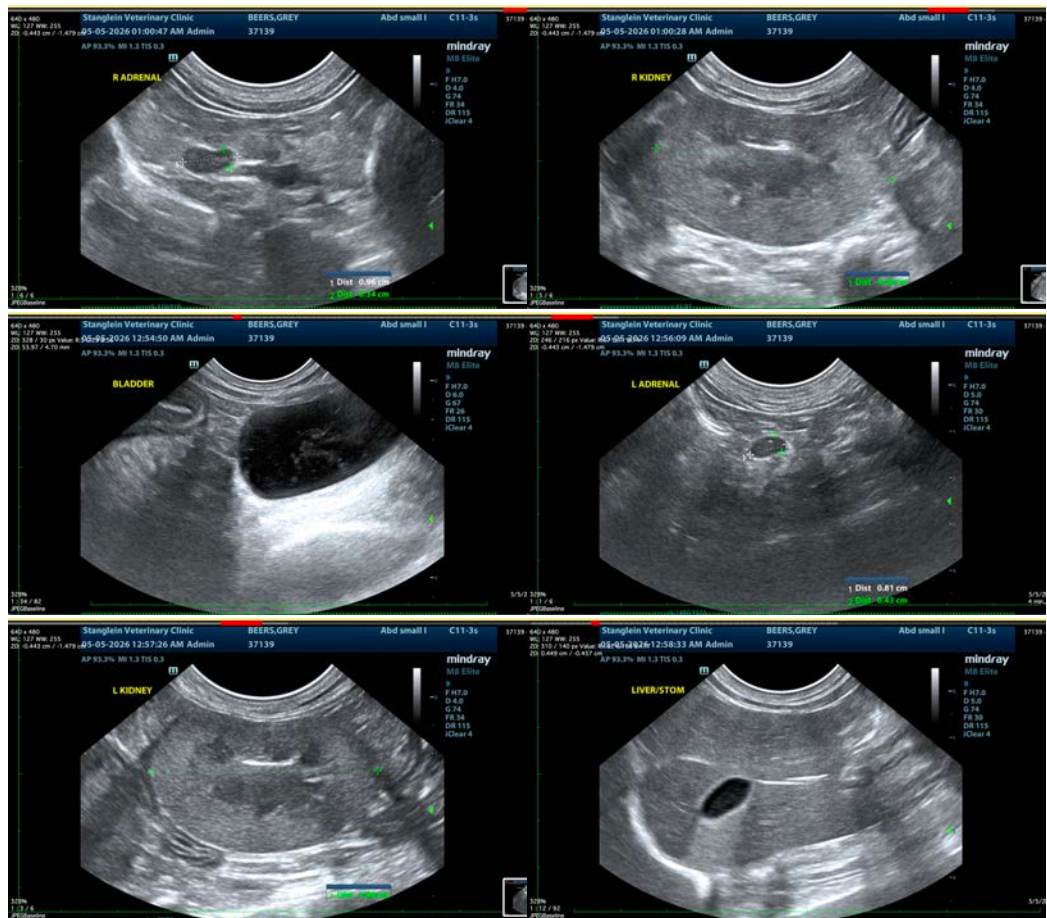
DATE

5/5/26

- If biopsies cannot be obtained, empirical therapies could include a probiotic (if diarrhea is present, such as visbiome or proviable), empirical deworming with a 5-day course of Panacur and, if tolerated, a transition in diet, based on trial-and-error response, beginning with a hydrolyzed protein diet. Some patients respond to one brand/version of a hydrolyzed protein diet better than another brand, so several trials may be required.

- Additional considerations could include cobalamin supplementation (unless cobalamin level is evaluated and supplementation is not warranted) and prednisolone (if not contraindicated based on patient contraindications, co-morbidities, etc.).

Having said that, especially in the face of decreased appetite, infiltrative disease affecting the liver and/or emerging chronic kidney disease versus other could be contributing to decreased appetite and weight loss. Therefore, further metabolic evaluation may be warranted.





PATIENT

Grey Beers

SPECIES

Feline

BREED

DSH

SEX

Neutered Male

AGE

13 Years 3 Months

WEIGHT

9.0

INTERPRETED BY

Beth Johnson, DVM
DACVIM

IMAGING PERFORMED BY

Jessica Green

HOSPITAL NAME

Stanglein Veterinary
Clinic

REFERRING VET

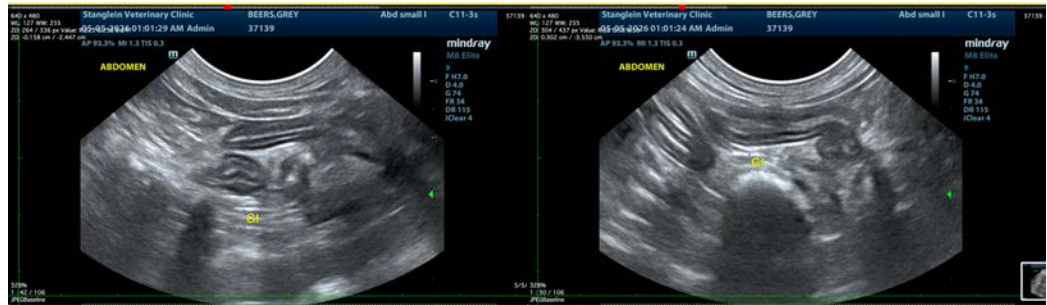
Dr. Nathaniel Stanglein

INVOICE

74945

DATE

5/5/26



The information and recommendations provided are based on the images presented by the referring veterinarian/sonographer. No evaluation can be communicated regarding pathology that was not visible in the image/video clips provided.

Thank you for this referral. If the clinical or image interpretation does not parallel your findings or if I can be of any further assistance please contact me.

Beth Johnson, DVM, DACVIM
info@sonopath.com