



PATIENT

Cinder Unkert

SPECIES

Feline

BREED

Norwegian Forest Cat

SEX

Neutered Male

AGE

10 Years 10 Months

WEIGHT

10.5 lbs

INTERPRETED BY

Beth Johnson, DVM
DACVIM

IMAGING PERFORMED BY

Vincent Ravancho CVT

HOSPITAL NAME

Legacy Animal Hospital

REFERRING VET

Dr. Potenzzone

INVOICE

15813

DATE

05/05/26

PRESENTING CLINICAL SIGNS

Hx of PU SX. R/O GI Lymphoma vs mechanical. Clinical findings - Weight Loss - Gas distended bowels

Abnormal PE/Chem/CBC/UA Results: March - CBC/Chem/T4 Fr T4/ Fecal/ all normal. U/A - 2+ protein, 3+ crystals. USG 1.053

ULTRASONOGRAPHIC EXAMINATION OF THE ABDOMEN

Urinary System

Urinary bladder is adequately distended with anechoic contents. No masses, inflammatory changes, echogenic sediment or cystoliths are observed. The urinary bladder, trigone and visible pelvic urethra are normal in thickness with a smooth mucosal surface.

Left kidney is normal in size (3.85 cm), shape and echogenicity. It has smooth peripheral margination. There is a normal 1:3 cortex to medulla ratio with appropriate corticomedullary distinction. There is no evidence of pyelectasia, mineral or infarcts observed.

Right kidney is normal in size (3.64 cm), shape and echogenicity. It has smooth peripheral margination. There is a normal 1:3 cortex to medulla ratio with appropriate corticomedullary distinction. There is no evidence of pyelectasia, mineral or infarcts observed.

Adrenal Glands

Left adrenal gland is normal in size (0.37 cm), shape and overall architecture, echogenicity and echotexture. Visible surrounding vasculature appears normal.

Right adrenal gland is normal in size (0.38 cm), shape and overall architecture, echogenicity and echotexture. Visible surrounding vasculature appears normal.

Spleen

Spleen is subjectively normal in size with a normal smooth capsular contour. Parenchyma is appropriately finely textured and homogenous with normal echogenicity relative to surrounding tissue (hyperechoic to liver). No focal nodules or masses are observed. Splenic vasculature appears normal.

Liver

Liver is subjectively normal in size with normal smooth curvilinear peripheral contour. Parenchyma is appropriately hypoechoic to the spleen in echogenicity and appropriately mildly coarse and homogenous in echotexture. No focal lesions are observed. Visible vasculature and biliary tree appear normal without distension or congestion.

Gallbladder is non-distended in size. The wall is smooth without visible thickening. Luminal contents are primarily anechoic. There is no evidence of cystic or common bile duct dilation.

Gastrointestinal

The visible stomach wall is normal in thickness and layering. The stomach is mildly distended and contains an echogenic interface with distal progressively shadowing material consistent with hairball density (or similar fluid absorbing material) noted. Normal ingesta and gas cannot be definitively ruled out and should be considered especially without adequate fasting prior to the ultrasound.



PATIENT	The visible small intestines are normal in wall thickness and layering. Small intestinal motility appears adequate (1-3 contractions per min). The lumen of the small intestine is empty with no evidence of obstruction, foreign material or infiltrative disease.
Cinder Unkert	
SPECIES	The visible colon is normal in wall thickness (< 0.2 cm) and layering. Contents are consistent with normal formed feces and gas.
Feline	
BREED	<i>Pancreas</i>
Norwegian Forest Cat	The pancreas that is observed appears appropriately isoechoic to surrounding omental fat. Visible capsule is smooth and normal in contour. Visible pancreatic parenchyma is homogenous and unremarkable. There is no visible pancreatic duct dilation. There is no evidence of active peripancreatic inflammation.
SEX	<i>Free Abdomen</i>
Neutered Male	There is no visible free peritoneal effusion noted in these images.
AGE	There is no apparent pathologic lymphadenopathy noted in these images.
10 Years 10 Months	
WEIGHT	ULTRASONOGRAPHIC FINDINGS
10.5 lbs	<ul style="list-style-type: none">The gastric content should be interpreted in combination with when patient last ate, as well as full clinical picture, etc. as normal ingesta and gas can't be ruled out. Having said that, given the shadowing foreign materials such as a hairball could potentially be present and contributing to a decreased appetite and therefore weight loss.Otherwise, this is a largely unremarkable/normal, structural abdomen without a definitive, ultrasonographically intra-abdominal explanation for patients' reported clinical signs.
INTERPRETED BY	<u>INTERPRETATION OF THE FINDINGS & FURTHER RECOMMENDATIONS</u>
Beth Johnson, DVM DACVIM	Further recommendations than those above, for patients' reported weight loss, are largely dependent on appetite/daily caloric intake.
IMAGING PERFORMED BY	If not already evaluated, a thorough evaluation of daily caloric intake is recommended to assure an adequate daily caloric intake is occurring vs an inadvertent reduction in calories due to change in diet and/or feeding schedule, competitive eating environment, etc.
Vincent Ravancho CVT	In the face of normal or even increased daily caloric intake, further evaluation of digestion and absorption is recommended beginning with a gastrointestinal malabsorption panel (including cobalamin, folate, TLI and PLI) to Texas A&M GI Laboratory is recommended for further evaluation of GI and pancreatic function.
HOSPITAL NAME	Other considerations, pending results of the gastric content evaluation and calorie assessment, include further evaluation for possible pain (dental, orthopedic, other), upper respiratory disease or oropharyngeal disease, cardiac disease and/or neurologic disease vs other as possible causes for decreased appetite and/or unintentional weight loss is also recommended.
Legacy Animal Hospital	
REFERRING VET	
Dr. Potenzone	
INVOICE	
15813	
DATE	
05/05/26	



PATIENT

Cinder Unkert

SPECIES

Feline

BREED

Norwegian Forest Cat

SEX

Neutered Male

AGE

10 Years 10 Months

WEIGHT

10.5 lbs

INTERPRETED BY

Beth Johnson, DVM
 DACVIM

IMAGING PERFORMED BY

Vincent Ravancho CVT

HOSPITAL NAME

Legacy Animal Hospital

REFERRING VET

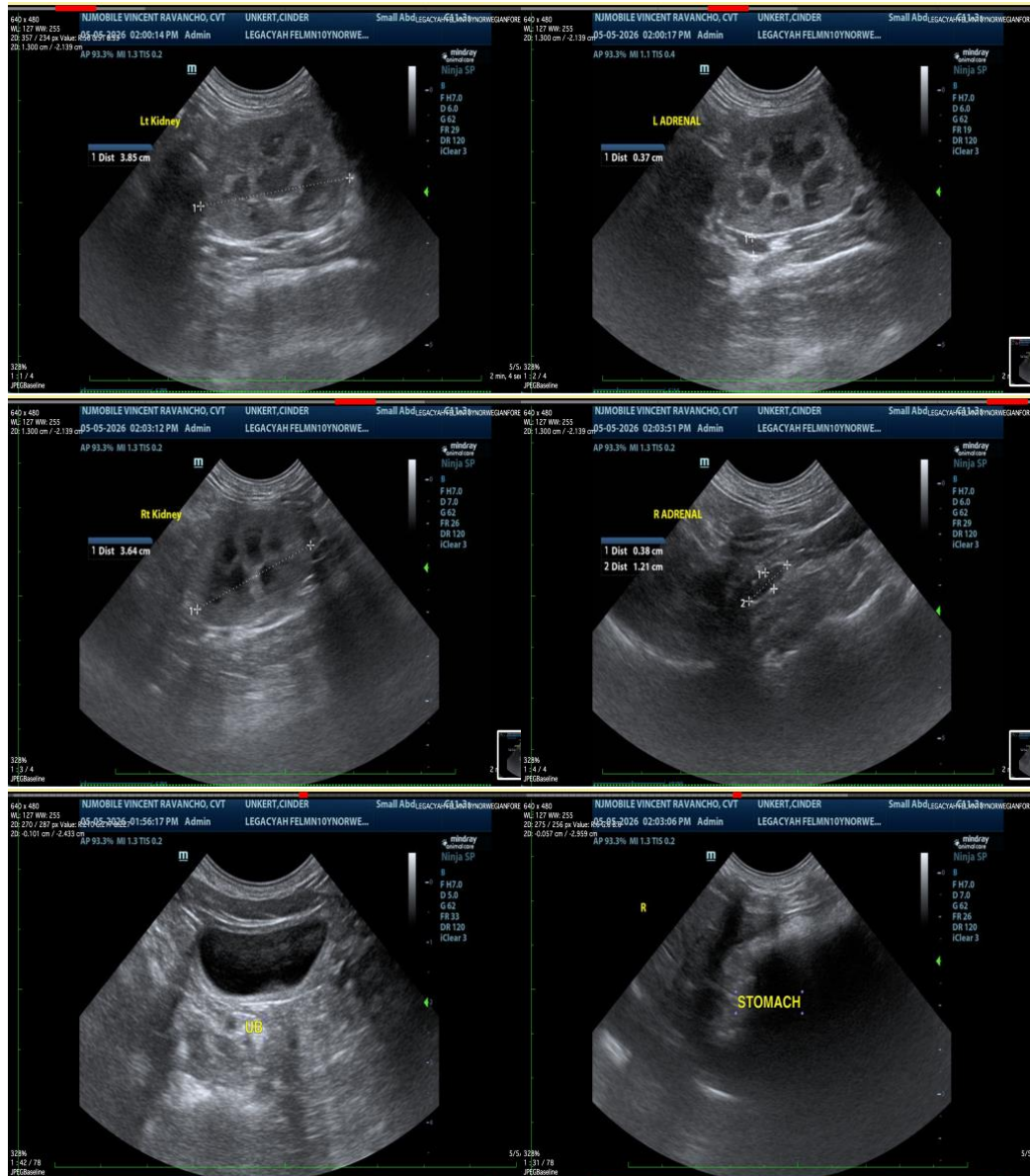
Dr. Potenzone

INVOICE

15813

DATE

05/05/26



The information and recommendations provided are based on the images presented by the referring veterinarian/sonographer. No evaluation can be communicated regarding pathology that was not visible in the image/video clips provided.

Thank you for this referral. If the clinical or image interpretation does not parallel your findings or if I can be of any further assistance, please contact me.

Beth Johnson, DVM DACVIM

info@sonopath.com