



**PATIENT**

Charlie Ditty

**SPECIES**

Canine

**BREED**

Cocker Spaniel

**SEX**

MN

**AGE**

10 years

**WEIGHT**

15.9 kg

**INTERPRETED BY**

Beth Johnson, DVM  
DACVIM

**IMAGING  
PERFORMED BY**

Loetitia Saint-Jacques,  
LVT

**HOSPITAL NAME**

Desert Hills Animal  
Hospital

**REFERRING VET**

Dr. Amanda Coats

**INVOICE**

11872

**DATE**

5/5/2026

**PRESENTING CLINICAL SIGNS**

Presented 4/30/26 for a distended abdomen & marked ascites noted. Albumin low, 500 ml fluid obtained via abdominocentesis. Started on prednisone 4/30, will be starting Royal Canine low fat+ hydrolyzed diet 5/4/26. Doing a little better over the weekend. Working diagnosis. R/O Hepatic dz vs Lymphangectasia vs other PLE vs other.

MEDS: Prednisone 20 mg- Give 1/2 tab PO in AM, 1 whole tab in PM; starting Roya Canin low fat + Hydrolyzed diet

Abnormal PE/Chem/CBC/UA Results: 4/30/26: CBC- Lymphocytes=0.79 (1.0-4.8); Chem 11-Albumin=1.9 (2.5-4.4), Alk Phos=179 (20-150), ALT=173 (10-118), Total Protein=4.3 (5.4-8.2) 5/1/26: Urinalysis- Urinalysis SG 1.015; No Protein 5/4/26: Fluid Part Only Source: ABDOMINAL Color LIGHT YELLOW Clarity CLEAR Specific Gravity 1.007 Protein <2.0 g/dL WBC 360 0-3,000 per ul RBC 0 per uL CYTOLOGY OF ABDOMINAL FLUID: Interpretation: Non-inflammatory fluid; Consistent with a transudate RAD CONCLUSIONS: 1. Large volume peritoneal effusion; an underlying cause is not noted on this study. An abdominal mass is not identified but could be obscured by the effusion. 2. The gastric content most likely reflects normal food, especially in the absence of vomiting. Foreign material is not likely.

**ULTRASONOGRAPHIC EXAMINATION OF THE ABDOMEN**

**Urinary System**

The urinary bladder is adequately distended with anechoic contents. No masses, inflammatory changes, echogenic sediment or cystoliths are observed. The urinary bladder, trigone and visible pelvic urethra are normal in thickness with a smooth mucosal surface.

Prostate is normal in size, echotexture, and echogenicity for a neutered male.

The right kidney is normal is size (6.0 cm), shape and echogenicity. It has smooth peripheral margination. There is a normal 1:3 cortex to medulla ratio with appropriate corticomedullary distinction. There is no evidence of pyelectasia, mineral or infarcts observed.

The left kidney is normal is size (5.5 cm), shape and echogenicity. It has smooth peripheral margination. There is a normal 1:3 cortex to medulla ratio with appropriate corticomedullary distinction. There is no evidence of pyelectasia, mineral or infarcts observed.

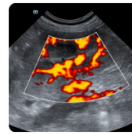
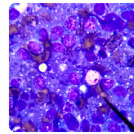
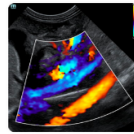
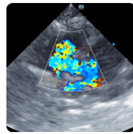
**Adrenal Glands**

The right adrenal gland is normal in size (0.65 cm at caudal pole, the cranial pole is difficult to fully visualize/isolate for measurement), shape and overall architecture, echogenicity and echotexture. Visible surrounding vasculature appears normal.

The left adrenal gland is normal in size (0.72 cm at cranial pole and 0.78 cm at caudal pole), shape and overall architecture, echogenicity and echotexture. Visible surrounding vasculature appears normal.

**Spleen**

Spleen is subjectively normal in size with a normal smooth capsular contour. Parenchyma is appropriately finely textured and homogenous with normal echogenicity relative to surrounding tissue (hyperechoic to liver). Multifocal well-demarcated hyperechoic homogenous nodules are noted. Splenic vasculature appears normal.



## PATIENT

Charlie Ditty

## SPECIES

Canine

## BREED

Cocker Spaniel

## SEX

MN

## AGE

10 years

## WEIGHT

15.9 kg

## INTERPRETED BY

Beth Johnson, DVM  
DACVIM

## IMAGING PERFORMED BY

Loetitia Saint-Jacques,  
LVT

## HOSPITAL NAME

Desert Hills Animal  
Hospital

## REFERRING VET

Dr. Amanda Coats

## INVOICE

11872

## DATE

5/5/2026

## Liver

The right liver is markedly heterogenous, characterized by multifocal hypoechoic nodules with an otherwise coarse, slightly more echogenic/hyperechoic parenchyma, and a smoother edge and more normal size. The left liver, however, is subjectively small in size with markedly undulating or scalloped capsular contour. Patchy, ill-defined areas of increased echogenicity are present with reduced visualization of vessels. No overt nodules or masses are observed. Visible vasculature and biliary tree appear normal without distension or congestion.

Gallbladder is moderately distended with anechoic bile as well as suspended and gravity dependent echogenic debris. The wall is smooth without visible thickening. There is no evidence of cystic or CBD dilation. There is no evidence of effusion or inflammation.

## Gastrointestinal

The visible stomach wall is normal in thickness and layering. The stomach is moderately distended with echogenic non-shadowing luminal contents and gas consistent with normal ingesta. There is no evidence of obstruction, foreign material or infiltrative disease. If patient was appropriately fasted, delayed gastric emptying could be considered. Non-shadowing foreign material is considered less likely but cannot be definitively ruled out.

If clinical signs are consistent (vomiting, etc.), recommendations include supportive medical care, 24 hours fasting and re-image.

The visible small intestines are normal in wall thickness and layering. Small intestinal motility appears adequate (1-3 contractions per min). The lumen of the small intestine is empty with no evidence of obstruction, foreign material or infiltrative disease.

The visible colon is normal in wall thickness (< 0.2 cm) and layering. Contents are consistent with normal formed feces and gas.

## Pancreas

The observed pancreas appears appropriately isoechoic to surrounding omental fat. The capsule is mildly irregular in shape. Parenchyma is mildly heterogenous and coarse. There is no visible pancreatic duct dilation. There is no evidence of active peripancreatic inflammation.

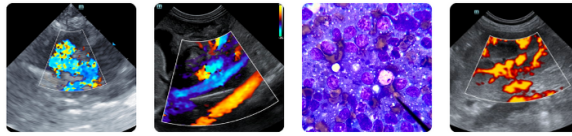
## Free Abdomen

There is a moderate amount of free fluid noted in these images as well as subtly enhanced hyperechoic mesenteric fat.

There is no apparent pathologic lymphadenopathy noted in these images.

## PRIMARY FINDINGS

- The appearance of the liver, especially the left side, is concerning for a hepatic fibrosis pattern consistent with chronic hepatitis and/or early cirrhosis. The right side appears less end stage but is concerning for an infiltrative process. Potentially benign chronic inflammatory with some nodular hyperplasia and infiltrative neoplasia, less likely, but unable to be definitively ruled out affecting the right side.



**PATIENT**

Charlie Ditty

**SPECIES**

Canine

**BREED**

Cocker Spaniel

**SEX**

MN

**AGE**

10 years

**WEIGHT**

15.9 kg

**INTERPRETED BY**

Beth Johnson, DVM  
DACVIM

**IMAGING  
PERFORMED BY**

Loetitia Saint-Jacques,  
LVT

**HOSPITAL NAME**

Desert Hills Animal  
Hospital

**REFERRING VET**

Dr. Amanda Coats

**INVOICE**

11872

**DATE**

5/5/2026

- Moderate gallbladder debris - Cholecystic debris is of unknown clinical significance. It can be seen with biliary stasis from fasting or illness. Cholecystic debris is not necessarily related to hepatobiliary disease. Echogenic bile is most commonly an incidental finding in dogs and should be interpreted in combination with clinical signs such as nausea, inappetence, cranial abdominal discomfort and/or laboratory changes such as increased ALP and/or increased Tbili.

- Pancreatic age-related remodeling/Chronic pancreatitis - Mild irregularities are consistent with benign age-related change. Low-grade smoldering chronic pancreatitis cannot be ruled out and should be suspected in the face of appropriate clinical signs.

- A moderate amount of free fluid is of unknown origin. Differentials (unless already ruled out) could include increased hydrostatic pressure (cardiac disease and/or vascular or lymph blockage), decreased oncotic pressure (low albumin), vasculitis, paraneoplastic fluid, rupture/leakage of/from an organ (GI, GB, UB, other), blood (hemoabdomen), other.

**SECONDARY FINDINGS**

- Hyperechoic splenic nodules - most consistent with benign myelolipomas. Other differentials such as fibrosis or calcification caused by old hematomas or infarcts, chronic inflammation, granulomatous disease or metastatic disease cannot be ruled out, but are considered less likely.

**INTERPRETATION OF THE FINDINGS & FURTHER RECOMMENDATIONS**

Given the appearance of the liver, combined with the fluid transudate, concerns are free fluid from the low albumin, combined potentially with some portal hypertension and overall decreased liver function contributing to the changes. Therefore, if patient's total bilirubin is not increased, bile acids are recommended.

Additionally, in the meantime, further gastrointestinal workup could also be considered beginning with a gastrointestinal malabsorption panel (including cobalamin, folate, TLI and PLI) to Texas A&M GI Laboratory is recommended for further evaluation of GI and pancreatic function.

A routine fecal/giardia exam is recommended if not recently evaluated.

A fecal enteropathogen PCR panel to Texas A&M GI Laboratory could be considered for further evaluation of possible infectious disease. Contact lab for recommendations on how long to discontinue antibiotics (if indicated) prior to obtaining a stool sample for submission.

Sampling of the liver could be considered beginning with a fine needle aspirate, especially of the right side, if patient's coagulation status is appropriate but ultimately, a liver biopsy being sure to include copper level assessment may be necessary for a definitive diagnosis.

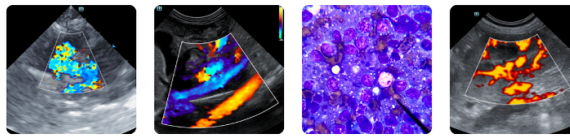
Pending results of above, full internal medicine consultation and/or referral to a veterinary internist may be helpful.

For an additional charge an internal medicine consult can be utilized through [Sonopath.com](http://sonopath.com). You can select the internalmedicine drop down at <http://spa.sonopath.com/>.

Imaging performed by



Desert Hills Animal Hospital, Inc.  
pawsonography@gmail.com  
530-786-8340



Clinical Sonography & Telecytology  
Educational Teleconsultation Services™

# SonoPath

FOSTERING THE ART OF VETERINARY MEDICINE™

SonoPath.com info@sonopath.com 1.800.838.4268

### PATIENT

Charlie Ditty

### SPECIES

Canine

### BREED

Cocker Spaniel

### SEX

MN

### AGE

10 years

### WEIGHT

15.9 kg

### INTERPRETED BY

Beth Johnson, DVM  
DACVIM

### IMAGING PERFORMED BY

Loetitia Saint-Jacques,  
LVT

### HOSPITAL NAME

Desert Hills Animal  
Hospital

### REFERRING VET

Dr. Amanda Coats

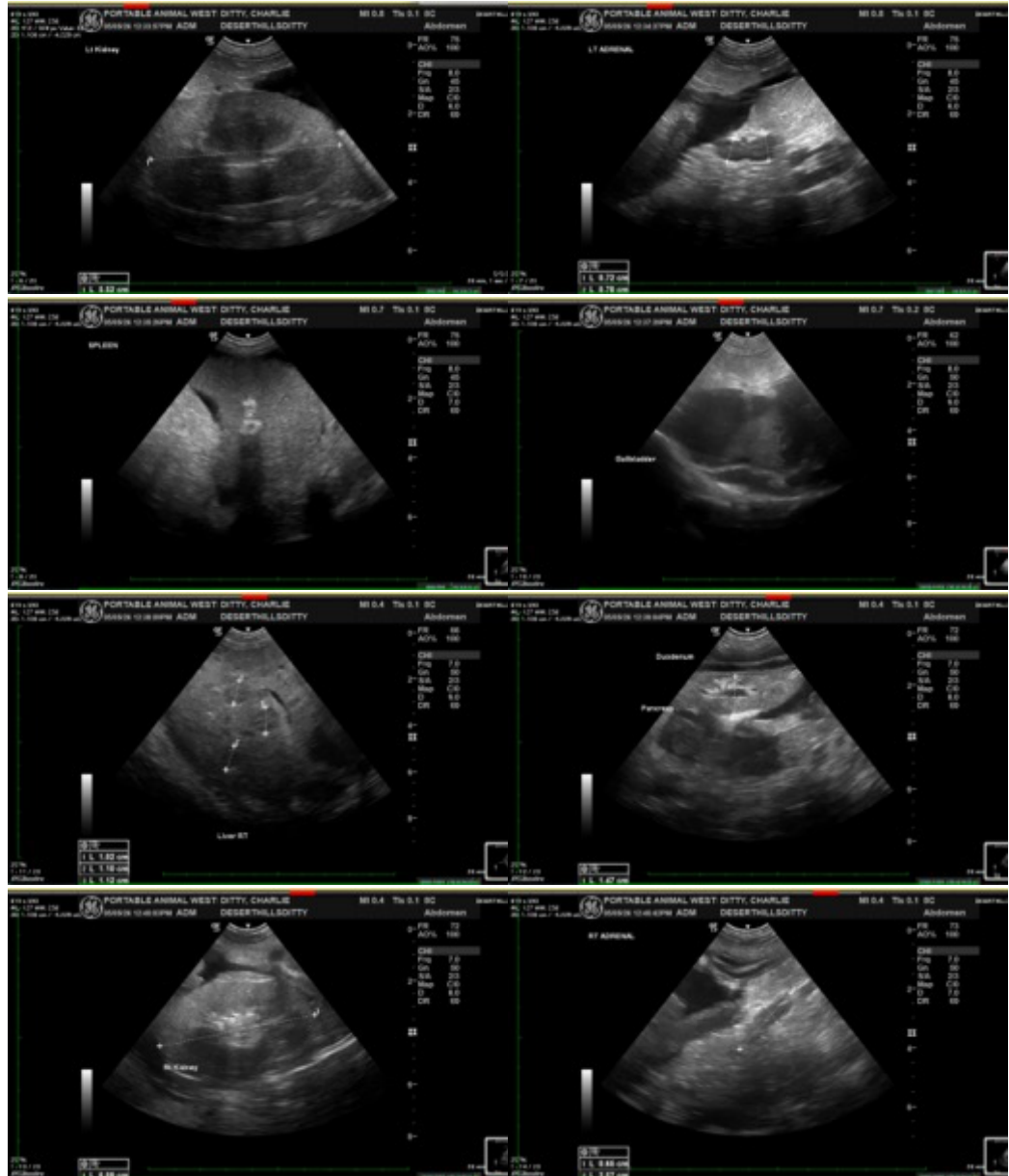
### INVOICE

11872

### DATE

5/5/2026

One of the world's top internists & SonoPath associate Dr. Remo Lobetti BVSc, MMedVet, PhD, DECVIM can evaluate your case through SonoPath. <https://sonopath.com/resources/sonopath-services/internal-medicine-teleconsultation-services>



Imaging performed by



Desert Hills Animal Hospital, Inc.  
pawsonography@gmail.com  
530-786-8340



Clinical Sonography & Telectyology  
Educational Teleconsultation Services™

SonoPath

FOSTERING THE ART OF VETERINARY MEDICINE™

SonoPath.com info@sonopath.com 1.800.838.4268

**PATIENT**

Charlie Ditty

**SPECIES**

Canine

**BREED**

Cocker Spaniel

**SEX**

MN

**AGE**

10 years

**WEIGHT**

15.9 kg

**INTERPRETED BY**

Beth Johnson, DVM  
DACVIM

**IMAGING PERFORMED BY**

Loetitia Saint-Jacques,  
LVT

**HOSPITAL NAME**

Desert Hills Animal  
Hospital

**REFERRING VET**

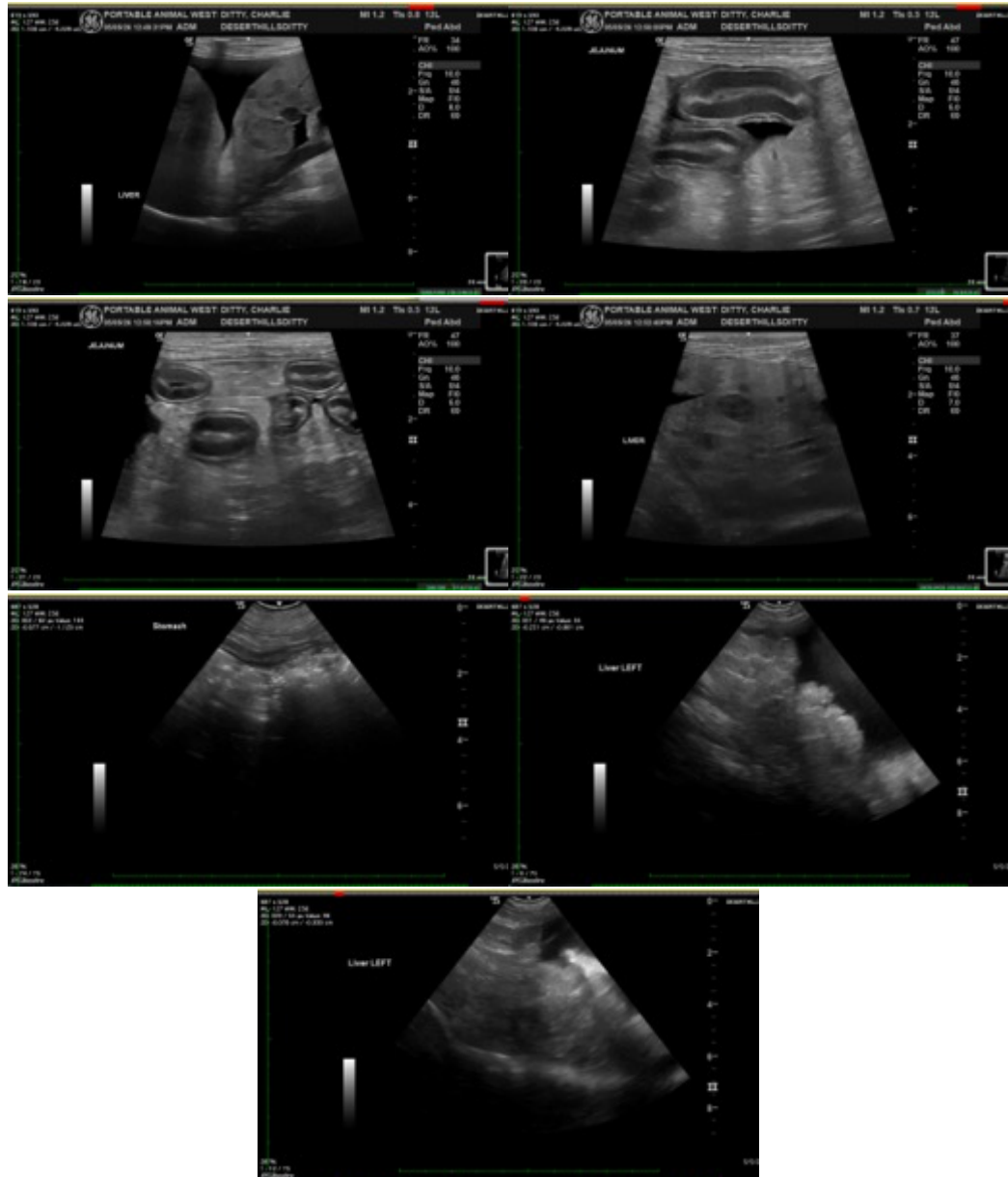
Dr. Amanda Coats

**INVOICE**

11872

**DATE**

5/5/2026



The information and recommendations provided are based on the images presented by the referring veterinarian/sonographer. No evaluation can be communicated regarding pathology that was not visible in the image/video clips provided.

Thank you for this referral. If the clinical or image interpretation does not parallel your findings or if I can be of any further assistance please contact me.

Beth Johnson, DVM, DACVIM  
info@sonopath.com