



## PATIENT

Sigyn Gutshall-  
Seidman

## SPECIES

Canine

## BREED

Bernese x

## SEX

Spayed Female

## AGE

5

## WEIGHT

73

## INTERPRETED BY

Beth Johnson, DVM  
DACVIM

## IMAGING PERFORMED BY

Jenn

## HOSPITAL NAME

Rockaway Animal  
Hospital

## REFERRING VET

Dr. Maniar

## INVOICE

75494

## DATE

5/28/26

## PRESENTING CLINICAL SIGNS

Recheck prev u/s 4/22 Owner reports still having soft stool  
Abnormal PE/Chem/CBC/UA Results: Resting Cortisol >0.50 ALT 167 ALP 380

## ULTRASONOGRAPHIC EXAMINATION OF THE ABDOMEN

### Urinary System

The urinary bladder is adequately distended with anechoic contents. No masses, inflammatory changes, echogenic sediment or cystoliths are observed. The urinary bladder, trigone and visible pelvic urethra are normal in thickness with a smooth mucosal surface.

The right kidney is normal is size (5.93 cm), shape and echogenicity. It has smooth peripheral margination. There is a normal 1:3 cortex to medulla ratio with appropriate corticomedullary distinction. There is no evidence of pyelectasia, mineral or infarcts observed.

The left kidney is normal is size (6.05 cm), shape and echogenicity. It has smooth peripheral margination. There is a normal 1:3 cortex to medulla ratio with appropriate corticomedullary distinction. There is no evidence of pyelectasia, mineral or infarcts observed.

### Adrenal Glands

The right adrenal gland is unable to be well visualized in these images.

The left adrenal gland is small (flattened contour), measuring 0.55 cm at the cranial pole and 0.39 cm at the caudal pole. Corticomedullary structure is unremarkable. Visible surrounding vasculature appears normal.

### Spleen

The spleen is subjectively normal in size with a normal smooth capsular contour. Parenchyma is appropriately finely textured and homogenous with normal echogenicity relative to surrounding tissue (hyperechoic to liver). No focal nodules or masses are observed. Splenic vasculature appears normal.

### Liver

The liver is subjectively normal in size with normal smooth curvilinear peripheral contour. Parenchyma is appropriately hypoechoic to the spleen in echogenicity and appropriately mildly coarse and homogenous in echotexture. No focal lesions are observed. Visible vasculature and biliary tree appear normal without distension or congestion.

The gallbladder is non-distended in size. The wall is smooth without visible thickening. Luminal contents are primarily anechoic. There is no evidence of cystic or common bile duct dilation.

### Gastrointestinal

The visible stomach wall is normal in thickness and layering. The lumen of the stomach is empty with no evidence of obstruction, foreign material or infiltrative disease. Pyloric outflow tract appears patent.

The visible small intestines are normal in wall thickness and layering. Small intestinal motility appears adequate (1-3 contractions per min). The lumen of the small intestine is empty with no evidence of obstruction, foreign material or infiltrative disease.



**PATIENT**

Sigyn Gutshall-Seidman

**SPECIES**

Canine

**BREED**

Bernese x

**SEX**

Spayed Female

**AGE**

5

**WEIGHT**

73

**INTERPRETED BY**

Beth Johnson, DVM  
DACVIM

**IMAGING PERFORMED BY**

Jenn

**HOSPITAL NAME**

Rockaway Animal Hospital

**REFERRING VET**

Dr. Maniar

**INVOICE**

75494

**DATE**

5/28/26

The visible colon is normal in wall thickness (< 0.2 cm) and layering. Contents are consistent with normal formed feces and gas.

**Pancreas**

The pancreas that is observed appears appropriately isoechoic to surrounding omental fat. Visible capsule is smooth and normal in contour. Visible pancreatic parenchyma is homogenous and unremarkable. There is no visible pancreatic duct dilation. There is no evidence of active peripancreatic inflammation.

**Free Abdomen**

There is no visible free peritoneal effusion noted in these images.

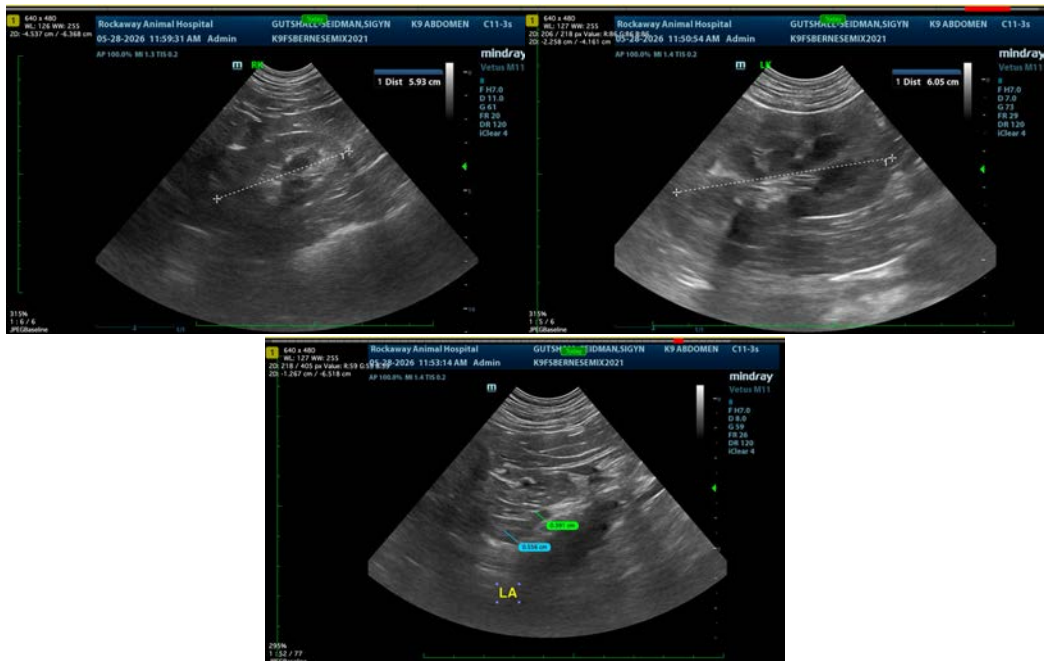
There is no apparent pathologic lymphadenopathy noted in these images.

**ULTRASONOGRAPHIC FINDINGS**

- Subjectively mildly flat left adrenal gland – This can be a normal patient variant and/or a sign of exogenous cortisol administration. If exogenous steroids are not being administered, hypoadrenocorticism (either relative or absolute) should be considered.

**INTERPRETATION OF THE FINDINGS & FURTHER RECOMMENDATIONS**

As is reportedly already pending, an ACTH stimulation test could be considered. Otherwise, recommendations are largely unchanged from the previous study.





## PATIENT

Sigyn Gutshall-  
Seidman

## SPECIES

Canine

## BREED

Bernese x

## SEX

Spayed Female

## AGE

5

## WEIGHT

73

## INTERPRETED BY

Beth Johnson, DVM  
DACVIM

## IMAGING PERFORMED BY

Jenn

## HOSPITAL NAME

Rockaway Animal  
Hospital

## REFERRING VET

Dr. Maniar

## INVOICE

75494

## DATE

5/28/26

The information and recommendations provided are based on the images presented by the referring veterinarian/sonographer. No evaluation can be communicated regarding pathology that was not visible in the image/video clips provided.

Thank you for this referral. If the clinical or image interpretation does not parallel your findings or if I can be of any further assistance please contact me.

**Beth Johnson, DVM, DACVIM**  
info@sonopath.com