



PATIENT

Lucy Laszlo

SPECIES

Canine

BREED

Coonhound x

SEX

Spayed Female

AGE

9 Years

WEIGHT

33.3 kg

INTERPRETED BY

Beth Johnson, DVM
DACVIM

IMAGING PERFORMED BY

Lindsay Powell, CVT

HOSPITAL NAME

Hershey Animal
Emergency Center

REFERRING VET

Dr. Brittany Lang

INVOICE

75439

DATE

5/27/26

PRESENTING CLINICAL SIGNS

P presented 5/26 for vomiting, lethargy, restlessness; last vomit prior to presentation contained blood. O reports that P had diarrhea over the weekend but started to improve with a bland diet alone at home. Os also noted development of petechiation prior to presentation. P is on phenobarbital BID for historical seizure management. PE: Oral Cavity: petechiation present on MM. Abdominal: Doughy, compliant with full cranial abdomen and mild to moderate discomfort on deep cranial palpation. Integument: Marked ecchymosis present on lateroventral thorax in axillary regions bilaterally. Mild petechiation noted in inguinal area bilaterally

Abnormal PE/Chem/CBC/UA Results: 4Dx: Negative x 4 Chem: BG 69 (L) Pancreatic Lipase: 858 (H) CBC: WBC 27.72 (H), Neut 25.10 (H), Lymph 0.87 (L), Mono 1.42 (H), Plt 4 (L), Plt Est. <50k/uL, MPV 13.5 (H), PCT 0.01 (L) EPOC: Lactate 4.66 (H) POCUS: No obvious peritoneal, pleural, or pericardial effusion noted. NIBP: 194/120 (137), 170/107 (121) ECG: Tachycardia but no arrhythmias noted PCV/TS: 50%/8.4 Plt Est IH: 18,000-24,000 Imagyst blood smear + path review: WBC 27.7 (H), Neut 24 (H), Band Neut 3.3, Est. Plt Count 20.4 (H); path review pending Radiographs: Loss of peritoneal detail in cranial abdomen; heterogenous soft tissue, opaque granular content in stomach

ULTRASONOGRAPHIC EXAMINATION OF THE ABDOMEN

Urinary System

The urinary bladder is adequately distended with anechoic contents. No masses, inflammatory changes, echogenic sediment or cystoliths are observed. The urinary bladder, trigone and visible pelvic urethra are normal in thickness with a smooth mucosal surface.

The right kidney is normal is size (6.6 cm), shape and echogenicity. It has smooth peripheral margination. There is a normal 1:3 cortex to medulla ratio with appropriate corticomedullary distinction. There is no evidence of pyelectasia, mineral or infarcts observed.

The left kidney is normal is size (6.9 cm), shape and echogenicity. It has smooth peripheral margination. There is a normal 1:3 cortex to medulla ratio with appropriate corticomedullary distinction. There is no evidence of pyelectasia, mineral or infarcts observed.

Adrenal Glands

The right adrenal gland is unable to be well visualized in these images.

The left adrenal gland is normal in size (0.46 cm at cranial pole and 0.59 cm at caudal pole), shape and overall architecture, echogenicity and echotexture. Visible surrounding vasculature appears normal.

Spleen

Spleen is subjectively normal in size with a normal smooth capsular contour. Parenchyma is appropriately finely textured and homogenous with normal echogenicity relative to surrounding tissue (hyperechoic to liver). Multifocal well-demarcated hyperechoic homogenous nodules are noted. Splenic vasculature appears normal.

Liver

The liver is subjectively normal in size with normal smooth curvilinear peripheral contour. Parenchyma is appropriately hypoechoic to the spleen in echogenicity and appropriately mildly coarse and



PATIENT

Lucy Laszlo

SPECIES

Canine

BREED

Coonhound x

SEX

Spayed Female

AGE

9 Years

WEIGHT

33.3 kg

INTERPRETED BY

Beth Johnson, DVM
DACVIM

IMAGING PERFORMED BY

Lindsay Powell, CVT

HOSPITAL NAME

Hershey Animal
Emergency Center

REFERRING VET

Dr. Brittany Lang

INVOICE

75439

DATE

5/27/26

homogenous in echotexture. No focal lesions are observed. Visible vasculature and biliary tree appear normal without distension or congestion.

The gallbladder is non-distended in size. The wall is smooth without visible thickening. Luminal contents are primarily anechoic. There is no evidence of cystic or common bile duct dilation.

Gastrointestinal

The visible stomach wall is normal in thickness and layering. The lumen is mildly distended with primarily fluid as well as some echogenic non-shadowing luminal contents and gas consistent with normal chyme. There is no evidence of obstruction, foreign material, or infiltrative disease. Pyloric outflow tract appears patent.

The visible small intestines are normal in wall thickness and layering. Small intestinal motility appears adequate (1-3 contractions per min). The lumen of the small intestine is empty with no evidence of obstruction, foreign material or infiltrative disease.

The visible colon is normal in wall thickness (< 0.2 cm) and layering. Contents are consistent with normal formed feces and gas.

Pancreas

The observed pancreas is markedly prominent/enlarged in size, hypoechoic to surrounding tissue and irregular in shape with a swollen undulating contour. Enhanced hyperechoic ill-defined surrounding fat is noted. Free fluid is noted in the area.

Free Abdomen

Small prominent hypoechoic lymph nodes/nodules in the area of the markedly prominent pancreas can't be ruled out.

There is a moderate amount of free fluid in these images.

PRIMARY FINDINGS

- Suspect moderate to severe acute pancreatitis. Necrotizing pancreatitis can't be ruled out but warrants color flow/power doppler to assess blood flow.

SECONDARY FINDINGS

- Hyperechoic splenic nodules – most consistent with benign myelolipomas. Other differentials such as fibrosis or calcification caused by old hematomas or infarcts, chronic inflammation, granulomatous disease or metastatic disease cannot be ruled out, but are considered less likely.

INTERPRETATION OF THE FINDINGS & FURTHER RECOMMENDATIONS

A quantitative PLI is recommended if not already evaluated.

Medical management of pancreatitis with anti-emetics, gastroprotectants, appetite stimulants or nutritional support as needed, pain management, broad spectrum antibiotics, and fluid therapy is recommended. If possible, a fresh frozen plasma transfusion and hyperbaric oxygen therapy (HBOT) could be beneficial. Monitoring of the pancreas with power doppler is recommended to identify possible necrosis as well as other potential sequelae such as abscesses, etc.



PATIENT

Lucy Laszlo

SPECIES

Canine

BREED

Coonhound x

SEX

Spayed Female

AGE

9 Years

WEIGHT

33.3 kg

INTERPRETED BY

Beth Johnson, DVM
DACVIM

IMAGING PERFORMED BY

Lindsay Powell, CVT

HOSPITAL NAME

Hershey Animal
Emergency Center

REFERRING VET

Dr. Brittany Lang

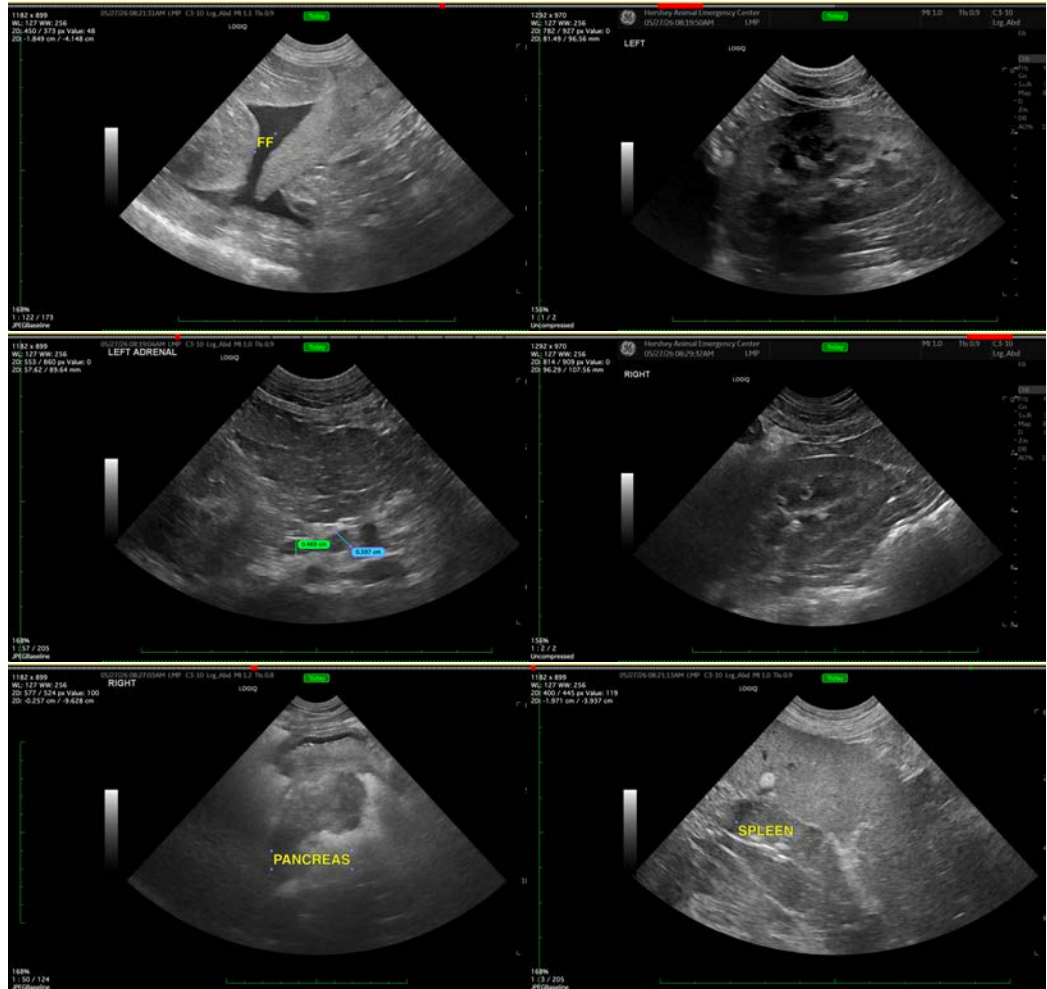
INVOICE

75439

DATE

5/27/26

Patient's reported thrombocytopenia is of unknown, if any relation to the suspected pancreatitis and may warrant further diagnostic and/or therapeutic intervention unrelated or separate from pancreatitis.



The information and recommendations provided are based on the images presented by the referring veterinarian/sonographer. No evaluation can be communicated regarding pathology that was not visible in the image/video clips provided.

Thank you for this referral. If the clinical or image interpretation does not parallel your findings or if I can be of any further assistance please contact me.

Beth Johnson, DVM, DACVIM
info@sonopath.com