



PATIENT

Breezy Laplant

SPECIES

Canine

BREED

Chihuahua

SEX

FS

AGE

11 years 10 months

WEIGHT

10.69 lbs

INTERPRETED BY

Beth Johnson, DVM
 DACVIM

IMAGING PERFORMED BY

Rebecca Hamilton

HOSPITAL NAME

Kingston Animal Hospital

REFERRING VET

Dr. Rosen

INVOICE

12001

DATE

5/27/2026

PRESENTING CLINICAL SIGNS

Weight loss, vomiting, Dec appetite, heart murmur. Vomits water/ fluid w/ small amount of food, usually several times daily. Polydipsia, severe dental dz, cataract OD. Meds: Gabapentin 50mg SID (Hx epilepsy) grade 3/6 HM.

Abnormal PE/Chem/CBC/UA Results: Mild anemia HCT 39% , Azotemia BUN 61, Creat 2.2, mild Inc. Amylase, 4DX Lyme positive historically. Free catch UA USG 1.018, 2+ protein, 3+ blood, mod rods.

ULTRASONOGRAPHIC EXAMINATION OF THE ABDOMEN

Urinary System

Urinary bladder is adequately distended with primarily anechoic contents and occasional echogenic non-shadowing debris. Apical urinary bladder wall is diffusely thick (0.47 cm). Mucosa is hyperechoic and irregular. No masses or cystoliths are observed. The trigone and visible pelvic urethra are normal thickness with a smooth mucosal surface.

The right kidney is normal is size (3.7 cm), shape and echogenicity. It has smooth peripheral margination. There is a normal 1:3 cortex to medulla ratio with appropriate corticomedullary distinction. There is no evidence of pyelectasia, mineral or infarcts observed.

The left kidney is normal is size (3.4 cm), shape and echogenicity. It has smooth peripheral margination. There is a normal 1:3 cortex to medulla ratio with appropriate corticomedullary distinction. There is no evidence of pyelectasia, mineral or infarcts observed.

Adrenal Glands

The right adrenal gland is normal in size (0.84 cm at cranial pole and 0.41 cm at caudal pole), shape and overall architecture, echogenicity and echotexture. Visible surrounding vasculature appears normal.

The left adrenal gland is normal in size (0.34 cm at cranial pole and 0.4 cm at caudal pole), shape and overall architecture, echogenicity and echotexture. Visible surrounding vasculature appears normal.

Spleen

The spleen is subjectively normal in size with a normal smooth capsular contour. Parenchyma is appropriately finely textured and homogenous with normal echogenicity relative to surrounding tissue (hyperechoic to liver). No focal nodules or masses are observed. Splenic vasculature appears normal.

Liver

The liver is subjectively normal in size with normal smooth curvilinear peripheral contour. Parenchyma is appropriately hypoechoic to the spleen in echogenicity and appropriately mildly coarse and homogenous in echotexture. No focal lesions are observed. Visible vasculature and biliary tree appear normal without distension or congestion.

The gallbladder is non-distended in size. The wall is smooth without visible thickening. Luminal contents are primarily anechoic. There is no evidence of cystic or common bile duct dilation.

Gastrointestinal



PATIENT

Breezy Laplant

SPECIES

Canine

BREED

Chihuahua

SEX

FS

AGE

11 years 10 months

WEIGHT

10.69 lbs

INTERPRETED BY

Beth Johnson, DVM
DACVIM

IMAGING PERFORMED BY

Rebecca Hamilton

HOSPITAL NAME

Kingston Animal
Hospital

REFERRING VET

Dr. Rosen

INVOICE

12001

DATE

5/27/2026

The visible stomach wall is normal in thickness and layering. The lumen is moderately distended with primarily fluid as well as some echogenic non-shadowing luminal contents and gas consistent with normal chyme. There is no evidence of obstruction, foreign material, or infiltrative disease. Pyloric outflow tract appears patent.

The visible small intestines are normal in wall thickness and layering. Small intestinal motility appears adequate (1-3 contractions per min). The lumen of the small intestine is empty with no evidence of obstruction, foreign material or infiltrative disease.

The visible colon is normal in wall thickness (< 0.2 cm) and layering. Contents are consistent with normal formed feces and gas.

Pancreas

The pancreas that is observed appears appropriately isoechoic to surrounding omental fat. Visible capsule is smooth and normal in contour. Visible pancreatic parenchyma is homogenous and unremarkable. There is no visible pancreatic duct dilation. There is no evidence of active peripancreatic inflammation.

Free Abdomen

There is no visible free peritoneal effusion noted in these images.

There is no apparent pathologic lymphadenopathy noted in these images.

ULTRASONOGRAPHIC FINDINGS

- Chronic Cystitis - Urinary bladder wall changes are most consistent with chronic cystitis. Infiltrative neoplasia cannot be ruled out but is considered less likely give the location and diffuse nature of the changes.
- The mild to moderate gastric distension is likely related to underlying gastritis/gastroenteritis or other metabolic disease, potentially some ileus, as there is not a definitive ultrasonographically visible reason for delayed outflow/obstruction noted in these images at this time.

INTERPRETATION OF THE FINDINGS & FURTHER RECOMMENDATIONS

Given patient's reported history and lab changes, a urine culture is recommended if not already evaluated.

Assessment for clinically active or significant lyme disease may be indicated. Testing for other infectious disease including leptospirosis could also be considered.

A blood pressure is recommended if not recently evaluated.

A baseline cortisol is recommended. If baseline cortisol is less than 2, a full ACTH stimulation test is recommended to rule out hypoadrenocorticism.

Other than supportive/symptomatic medical management of clinical signs, further diagnostic and treatment recommendations are largely dependent on results of the above.



PATIENT

Breezy Laplant

SPECIES

Canine

BREED

Chihuahua

SEX

FS

AGE

11 years 10 months

WEIGHT

10.69 lbs

INTERPRETED BY

Beth Johnson, DVM
 DACVIM

IMAGING PERFORMED BY

Rebecca Hamilton

HOSPITAL NAME

Kingston Animal
 Hospital

REFERRING VET

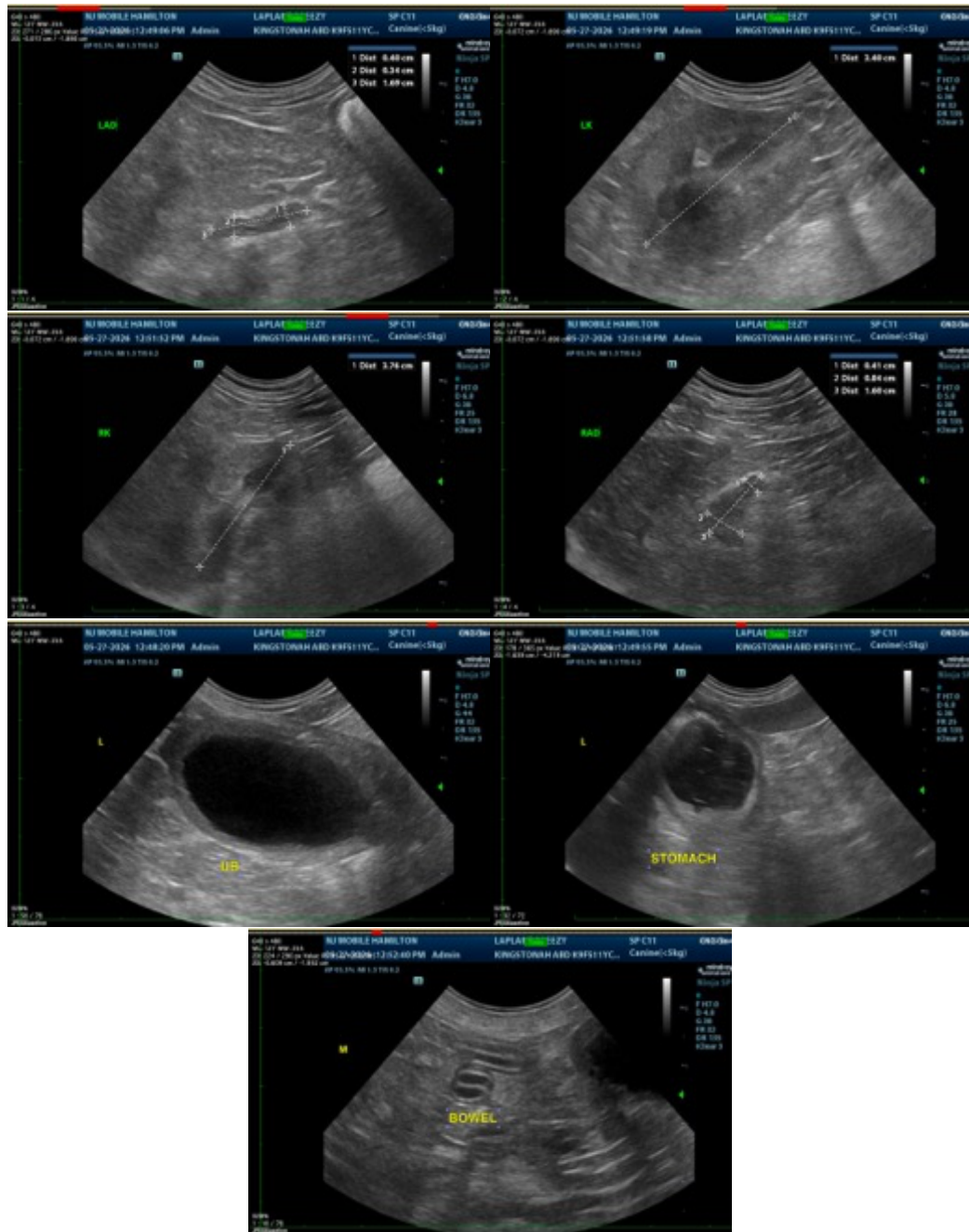
Dr. Rosen

INVOICE

12001

DATE

5/27/2026



The information and recommendations provided are based on the images presented by the referring veterinarian/sonographer. No evaluation can be communicated regarding pathology that was not visible in the image/video clips provided.

Thank you for this referral. If the clinical or image interpretation does not parallel your findings or if I can be of any further assistance please contact me.

Beth Johnson, DVM, DACVIM

info@sonopath.com