



PATIENT

Lola Shema

SPECIES

Canine

BREED

Husky

SEX

Spayed Female

AGE

12 Years 6 Months

WEIGHT

48.8 lbs

INTERPRETED BY

Beth Johnson, DVM
DACVIM

IMAGING PERFORMED BY

Chloe Lowe, CVT

HOSPITAL NAME

Cummings Veterinary
Hospital

REFERRING VET

Dr. Daniels

INVOICE

75436

DATE

5/26/26

PRESENTING CLINICAL SIGNS

Persistent, decreased appetite, diarrhea, weight loss. Unremarkable PE. Severe spinal arthritis. On abdominal radiographs initially increased soft tissue density fat pad ventral to liver.

Abnormal PE/Chem/CBC/UA Results: Alt/alp elevations.

ULTRASONOGRAPHIC EXAMINATION OF THE ABDOMEN

Urinary System

The urinary bladder is adequately distended with anechoic contents. No masses, inflammatory changes, echogenic sediment or cystoliths are observed. The urinary bladder, trigone and visible pelvic urethra are normal in thickness with a smooth mucosal surface.

The right kidney is normal is size (6.47 cm), shape and echogenicity. It has smooth peripheral margination. There is a normal 1:3 cortex to medulla ratio with appropriate corticomedullary distinction. There is no evidence of pyelectasia, mineral or infarcts observed.

The left kidney is normal is size (5.85 cm), shape and echogenicity. It has smooth peripheral margination. There is a normal 1:3 cortex to medulla ratio with appropriate corticomedullary distinction. There is no evidence of pyelectasia, mineral or infarcts observed.

Adrenal Glands

The right adrenal gland is normal in size (1.5 cm at cranial pole and 0.45 cm at caudal pole), shape and overall architecture, echogenicity and echotexture. Visible surrounding vasculature appears normal.

The left adrenal gland is normal in size (0.26 cm at cranial pole and 0.30 cm at caudal pole), shape and overall architecture, echogenicity and echotexture. Visible surrounding vasculature appears normal.

Spleen

The spleen is subjectively normal in size with a normal smooth capsular contour. Parenchyma is appropriately finely textured and homogenous with normal echogenicity relative to surrounding tissue (hyperechoic to liver). No focal nodules or masses are observed. Splenic vasculature appears normal.

Liver

The liver is subjectively normal in size with normal smooth curvilinear peripheral contour. Parenchyma is appropriately hypoechoic to the spleen in echogenicity and appropriately mildly coarse and homogenous in echotexture. No focal lesions are observed. Visible vasculature and biliary tree appear normal without distension or congestion.

Gallbladder is moderately distended with anechoic bile as well as suspended and gravity dependent echogenic debris. The wall is smooth without visible thickening. There is no evidence of cystic or CBD dilation. There is no evidence of effusion or inflammation.

Gastrointestinal

The visible stomach wall is normal in thickness and layering. The lumen of the stomach is mildly distended with very echogenic reverberation artifact from intraluminal gas. There is no evidence of obstruction, foreign material, or infiltrative disease; however, visualization is partially inhibited by gas.



PATIENT

Lola Shema

SPECIES

Canine

BREED

Husky

SEX

Spayed Female

AGE

12 Years 6 Months

WEIGHT

48.8 lbs

INTERPRETED BY

Beth Johnson, DVM
DACVIM

IMAGING PERFORMED BY

Chloe Lowe, CVT

HOSPITAL NAME

Cummings Veterinary
Hospital

REFERRING VET

Dr. Daniels

INVOICE

75436

DATE

5/26/26

The visible small intestine demonstrates areas of mildly thick muscularis layer relative to mucosa (disruption of the normal 1:3 muscularis:mucosa ratio). Small intestinal submucosa is slightly irregular, thick and hyperechoic, without evident loss of layering appreciated. The lumen of the small intestine is empty with no evidence of obstruction or foreign material.

The visible colon is normal in wall thickness (< 0.2 cm) and layering. Contents are consistent with normal formed feces and gas.

Pancreas

*See other.

Other

There is no visible free peritoneal effusion noted in these images.

There is no apparent pathologic lymphadenopathy noted in these images.

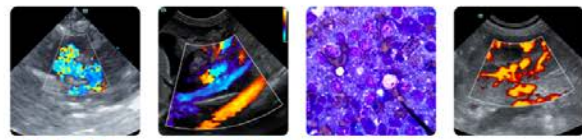
In several images of the right cranial abdomen there is an ill-defined, non-discrete, hypoechoic density/area with some subjectively mildly hyperechoic adjacent tissue that is difficult to fully isolate/assess the identity of, as detail is decreased in the area and there is a lot of artifact. In the clearest view, however, I suspect pancreatic parenchyma.

ULTRASONOGRAPHIC FINDINGS

- Suspect mild, potentially emerging acute pancreatitis, potentially an acute on chronic low-grade smoldering pancreatitis flare up. Having said that, other etiologies including lymph node, focal steatitis from other causes, or even normal patient variant can't be ruled out as it is difficult to fully assess the area as described above.
- Mild inflammatory bowel disease (IBD) pattern – Thick muscularis has been reported with infiltrative bowel disease including both benign inflammatory disease as well as infiltrative neoplasia such as lymphoma. No loss of layering or distinct characteristics of malignancy are present. Therefore, differentials cannot be further ranked without tissue sampling.
- Mild gallbladder debris - Cholecystic debris is of unknown clinical significance. It can be seen with biliary stasis from fasting or illness. Cholecystic debris is not necessarily related to hepatobiliary disease. Echogenic bile is most commonly an incidental finding in dogs and should be interpreted in combination with clinical signs such as nausea, inappetence, cranial abdominal discomfort and/or laboratory changes such as increased ALP and/or increased Tbili.
- An obvious cause for the reported increased liver enzymes is not identified in these images. Microscopic disease such as Leptospirosis, bacterial cholangiohepatitis, chronic active hepatitis, copper-associated hepatotoxicity, other hepatotoxicity, other reactive hepatopathy, infiltrative neoplasia (considered unlikely), etc. cannot be definitively ruled out.

INTERPRETATION OF THE FINDINGS & FURTHER RECOMMENDATIONS

Given patient's reported gastrointestinal signs combined with the changes noted above, a routine fecal/giardia exam is recommended if not recently evaluated.



PATIENT

Lola Shema

SPECIES

Canine

BREED

Husky

SEX

Spayed Female

AGE

12 Years 6 Months

WEIGHT

48.8 lbs

INTERPRETED BY

Beth Johnson, DVM
DACVIM

IMAGING PERFORMED BY

Chloe Lowe, CVT

HOSPITAL NAME

Cummings Veterinary
Hospital

REFERRING VET

Dr. Daniels

INVOICE

75436

DATE

5/26/26

A gastrointestinal malabsorption panel (including cobalamin, folate, TLI and PLI) to Texas A&M GI Laboratory is recommended for further evaluation of GI and pancreatic function.

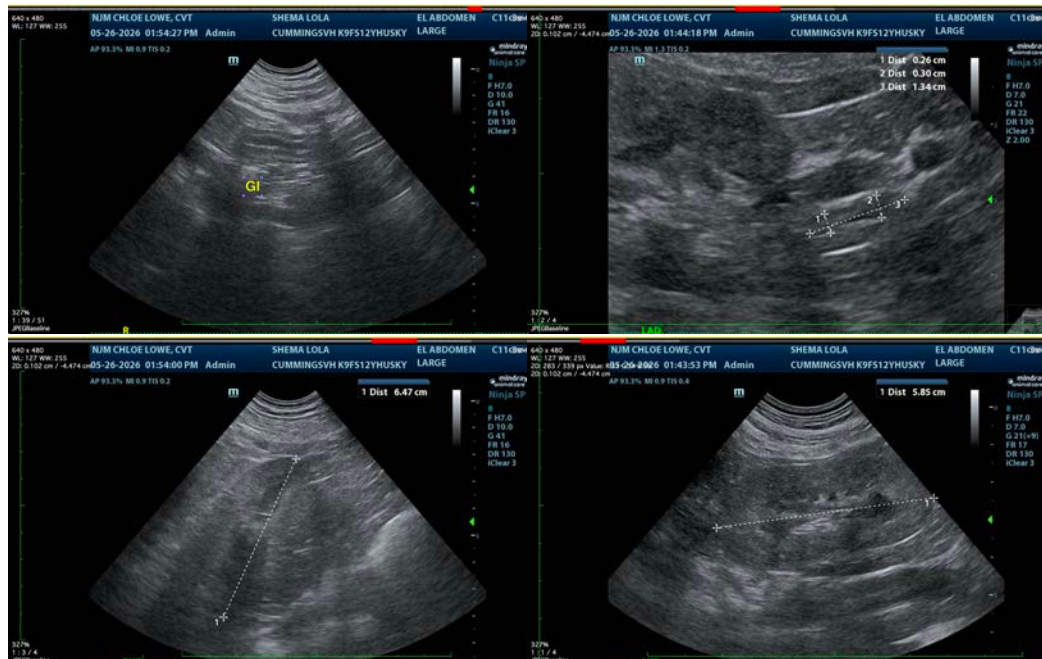
A fecal enteropathogen PCR panel to Texas A&M GI Laboratory could be considered for further evaluation of possible infectious disease. Contact lab for recommendations on how long to discontinue antibiotics (if indicated) prior to obtaining a stool sample for submission.

A baseline cortisol is recommended. If baseline cortisol is less than 2, a full ACTH stimulation test is recommended to rule out hypoadrenocorticism.

Further evaluation of the reportedly increased liver enzymes depend in large part on the exact degree of elevation as well as the pattern i.e., primarily hepatocellular injury versus cholestatic, etc.

Other considerations could include:

- Supportive/symptomatic medical management of clinical signs is recommended, including anti-emetics, gastroprotectants (+/- sucralfate, especially with any history of hematemesis), an appetite stimulant and fluid therapy if indicated, etc.
- Additionally, empirical deworming with a 5-day course of Panacur is recommended.
- A full course of empirical Helicobacter triple therapy could be considered.
- A probiotic, such a visbiome or proviable, may be helpful.
- Finally, if tolerated, a transition in diet could be considered, based on trial-and-error response with some options to consider including a gastrointestinal biome diet vs a hydrolyzed protein diet (sometimes several trials with different brands are necessary) vs an easy to digest, bland or low-fat diet vs other.





PATIENT

Lola Shema

SPECIES

Canine

BREED

Husky

SEX

Spayed Female

AGE

12 Years 6 Months

WEIGHT

48.8 lbs

INTERPRETED BY

Beth Johnson, DVM
 DACVIM

IMAGING PERFORMED BY

Chloe Lowe, CVT

HOSPITAL NAME

Cummings Veterinary
 Hospital

REFERRING VET

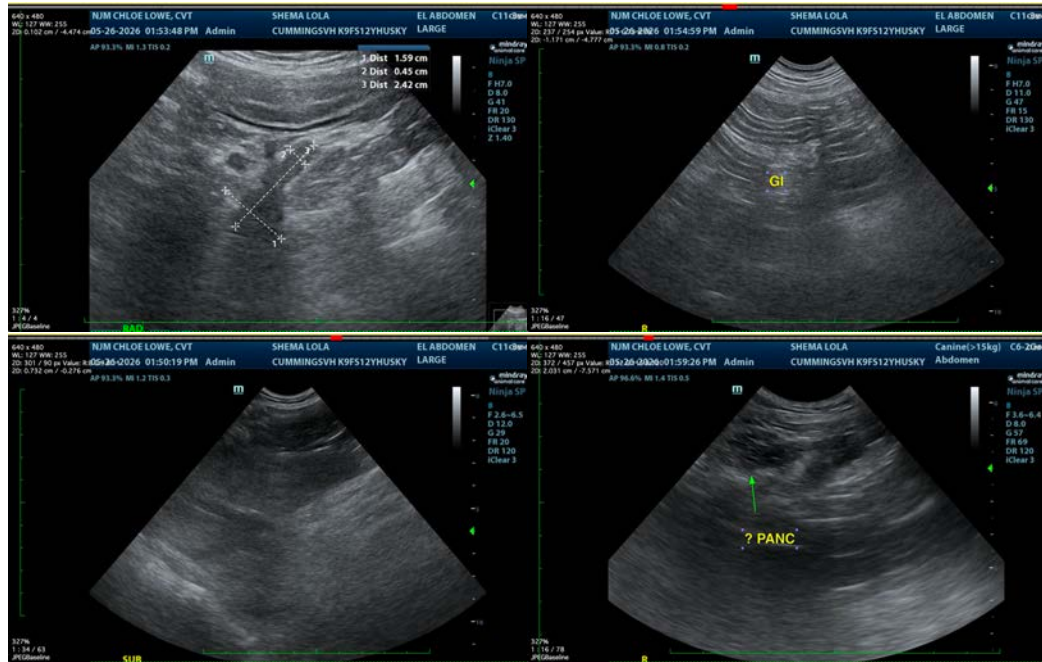
Dr. Daniels

INVOICE

75436

DATE

5/26/26



The information and recommendations provided are based on the images presented by the referring veterinarian/sonographer. No evaluation can be communicated regarding pathology that was not visible in the image/video clips provided.

Thank you for this referral. If the clinical or image interpretation does not parallel your findings or if I can be of any further assistance please contact me.

Beth Johnson, DVM, DACVIM
 info@sonopath.com